

Original article

Dose-dependent effect of local treatment of *Phyllanthus emblica* L. cream on diabetic wound

Ting-ting Liao^a, Supakanda Sukpat^c, Chaisak Chansriniyom^b, Suthiluk Patumraj^{c,*}

^aProgram in Medical Sciences (International Program), Faculty of Medicine, Chulalongkorn University, Bangkok, Thailand

^bDepartment of Pharmacognosy and Pharmaceutical Botany, Faculty of Pharmaceutical Sciences, Chulalongkorn University, Bangkok, Thailand

^cCenter of Excellence for Microcirculation, Department of Physiology, Faculty of Medicine, Chulalongkorn University, Bangkok, Thailand

Background: Non-healing diabetic ulcers are the most common cause of amputation. Several studies have reported for new, more effective treatments for chronic wounds in diabetic patients.

Objective: This study aimed to evaluate the effect of local treatment of *Phyllanthus emblica* Linn. (PE) on a full-thickness wound model in streptozotocin-induced diabetic mice.

Methods: Balb/c mice were divided into five groups: control group (CON), diabetic wounded group (DM, streptozotocin 45 mg/kg i.p. daily for 5 days), diabetic wounded group with daily treatment of different concentrations of PE cream (10%; 100%; and 200%, w/v). Seven days after the diabetic induction, all mice were created bilateral full-thickness excisional skin wounds on the back and received vehicle or PE cream into wound bed. At day 14 post-wounding, the percentage of wound closure (%WC) and the percentage of capillary vascularity (%CV) were determined by using confocal fluorescence microscopy and digital image analysis.

Results: The dose-dependent of PE on diabetic wounds were determined by both findings of %WC and %CV. The results showed positive correlation between various doses of topical PE and 14-day %CV post-wound creation ($r=0.7197$) ($P=0.0017$). The linear regression equation, $Y=0.01788X+37.35$, with $R^2=0.5180$, described the relationship between PE doses and CV%.

Conclusion: These findings show that local administration of PE cream improved the healing process of diabetic wounds in associated with PE's angiogenic effect in a dose-dependent manner.

Keywords: Diabetic wound, *Phyllanthus emblica* Linn., wound closure, capillary vascularity.

The development of severe diabetic complications in multiple organs are common problems that appeared in long-term diabetes or poorly control of hyperglycemia. One of the most common and serious complications of diabetes mellitus is diabetic foot ulcers (DFUs). Around 15.0% of diabetic patients suffer from chronic non-healing diabetic foot ulcers, and approximately 85.0% of persons with diabetes end up with lower-extremity amputations. ⁽¹⁻³⁾

According to the wound healing pathophysiology, it is demonstrated that the resolution of inflammation seems to be the key point for further process of proliferation to develop. In diabetic patients, prolonged inflammatory phase can in turn disturb collagen metabolism, resulting in poor blood supply, reduced production of growth factors, and impaired angiogenesis to contribute to the frequent skin lesions and poor wound healing. ⁽¹⁾ Therefore, several studies have aimed to define some therapeutic agents or medicinal herbs to inhibit or reduce this prolonged inflammatory phase. For instance, simvastatin is one of those researched agents that could reduce pro-inflammatory cytokines, increasing angiogenesis and re-epithelialization, and improve wound closure in both diabetic and non-diabetic animal models. ⁽⁴⁻⁵⁾

*Correspondence to: Suthiluk Patumraj, Department of Physiology, Faculty of Medicine, Chulalongkorn University, Bangkok 10330, Thailand.

E-mail: suthilukp@yahoo.com

Received: November 17, 2020

Revised: February 2, 2021

Accepted: March 4, 2021

Phyllanthus emblica Linn. (PE), belongs to the euphorbiaceae family, is widely distributed throughout tropical and subtropical countries.⁽⁶⁻⁷⁾ It is native to tropical south eastern Asia in mixed forest regions. PE is one of the important and most widely used herbal drugs in Ayurvedic Medicine.⁽⁸⁾ PE has shown strong antioxidant effect with experimental evidence. In addition, previous studies indicated that PE has antidiabetic and beneficial effects on lipid profile; thus, it can be recommended for use as a natural supplementary herbal remedy in patients suffering from diabetes mellitus.⁽⁹⁾ However, no research has yet been reported about the PE effects on wound angiogenesis and wound closure in diabetic wound model. Therefore, the present study aimed to define whether the topical application of PE-cream could improve wound healing in diabetic mice association with angiogenic effect in a dose-dependent manner or not.

Materials and methods

PE extraction

Phyllanthus emblica Linn. fruits were taken from Kanchanaburi, Thailand. Then 10 kg of the fresh *Phyllanthus emblica* Linn. fruits were squeezed to get fruit without juice. After that, the squeezed *Phyllanthus emblica* Linn. fruits were extracted with 100% ethanol (1:2 w:v) for 72 hours, three times. The alcoholic extraction solution was evaporated by vacuum rotary evaporation below 45°C to yield PE-ethanol extract production.

Animals

Male BALB/c mice (7 - 8 weeks, 20 - 25 g) from Nomura Siam International, Bangkok, Thailand were used in this study. All procedures were conducted in accordance with guidelines for the use of experimental animals by The National Research Council of Thailand. This study has been approved by the Ethics Committee, Faculty of Medicine, Chulalongkorn University, Bangkok, Thailand (IRB no. 007/2562).

The mice were divided into five groups as follows: the control group (CON; n = 4); the diabetic group (DM; n = 4); the latter received a daily treatment of PE at the doses of 10%, 100%, and 200%, w/v (DM + PE10, DM + PE100, DM + PE200; n = 12). STZ was intraperitoneally injected to BALB/c mice, dosage of 45mg/kg, for 5 consecutive days, to induce diabetic mice model. Seven days after the blood glucose reached 200 mg/dL, the full-thickness bilateral wound model (0.6 × 0.6 cm²) was made on the dorsal

skin of each mice. In the experimental protocol, the various doses of 10%, 100%, and 200% for PE, were used and mixed in PMA2-base cream. The prepared PE extract as mentioned above was weighted according to the calculation of 10% PE, 100% PE and 200% PE weight per volume of the cream mixture. The prepared 10% PE, 100% PE and 200% PE creams were kept in tightly closed light-proof brown glass bottles and kept at 4°C. At room temperature, the 10 µl of mixture cream was topically applied to the wound area of each mouse once a day for 14 days.

Diabetic induction and wounding protocols

In the diabetic groups, mice were induced by injection of streptozotocin (Sigma Chemical Co, USA.) in citrate buffer pH 4.5 (Sigma Chemical Co, USA.) with dose of 45 mg/kg intraperitoneal injection daily for 5 days. The same volume of citrate buffer was injected by the same route to non-diabetic control animal. Two weeks after diabetic induction, tail-vein blood glucose levels were measured by using glucometer (Advance Glucometer, Boehringer Mannheim, Germany). The inclusion criteria for diabetes was that the fasting plasma glucose concentration equals to or greater than 200 mg/dL.⁽¹⁰⁾

The wounding protocol was modified from Wu Y, *et al.* and Sivan-Loukianova E, *et al.*⁽¹¹⁻¹²⁾ Seven days after the diabetic induction, the mice were anesthetized (sodium pentobarbital 55 mg/kg, i.p.) and swabbed with alcohol on dorsal-rostral back. Bilateral full-thickness excisional skin wounds (0.6 x 0.6 cm²) were created on both left and right sides of the midline. A square-shaped plastic splints were secured around the perimeter of the wound to limit wound contracture.

Wound closure (WC) measurement

This study was observed at day 14 after wound creation. Briefly, the mice were anesthetized with an intraperitoneal injection of sodium pentobarbital at a dose of 55 mg/kg. Digital photographs of the wounds were taken at day 14 by a digital camera (Nikon DSLR2, Japan) (Canon EOS, Japan). Areas of the wounds were measured by tracing the wound margin and calculated using digital image software analysis (Image-Pro Plus II 6.1, Media Cybernetics, Bethesda, MD), and the percentage of wound closure (%WC) was evaluated using the following equation: - %WC = (area of original wound- area of actual wound)/area of original wound x 100.^(10,12)

Capillary vascularity (CV) measurement

The right jugular vein of anesthetizing mouse was cannulated for injection of 0.1 ml of 5% FITC-labeled dextran. The capillary vascularity was examined using confocal fluorescence microscopy at 100 x magnification (Nikon eclipse E800, Nikon, Japan). From the fluorescent photographs, the capillary diameter less than 15 μm were analyzed using Image Pro II 6.1 software. The percentage of capillary vascularity (%CV) was calculated using the following equation:- %CV = number of pixels within capillaries/ total number of pixels of the entire frame x 100.^(10,13)

Statistical analysis

The data were expressed as the means ± standard errors of mean (SEM) and standard deviation (SD). The differences between groups were determined by one-way analysis of variance (ANOVA), followed by the least significant difference (LSD) post hoc test using SPSS software, version 22. The comparison between groups was done by using Student's *t* - test. Differences were statistically significant when *P* - value was less than 0.05.

Results

In Figure 1, 14 days after wound creation, tail-vein blood glucose levels were measured by using

glucometer (Advance Glucometer, Boehringer Mannheim, Germany). Results of fasting plasma glucose concentration (FBG, mg/dl) indicated the hyperglycemia in DM had no effects from the topical treatments of PE.

Data showed that under hyperglycemia, the percentage of capillary vascularity (%CV) were significantly decreased at the 14-day DM as shown in Figure 2 (CON = 40.7 ± 1.2%, DM = 36.3 ± 0.7%, DM + PE10 = 38.5 ± 0.8%, DM+PE100 = 39.4 ± 0.7%, DM + PE200 = 40.8 ± 0.5%) (*P* < 0.05). In addition, at 14-day post-wound, the percentage of wound closure (%WC) was significantly less in the DM group than in the control group, as shown in Figure 3 (CON = 99.3 ± 0.1%, DM = 94.8 ± 2.8%, DM+PE10 = 98.8 ± 0.5%, DM+PE100 = 99.0 ± 0.6%, DM+PE200 = 97.3 ± 0.8%) (*P* < 0.05).

In Figure 4, the dose-dependent of PE on diabetic wounds was demonstrated. The results showed positive correlation between various doses of topical PE and %CV on day 14 post-wound (*r* = 0.7197), (*P* = 0.0017). The linear regression equation, $Y = 0.01788X + 37.35$ with $R^2 = 0.5180$, represents the relationship between PE doses and CV%.

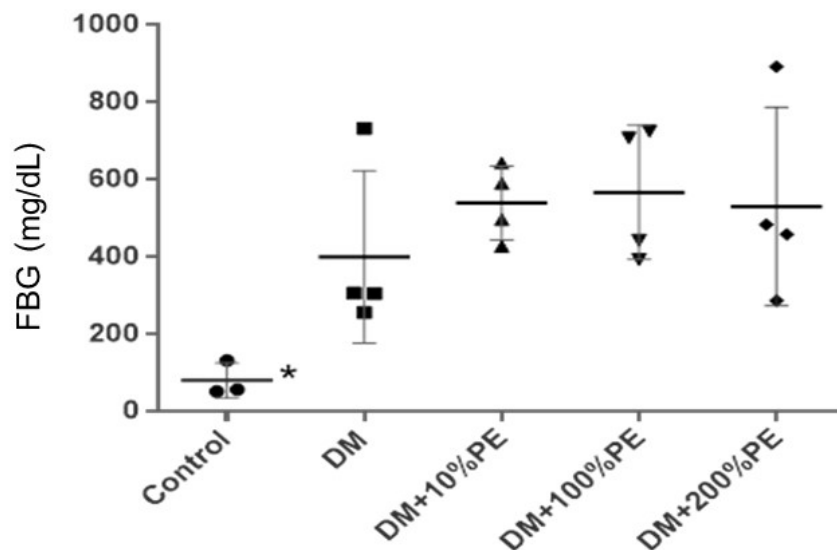


Figure 1. At 14 days after wound creation, tail-vein blood glucose levels were measured by using glucometer (Advance Glucometer, Boehringer Mannheim, Germany). The fasting plasma glucose concentration (FBG, mg/dl) in the control group (CON; n = 4); the diabetic group (DM; n = 4); the diabetic group received a daily treatment of PE at doses of 10%; 100%; and 200%, w/v (DM+PE10, DM+PE100, DM+PE200; n = 12) were shown.

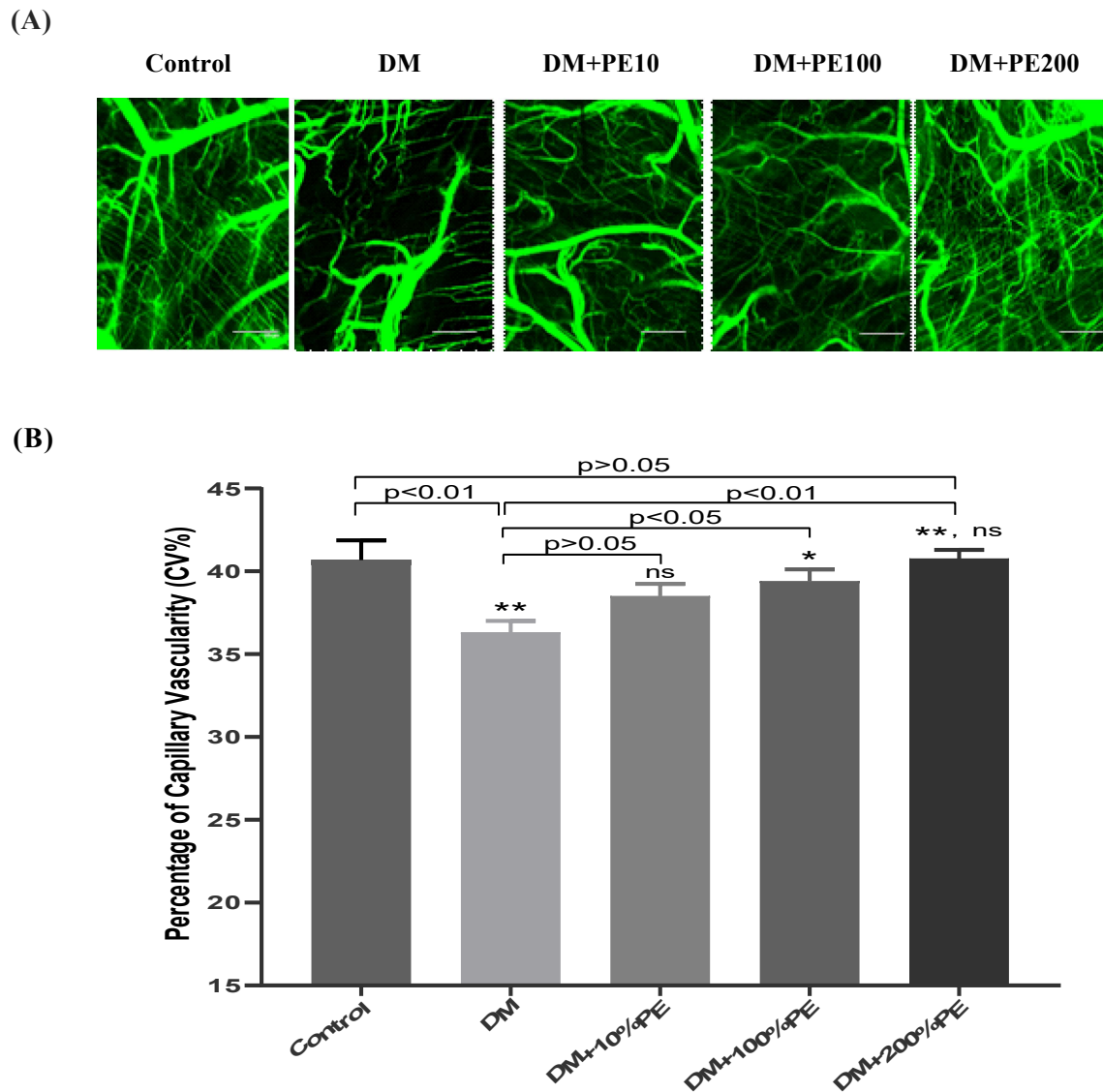


Figure 2. A-B. The capillary vasculature was examined using confocal fluorescence microscopy at 100x magnification (Nikon eclipse E800, Nikon, Japan).

(B). From the fluorescent photographs, the capillary diameter less than 15 μm were analyzed using Image Pro II 6.1 software. At 14 days after wound creation, means percentage of capillary vasculature of CON, DM, DM+PE10, DM+PE100, DM+PE200 were calculated using the following equation: (number of pixels within capillaries/total number of pixels of the entire frame) x 100. Bar scale is 100 μm . * $P < 0.05$, ** $P < 0.01$, ns is non-significant difference.

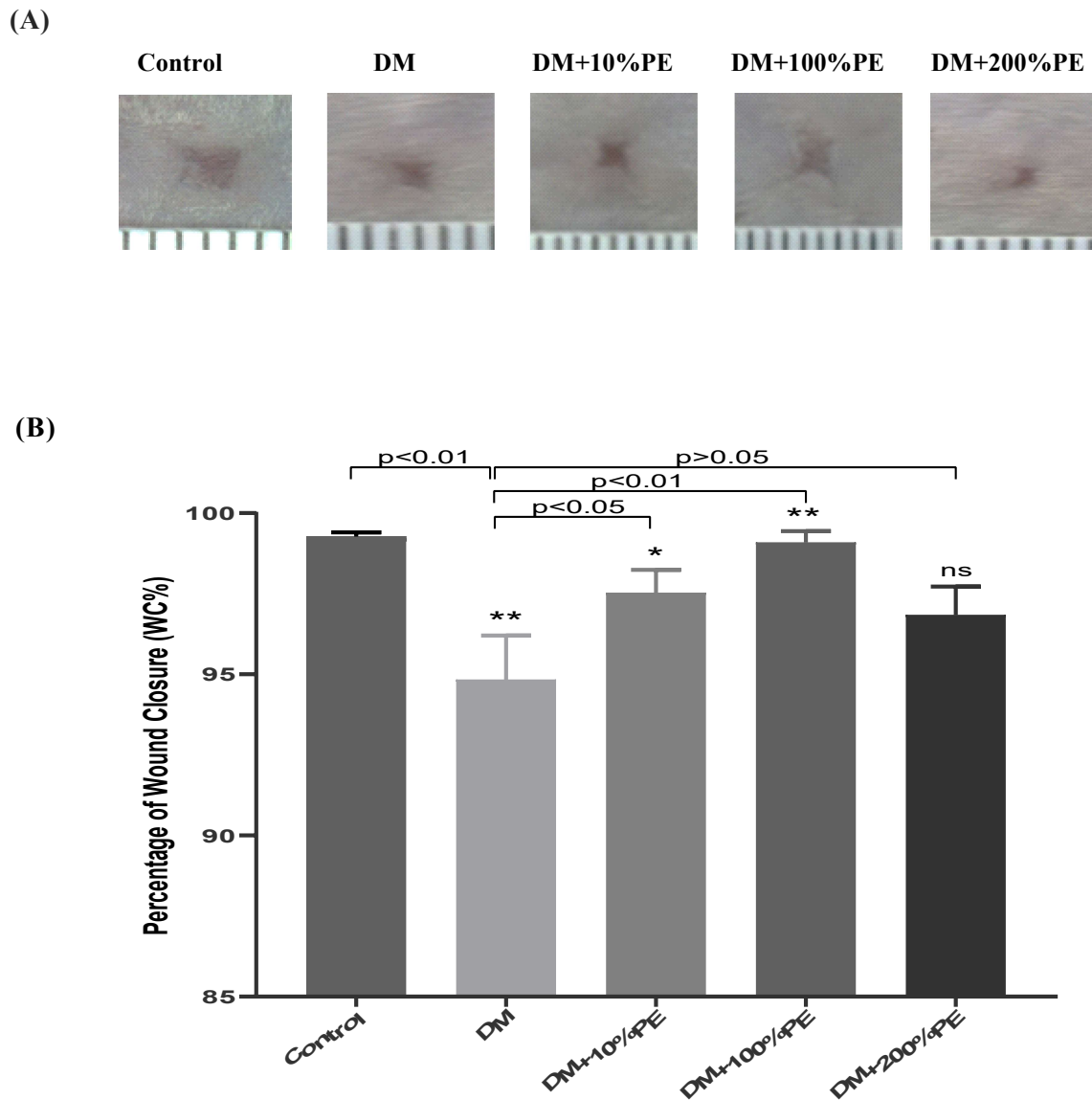


Figure 3. (A-B) At 14-day post-wound creation, the percentage of wound closure (%WC) for CON, DM, DM+PE10, DM+PE100, DM+PE200 were determined from photographs taken by a digital camera (Nikon DS-L2, Japan). Areas of the wound were measured by tracing the wound margin and calculated using digital image software analysis (Image-Pro Plus II 6.1; Media Cybernetics, Bethesda, MD), and the percentage of wound closure (%WC) was evaluated using the following equation: (area of original wound- area of actual wound)/area of original wound x 100. * $P < 0.05$, ** $P < 0.01$, ns is non-significant difference.

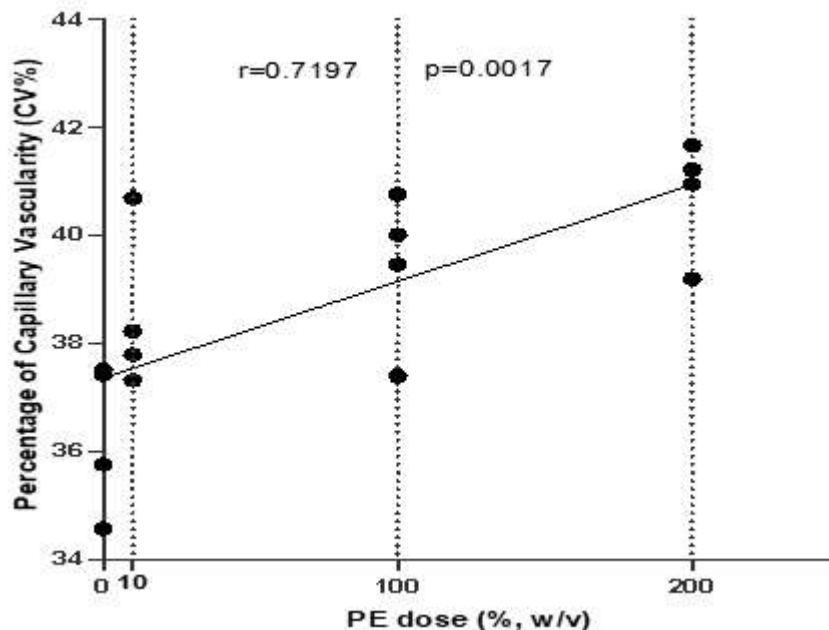


Figure 4. The dose response of PE on diabetic wound was demonstrated. The results showed positive Pearson's correlation coefficient, $r = 0.7197$ ($P = 0.0017$), among PE doses and CV% of day-14 post-wound. The linear regression equation, $Y = 0.01788X + 37.35$ with $R^2 = 0.5180$, represents the relationship between PE doses and CV%.

Discussion

Diabetic wounds are characterized by prolonged chronic inflammatory state, impaired cellular defense mechanisms, and induced prolonged elevation of pro-inflammatory mediators including TNF- α , IL-1, and IL-6. This pro-inflammatory environment induces a low-grade inflammation, leading to a chronic inflammatory state.⁽¹⁴⁻¹⁵⁾ Moreover, the reduction of growth factors, angiogenesis, and abnormal blood flow cause prolonged and incomplete diabetic wound healing.⁽¹⁶⁾

In this study, we found that at high doses of topical PE cream, 100% and 200%, could improve wound vascularity in diabetic mice. The wound closure (%WC) and capillary vascularity (%CV) were significantly different between DM and DM+PE100 at 14 days after wound creation.

Considering the previous findings, by using the excision and incision wound models, Boakye YD, *et al.* found that wounds treated with *Phyllanthus muellerianus* (PE, 0.25, 0.5, and 1% w/w) cream could increase wound contraction rate when compared to untreated wounds.⁽¹⁶⁾ Immunohistochemical investigations revealed high levels of TGF- β 1 in PE-treated wound tissues when compared to the untreated wound tissues. Tensile strength of incised wounds was significantly high in

PE-treated wounds. It was remarked that PE possess wound healing and cytoprotective effects.⁽¹⁶⁾

In the present study, the topical application of PE (100% w/v) on diabetic wound model showed significant ($P < 0.01$) reduction in wound area when compared to the diabetic untreated group (Figure 3). The pronounced reduction in wound area exhibited by PE (100% w/v) might be explained by the effect of PE on enhancing wound capillary vascularity. The results shown in Figure 2 indicated the increased %CV in PE-treated groups. Moreover, by using Pearson's correlation analysis (Figure 4), the finding confirmed a positive correlation between the expected factors and represented the pleiotropic effect of PE on wound angiogenesis.

Previous studies have documented PE to contain biologically important compounds such as tannins, alkaloids, phenolic compounds, and flavonoids.⁽¹⁷⁻¹⁸⁾ The polyphenols and hydrolysable tannins, which have ascorbic acid-like action from *Phyllanthus emblica* Linn. were reported to have stronger superoxide anion radical scavenging ability than vitamin C.⁽¹⁹⁻²⁰⁾ Besides, in various study models, *Phyllanthus emblica* Linn. has been proved to increase the antioxidant defense system enzymes and lipid peroxidation marker, such as standard malondialdehyde, glutathione peroxidase, superoxide dismutase, catalase and glutathione.⁽²¹⁻²³⁾

Therefore, it might be proposed that the antioxidant effect of *Phyllanthus emblica* Linn. is the key mechanism of improving diabetic wound angiogenesis and wound healing.

Conclusion

These results may be the first in vivo evidence showed the topical treatment of PE's effects on wound angiogenesis and wound closure in diabetic-wounded mice model by dose effective manner. PE cream might be used to improve the clinical benefit. However, it still needs further clinical research to determine the proper dose of PE cream for diabetic patients.

Acknowledgements

This study was supported by Ratchadapisek-sompotch Fund of the Faculty of Medicine, The 100th Anniversary Chulalongkorn University for Doctoral Scholarship, the Graduate School, Chulalongkorn University, Thailand.

Conflict of interest

The authors, hereby, declare no conflict of interest.

References

1. Ogurtsova K, da Rocha Fernandes JD, Huang Y, Linnenkamp U, Guariguata L, Cho NH, et al. IDF diabetes atlas: global estimates for the prevalence of diabetes for 2015 and 2040. *Diabetes Res Clin Pract* 2017;128:40-50.
2. Schreiber J, Efron PA, Park JE, Moldawer LL, Barbul A. Adenoviral gene transfer of an NF-kappaB super-repressor increases collagen deposition in rodent cutaneous wound healing. *Surgery* 2005;138:940-6.
3. Pecoraro RE, Reiber GE, Burgess EM. Pathways to diabetic limb amputation. Basis for prevention. *Diabetes Care* 1990;13:513-21.
4. Sukpat S, Israsena N, Patumraj S. Pleiotropic effects of simvastatin on wound healing in diabetic mice. *J Med Assoc Thai* 2016;99:213-9.
5. Asai J, Takenaka H, Hirakawa S, Sakabe J, Hagura A, Kishimoto S, et al. Topical simvastatin accelerates wound healing in diabetes by enhancing angiogenesis and lymphangiogenesis. *Am J Pathol* 2012;181: 2217-24.
6. Unander DW, Webster GL, Blumberg BS. Usage and bioassays in *Phyllanthus* (Euphorbiaceae). IV. Clustering of antiviral uses and other effects. *J Ethnopharmacol* 1995;45:1-18.
7. Unander DW, Webster GL, Blumberg BS. Records of usage or assays in *Phyllanthus* (Euphorbiaceae). I. Subgenera *Isocladius*, *Kirganelia*, *Cicca* and *Emblica*. *J Ethnopharmacol* 1990;30:233-64.
8. Kirtikar KR, Basu BD. In: Kirtikar KR, Basu BD, editors. *Indian medicinal plants*, 2nd ed. Allahabad: Lolit Mohan Basu Publication;1935. p.1020-23.
9. Krishnaveni M, Mirunalini S, Karthishwaran K, Dhamodharan G. Antidiabetic and antihyperlipidemic properties of *Phyllanthus emblica* Linn. (Euphorbiaceae) on streptozotocin induced diabetic rats. *Pak J Nutr* 2010;9:43-51.
10. Sukpat S, Isarasena N, Wongphoom J, Patumraj S. Vasculoprotective effects of combined endothelial progenitor cells and mesenchymal stem cells in diabetic wound care: their potential role in decreasing wound-oxidative stress. *Biomed Res Int* 2013;459196.
11. Wu Y, Chen L, Scott PG, Tredget EE. Mesenchymal stem cells enhance wound healing through differentiation and angiogenesis. *Stem Cells* 2007;25: 2648-59.
12. Sivan-Loukianova E, Awad OA, Stepanovic V, Bickenbach J, Schatteman GC. CD34+ blood cells accelerate vascularization and healing of diabetic mouse skin wounds. *J Vasc Res* 2003;40:368-77.
13. Chokesuwattanaskul S, Sukpat S, Duangpatra J, Buppajarntham S, Decharatanachart P, Mutirangura A, Patumraj S. High dose oral vitamin C and mesenchymal stem cells aid wound healing in a diabetic mouse model. *J Wound Care* 2018;27:334-9.
14. Saraheimo M, Teppo AM, Forsblom C, Fagerudd J, Groop PH. Diabetic nephropathy is associated with low-grade inflammation in Type 1 diabetic patients. *Diabetologia* 2003;46:1402-7.
15. Garcia C, Fève B, Ferre P, Halimi S, Baizri H, Bordier L, et al. Diabetes and inflammation: fundamental aspects and clinical implications. *Diabetes Metab* 2010;36: 327-38.
16. Boakye YD, Agyare C, Ayande GP, Titiloye N, Asiamah EA, Danquah KO. Assessment of wound-healing properties of medicinal plants: The case of *Phyllanthus muellerianus*. *Front Pharmacol* 2018; 9:945.
17. Suguna L, Singh S, Sivakumar P, Sampath P, Chandrakasan G. Influence of *Terminalia chebula* on dermal wound healing in rats. *Phytother Res* 2002; 16:227-31.
18. Tang T, Yin L, Yang J, Shan G. Emodin, an anthraquinone derivative from *Rheum officinale* Baill, enhances cutaneous wound healing in rats. *Eur J Pharmacol* 2007;567: 177-85.

19. Singh E, Sharma S, Pareek A, Dwivedi J, Yadav S, Sharma S. Phytochemistry, traditional uses and cancer chemopreventive activity of Amla (*Phyllanthus emblica*): The Sustainer. *J Appl Pharm Sci* 2011;2: 176-83.
20. Yadav SS, Singh MK, Singh PK, Kumar V. Traditional knowledge to clinical trials: a review on therapeutic actions of *Emblica officinalis*. *Biomed Pharmacother* 2017;93:1292-302.
21. Usharani P, Fatima N, Muralidhar N. Effects of *Phyllanthus emblica* extract on endothelial dysfunction and biomarkers of oxidative stress in patients with type 2 diabetes mellitus: a randomized, double-blind, controlled study. *Diabetes Metab Syndr Obes* 2013; 6:275-84.
22. Chansrinoyom C, Bunwatcharaphansakun P, Eaknai W, Nalinratana N, Ratanawong A, Khongkow M, et al. A synergistic combination of *Phyllanthus emblica* and *Alpinia galanga* against H₂O₂-induced oxidative stress and lipid peroxidation in human ECV304 cells. *J Funct Foods* 2018;43:44-54.
23. Usharani P, Kishan PV, Fatima N, Kumar CU. A comparative study to evaluate the effect of highly standardised aqueous extracts of *Phyllanthus emblica*, *Withania somnifera* and their combination on endothelial dysfunction and biomarkers in patients with type 2 diabetes mellitus. *Int J Pharm Sci Res* 2014; 5:2687-97.