

## Ultrasonography of amoebic liver abscess

Kaesorn Vajarapongse\*

Darunee Wetchsetnont\*

Vacharee Buachum\*

Laddawan Vajaragupta\*

Sukalaya Lerdlum\*

เกษร วัชรพงศ์, ครุณี เวชเชษฐนนท์, ลัดดาวัลย์ วัชรกุลป์, วัชร บัวชุม, สุกัลยา เลิศล้ำ. อุลตราซาวด์ของฝีในตับ. จุฬาลงกรณ์เวชสาร 2527 กันยายน; 28 (9) : 973-982

การศึกษาลักษณะภาพอุลตราซาวด์ของฝีในตับที่เกิดจากเชื้ออมีบา ในผู้ป่วย 52 ราย ซึ่งมีจำนวนฝีทั้งหมด 60 แห่ง ในโรงพยาบาลจุฬาลงกรณ์ ระหว่างปี ค.ศ. 1980-1983 ได้ทำการวิเคราะห์ลักษณะภาพอุลตราซาวด์ของฝีในตับในแง่ของ จำนวน ขนาด รูปร่าง ตำแหน่ง ลักษณะการสะท้อนของคลื่นเสียง (*echogenic pattern*) และความเข้มของเสียงที่ผ่านขอบหลังของฝี (*through transmission*)

จากการศึกษาพบว่า ฝีในตับที่เกิดจากเชื้ออมีบามีจำนวนหนึ่งแห่ง มี 46 ราย และมากกว่าหนึ่งแห่ง มี 6 ราย ฝีส่วนใหญ่มีรูปร่างกลมหรือรูปไข่ อยู่ในกلبขวา ของตับ และชิดกับผิว คลื่นเสียงสะท้อนภายในฝี (*internal echo*) มีน้อยหรือไม่มี 50% การสะท้อนของคลื่นเสียงที่ขอบฝีมีน้อย (*echogenic wall*) 73% และมีการเพิ่มขึ้นของความเข้มของเสียงหลังจากผ่าฝีไปแล้ว (*through transmission*) 70%

ลักษณะดังกล่าวอาจจะเป็นแนวทางในการวินิจฉัยแยกโรกระหว่างฝีในตับที่เกิดจากเชื้ออมีบาและฝีในตับที่เกิดจากเชื้อชนิดอื่น

Gray scale ultrasonogram is now used to evaluate the focal lesion in the liver. The ultrasonographic features of the typical abscess had been described.<sup>(1-6)</sup> We have analysed the ultrasonographic features of the amoebic abscesses in attempt to clarify some specific ultrasonographic appearances.

### Material and methods

The ultrasonography of 52 patients (60 abscesses) with proved amoebic liver abscesses at Chulalongkorn Hospital during 1980-1983 were retrospectively analysed. The abscesses were proved either by aspiration, serologic test, clinical response to metronidazole or surgery. Some abscesses were needle aspirated under ultrasound guidance. The ultrasonography was performed with PHOSONIC 8 m. ACPHL using 2.25 or 3.5 MHz transducer. The age incidence was between 20-50 years, with 43 males and 9 females. Abdominal pain, fever with chill were the commonest presenting symptoms. The ultrasonographic appearances of the abscesses were analysed with regard to size, shape, location, echogenic patterns, and through transmission. The ultrasonic appearance of the liver is an homogeneous internal architecture with fine uniform distribution of echoes without focal disruption. The degree of echogenicity of the lesion in

the liver was compared to the echogenicity of the normal liver parenchyma. The high level echoic or hyperechoic lesion had higher amplitude and numbers of echoes than normal liver. The isoechoic lesion showed equal number and intensity of echoes to the normal liver parenchyma. The low level echoic or hypoechoic lesion had less number and intensity of echoes than normal liver. The anechoic lesion was an area of absence echoes. However the anechoic lesion may contain variable amounts and intensity of the internal echoes. When the sound beam passes through the fluid-filled structures, there will be an increase in the intensity of the echoes behind the posterior wall of the structure which is called through transmission or sound enhancement. The margin of the abscesses had different echogenicity and was referred to the thickness of the wall of abscess in this presentation.

### Results

Forty six patients had one abscess, 4 had 2 abscesses, and 2 had 3 abscesses. The size varied from 3 to 12 cm. in diameter. Fifty five abscesses were located in the right lobe, 5 in the left lobe. Forty two abscesses in the right lobe were contiguous to the liver capsule. Most of the abscesses were round or ovoid shape. The echogenic patterns were shown in table I.

Table 1

Ultrasonographic feature		No.
I. Echogenic character in the abscess.		60 abscesses
1. Well defined poor echoic area. (Fig. 1)		16 (26.7%)
2. Anechoic area contained		
A. Fine. homogeneous low level echoes (Fig. 2)		14 (23.3%)
B. Mixed irregular different level echoes (Fig. 3)		6 (10%)
C. Homogeneous low level echoes with anechoic center (Fig. 4)		1 (1.7%)
D. Some low level echoes at the lower portion (Fig. 5)		10 (16.7%)
E. Fluid-debries level (Fig. 6)		3 (5%)
3. Low or isoechoic area with peripheral echo free halo (Fig. 7)		10 (16.7%)
II. Distal sonic enhancement.		
presence		42 (70%)
absence		18 (30%)
III. Echogenic wall		
No		44 (73.3%)
Thin (Fig. 8)		10 (16.7%)
Thick (Fig. 9)		6 (10%)

Ten patients with amoebic abscesses had follow up scans from 3 to 90 days. The sonographic changes were studied. The early abscess showed iso-echoic area distinguished from the normal liver by peripheral echo free halo. All the abscesses in the follow up scans were decrease in size and internal echoes. Fig. 10, 11

### Discussion

The specific ultrasonic features of the amoebic abscess can not be definitely established. There are wide variation of the echogenicity of the abscess from totally anechoic to echoic lesion. Nevertheless most of the amoebic abscesses showed well defined low level-echoes, round or ovoid shape, peripheral loca-

tion, distal sonic enhancement without echogenic wall. The ultrasonographic appearances are related to the phases of development, organization and repair of abscess.<sup>(12-15)</sup> In our cases, the early abscesses tended to be iso-echoic and turned to be hypo or anechoic in the follow up sonograms. Corresponding to the pathology and pathogenesis of the amoebic abscess, the early phase is characterized by granuloma or micro abscesses, the cavity is formed later by coalescence of a number of smaller abscesses.<sup>(12-15)</sup> The contents of the abscess give different echogenicity. In the experimental studies showed that the sonographic appearance of the fluid

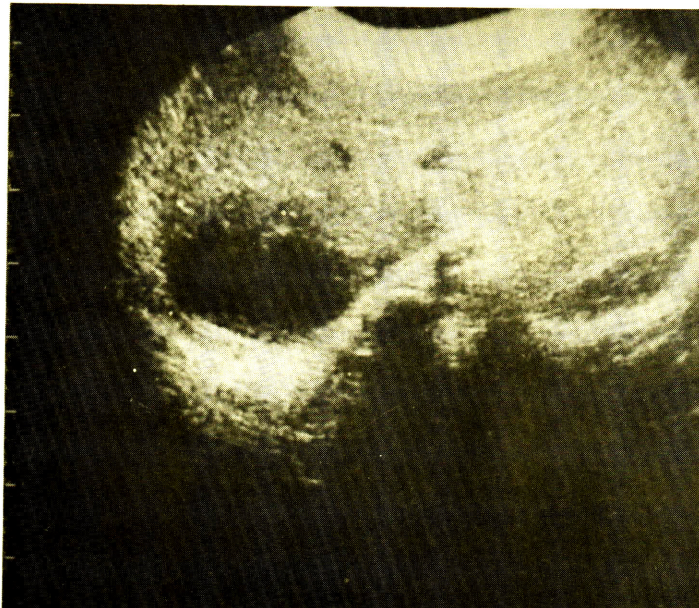
collection containing cholesterol, protein, lipid, fat, and suspension of protein macroaggregates were echogenic.<sup>(7-11)</sup> Some early abscesses showed isoechoic lesion with peripheral echo free halo. The peripheral echo free halo may represent the inflammatory reaction and the increased blood flow in the adjacent parenchyma.<sup>(2,6)</sup> Few abscesses had echogenic wall. The well formed fibrous wall is indicating chronicity as well as secondary infection.<sup>(12)</sup> The echogenic wall is not the common ultrasonic finding of amoebic abscess.

#### Conclusion

This presentation showed the common ultrasonographic features of the amoebic abscess that may help to establish

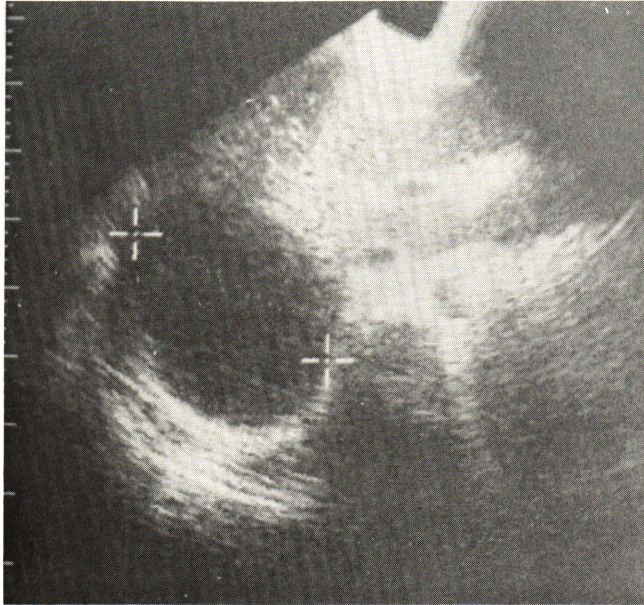
the diagnosis. The ultrasonography guided needle aspiration is a useful method to quickly and definitely diagnose the abscess. If diagnosed early, amoebic abscess can be treated effectively at low cost. If undiagnosed, significant morbidity and mortality may occur.

The ultrasonographic appearance of amoebic liver abscess was studied in 52 patients (60 abscesses). The size, shape, location, echogenic patterns, and through transmission were analysed. The frequent ultrasonographic features of amoebic abscess were single, round or ovoid shape, peripheral location, poor echoic or homogenous low echoic lesion (50%), no echogenic wall (73.3%) with distal sonic enhancement (70%).

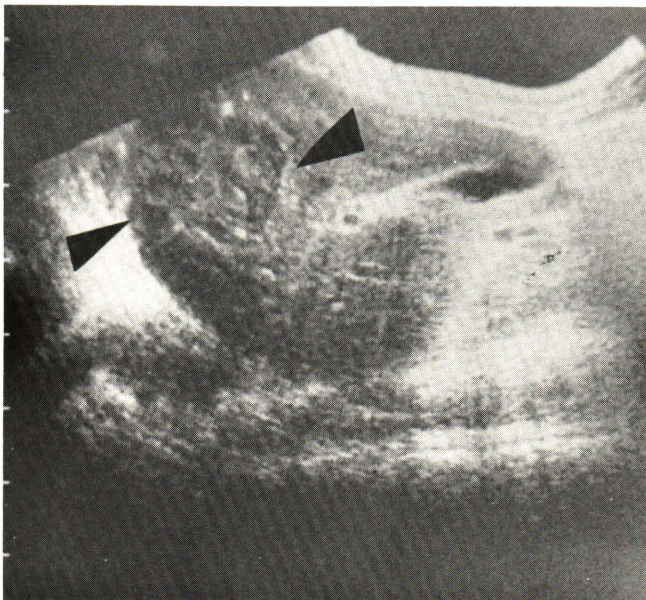


**Fig. 1** Transverse scan shows a well defined poor echoic area in the right lobe with distal sonic enhancement. There is no echogenic wall.



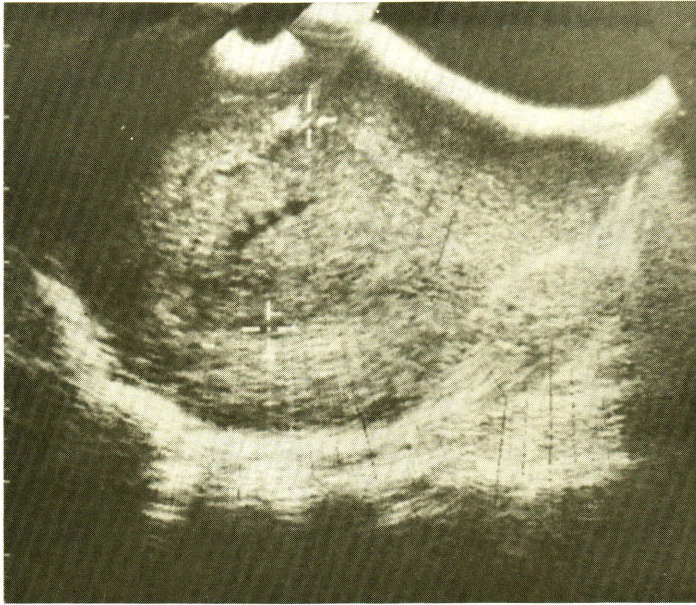


**Fig. 2** Transverse scan shows a well defined anechoic area containing homogeneous low level echoes with distal sonic enhancement.

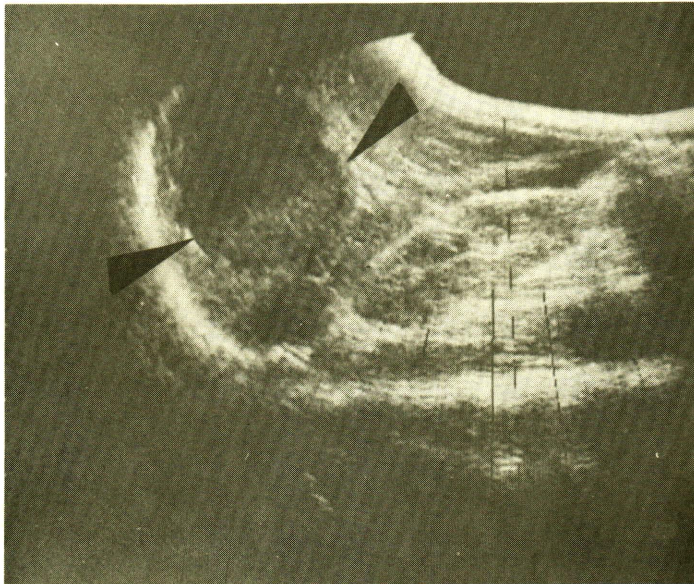


**Fig. 3** Sagittal scan through the right lobe shows a round anechoic area containing mixed irregular different level echoes. There is no definite distal sonic enhancement.



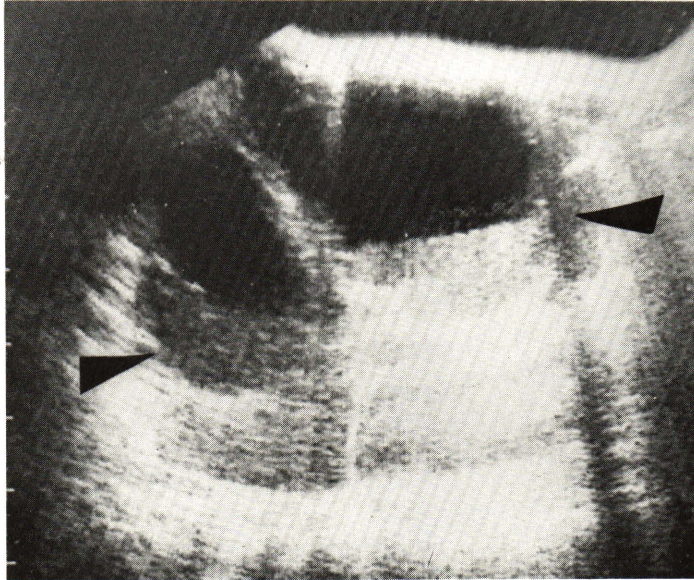


**Fig. 4** Sagittal scan shows an abscess in the right lobe. The echogenic pattern is homogeneous low level echo with central echo-free area. Slight distal sonic enhancement is shown.

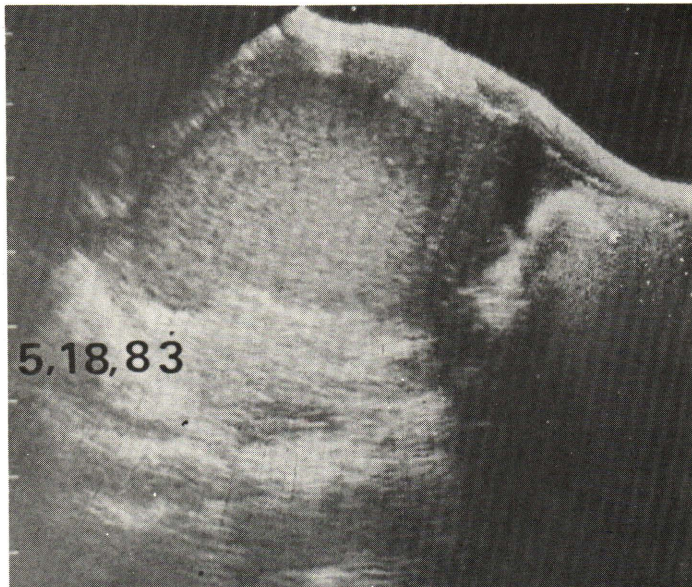


**Fig. 5** Sagittal scan through the right lobe shows a well defined anechoic area with low level echoes at the inferior portion.



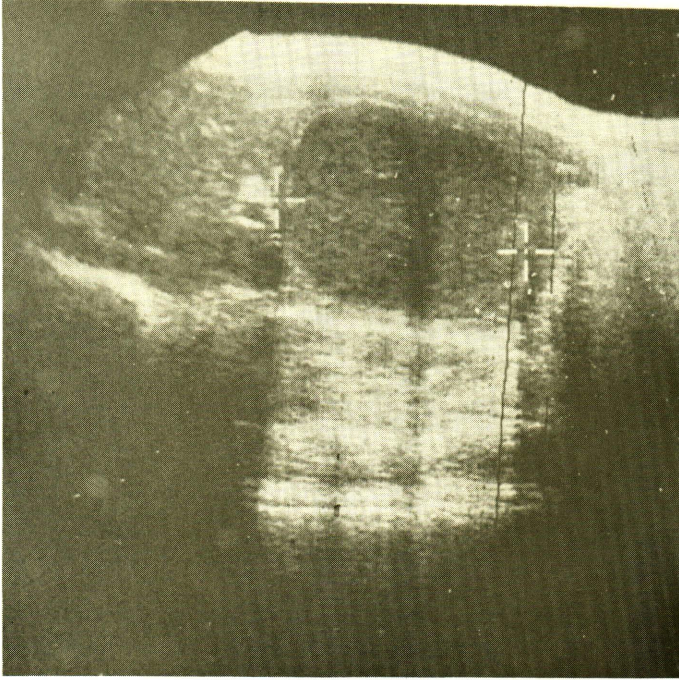


**Fig. 6** Sagittal scan shows two abscesses in the right lobe. Fluid-debris levels and distal sonic enhancement are seen.

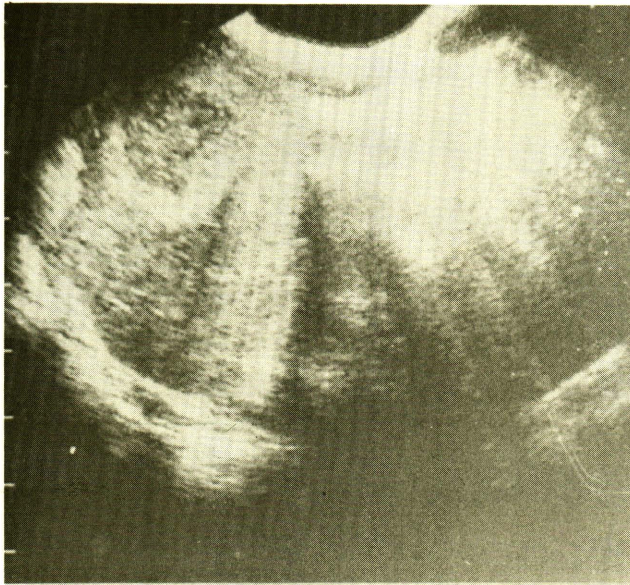


**Fig. 7** Sagittal scan shows a well defined isoechoic area in the right lobe distinguished from normal liver by the peripheral echo free halo. There is distal sonic enhancement.





**Fig. 8** Sagittal scan through the right lobe shows an abscess with thin echogenic wall.



**Fig. 9** Transverse scan of the liver shows a thick wall abscess in the right lobe.



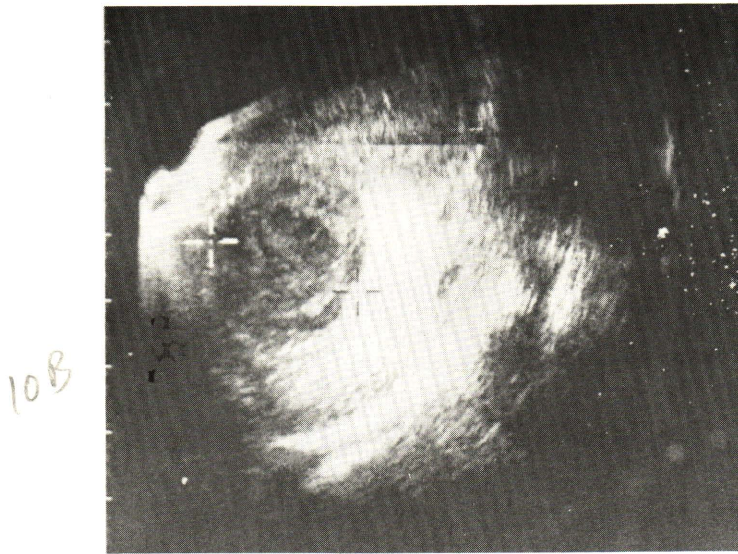


Fig. 10 A. Transverse scan shows an isoechoic lesion with marginal echo free halo.

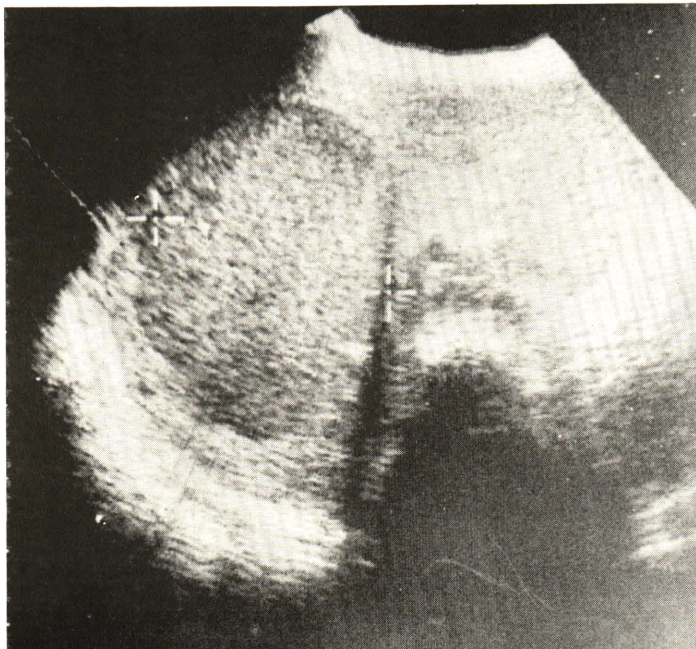
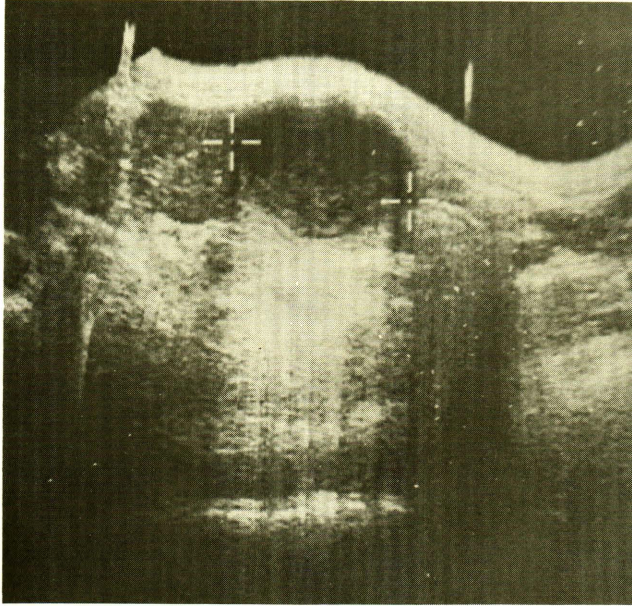


Fig. 10 B. Follow up scan 7 days later shows decrease in the internal echoes and size.



**Fig. 11** Sagittal scan shows two abscesses in the right lobe. The small one is a well defined homogeneous isoechoic area with peripheral echo free halo. Slight distal sonic enhancement is seen. The large one is anechoic lesion containing some internal echoes at the inferior portion. Mark distal sonic enhancement is seen.



**แก้ไขรูป**

**ขออภัย ! รูปในจุฬาลงกรณ์เวชสาร**

**ปีที่ 28 ฉบับที่ 9 กันยายน 2527 หน้า 981**

**เรื่อง Ultrasonography of amoebic liver abscess ของ พ.ญ. เกษร วัชรพงศ์**

**รูปที่ถูกต้องคือ รูปบนเป็นรูป 10B รูปล่างเป็นรูป 10A**

References

1. Ralls PW, Meyers HI, Lapin SA, Rogers W, Boswell WD, Halls J. Gray-scale ultrasonography of hepatic amoebic abscesses. *Radiology* 1979 Jul; 132 (1) : 125-129
2. Dewbury KC, Joseph AEA, Millward Sadler GH, Birch SJ. Ultrasound in the diagnosis of the early liver abscess. *Br J Radiol* 1980 Dec; 53 (636) : 1160-1165
3. Kuligoska E, Connors SK, Shapiro JH. Liver abscess : Sonography in diagnosis and treatment. *AJR* 1982 Feb; 138(2) : 253-257
4. Newlin N, Silver TM, Stuck KJ, Sandler MA. Ultrasonic features of pyogenic liver abscess. *Radiology* 1981 Apr; 139 (1) : 155-159
5. Powers TA, Jones TB, Karl JH. Echogenic hepatic abscess without radiographic evidence of gas. *AJR* 1981 Jul; 137(1) : 159-160
6. Subramanyam BR, Balthazar EJ, Raghavendra BN, Horii SC, Hiltons S, Naidich DP. Ultrasound analysis of solid-appearing abscesses. *Radiology* 1983 Feb 146(2) : 487-491
7. Glancy JJ, Goddard J, Pearson DE. In vitro demonstration of cholesterol crystals' high echogenicity relative to protein particles. *J Clin Ultrasound* 1980 Feb; 8(1) : 27-29
8. Cunningham JJ, Wooten W, Cunningham MA. Gray scale echography of soluble protein and protein aggregate fluid collections (in vitro study) *J Clin ultrasound* 1976 Dec; 4(6) : 417-419
9. Cunningham JJ. In vitro gray scale echography of protein-lipid fluid collections in liver tissue *J Clin Ultrasound* 1976 Aug; 4(4) : 255-258
10. Davis PL, Filly RA, Goerke J. Echogenicity caused by stable microbubbles in a protein-lipid emulsion. *J Clin Ultrasound* 1981 May; 9(5) : 249-252
11. Kurtz AB, Dubbins PA, Rubin CS, Kurtz RJ, Cooper HS, goldberg BB. Echogenicity : analyses, significance and masking. *AJR* 1981 Sep ; 137 (3) : 471-476
12. Aikat BK, Bhusnurmath SR, PAL, AK, Chhuttani PN, DATTA DV. The pathology and pathogenesis of fatal hepatic amoebiasis—a study based on 79 autopsy cases. *Trans R Soc Trop Med Hyg* 1979; 73(2) : 188-192
13. Lushbaugh WB, Kairalla AB, Hofbauer AF, Pittman FE. Sequential Histopathology of cavity liver abscess : formation induced by axenically grown entamoeba histolytica. *Phathol Lab Med* 1980; 104 : 575-579
14. Ravi V, Tandon HD, Tandon BN. Morphological changes in the liver in hepatic amoebiasis. *Indian J Med Res* 1974 Dec; 62(12) : 1832-1836
15. Aikat BK, Bhusnurmath SR, Pal AK, Chhuttani PN, Datta DV. Amoebic liver abscess—a clinicopathological study. *Indian J Med Res* 1978 Mar; 67(3) : 381-391