

Panophthalmitis in the acquired immune deficiency syndrome (AIDS) patient presenting as an acute glaucoma : a case report.

Siripash Ubolsing*
Pakitti Tayanithi*

Ubolsing S, Tayanithi P. Panophthalmitis in the acquired immune deficiency syndrome (AIDS) patient presenting as an acute glaucoma : a case report. Chula Med J 1990 Feb; 35(1):99-103

The acquired immune deficiency syndrome (AIDS) is caused by the human immune deficiency virus (HIV). The ophthalmological manifestations are of special interest. The reported ophthalmic manifestations of AIDS included cotton wool spots, conjunctival Kaposi's sarcoma, retinal periphlebitis and CMV retinitis. One of our patients had an acute unilateral glaucoma secondary to endogenous endophthalmitis and subsequently progressed to panophthalmitis. His HIV antibody was positive. Unfortunately, no proven causative organism was detected in our patient. The patient was treated with antiglaucoma drugs and parenteral antibiotics. The infection was controlled and subsided but the eye became atrophic. The patient was loss to follow up. The ocular infection in association with secondary glaucoma in AIDS patients were reviewed.

Reprint request : Tayanithi P, Department of Ophthalmology, Faculty of Medicine, Chulalongkorn University, Bangkok 10330, Thailand.

Received for publication. August 6, 1990.

ศิริพัช อุบลสิงห์, ปกิตติ ทยานิธิ. แพนออฟทัลไมคิสในผู้ป่วยกลุ่มอาการภูมิคุ้มกันบกพร่องที่มาด้วยอาการของโรคต่อหินเฉียบพลัน. จุฬาลงกรณ์เวชสาร 2534 กุมภาพันธ์; 35(2): 99-103

ในปัจจุบัน กลุ่มอาการภูมิคุ้มกันบกพร่องกำลังได้รับความสนใจอย่างมาก ทั้งในวงการแพทย์และประชาชนทั่วไป อาการทางตาเป็นอาการที่พบได้บ่อย และมักเป็นอาการที่นำคนไข้กลุ่มอาการนี้มาพบแพทย์ ผู้เขียนได้รายงานผู้ป่วย ซึ่งมาโรงพยาบาลด้วยอาการของโรคต่อหินเฉียบพลัน และพบในเวลาต่อมาว่ามีการติดเชื้อของลูกตา และกลุ่มอาการภูมิคุ้มกันบกพร่องร่วมกัน การติดเชื้อภายในลูกตาสุกกลามออกสู่น้ำเยื่อรอบ ๆ ลูกตาอย่างรวดเร็ว ผู้ป่วยได้รับยารักษาโรคต่อหินและยาปฏิชีวนะอย่างเต็มที่ จนสามารถควบคุมการติดเชื้อและทำให้สงบลงได้ อาการทางตาลักษณะนี้พบได้ไม่บ่อยนัก

The acquired immune deficiency syndrome (AIDS) caused by the human immuno deficiency virus (HIV), is a severe disorder of the immune system affecting previously healthy individuals of age below 60 years. Almost all patients have evidences of severe defects of immunoregulation, usually associated with the T-cell component of the immune system. Life-threatening opportunistic infections or Kaposi's sarcoma, or both, occur in persons with no underlying immunosuppressive therapy. At least eight groups have been found to be at special risk of acquiring AIDS⁽¹⁾.

The illness effects on the body are widespread, of special interest are the ophthalmological manifestations. The actual case fatality rate approaches 100%. No effective treatment for the illness is currently available.

The reported ophthalmoscopic manifestations of AIDS included cotton wool spots, conjunctival Kaposi's sarcoma, retinal periphlebitis and CMV retinitis.

One of our patients had an acute unilateral glaucoma secondary to endogenous endophthalmitis and subsequently progressed to panophthalmitis.

A case report

A 30-year-old Thai man came in with a complaint of one-day history of severe ocular pain, nausea, vomiting and inability to see the light in the left eye. His ocular past history was unremarkable.

He had been an intravenous drug (heroin) abuser for more than 10 years and had a history of sharing the needles with his partners. He denied homosexuality, transfusions, or known exposure to patients with AIDS.

The physical examination showed a cachetic man in no acute distress with normal vital signs.

The initial visual acuity was: R.E. : 20/40 and L.E. : no light perception. Intraocular pressure by

applanation tonometry was R.E. : 18 mm.Hg. and L.E. : 50 mm.Hg. Slit-lamp examination of the left eye disclosed diffuse microcystic oedema of the cornea with marked ciliary injection, blepharospasm, lacrimation and steamy cornea. The anterior chamber was shallow peripherally, deep centrally with mild cell and flare. The pupil was 2 mm. in diameter and nonreactive. Iris bombe configuration was not present. There were no posterior synechiae, hypopyon or conjunctival discharge. The right eye was unremarkable except for a reversed Marcus Gunn pupil. The corneal haziness precluded gonioscopy and ophthalmoscope examination of the posterior pole.

An immediate standard B-scan ultrasonography was undertaken and showed moderate vitreous opacity, diffuse choroidal and scleral thickening of the left eye and unremarkable finding on the right eye.

The diagnosis was endogenous endophthalmitis with forward displacement of the lens-iris diaphragm causing secondary glaucoma.

The patient was treated with oral glycerine, oral diamox, topical atropine, timolol and intravenous penicillin, cloxacillin and gentamicin.

12 hours later, the patient had acute left periorbital oedema, proptosis, a markedly chemotic left eye and complete ophthalmoplegia. (Fig. 1,2) Computerized tomography scan showed marked proptosis, soft tissue swelling of the lid, diffuse thickening of the sclera, increased density of vitreous and irregular enhancement of all orbital structures on the left side. The sinuses were normal. Despite aggressive intravenous antibiotic therapy a ring-shaped peripheral corneal abscess in association with a central abscess developed. The result of the haemoculture and conjunctival culture revealed no bacterial growth. Antibody to HIV was positive.

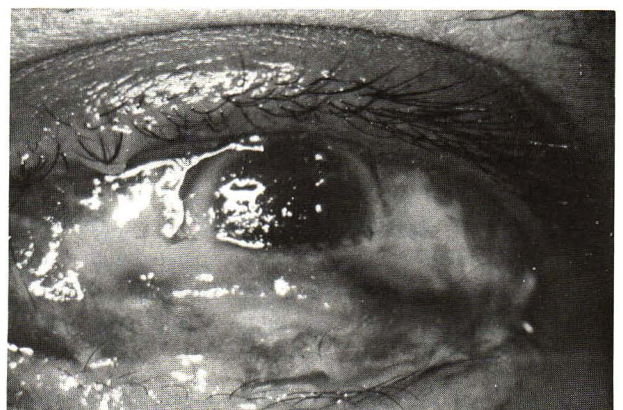
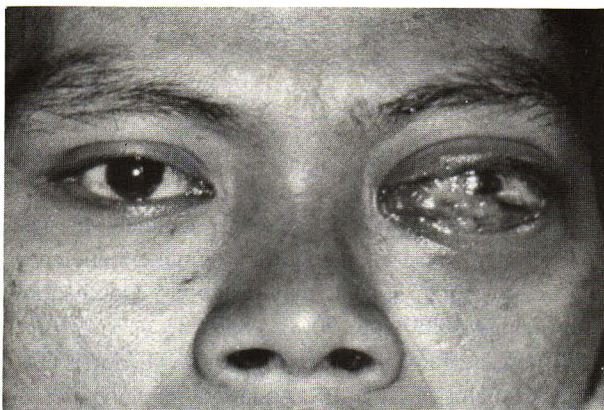

Figure 1,2 The patient had acute left periorbital edema, proptosis, a markedly chemotic left eye and complete ophthalmoplegia.

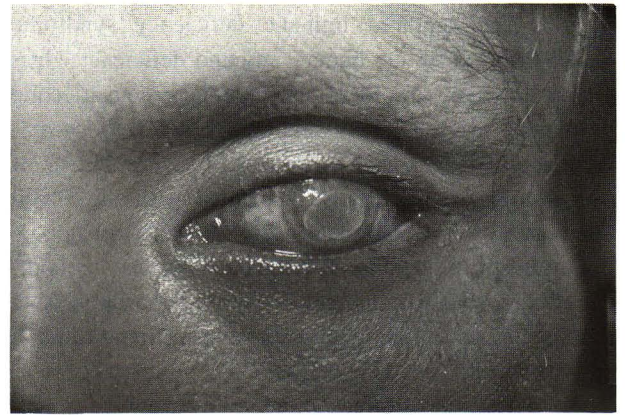
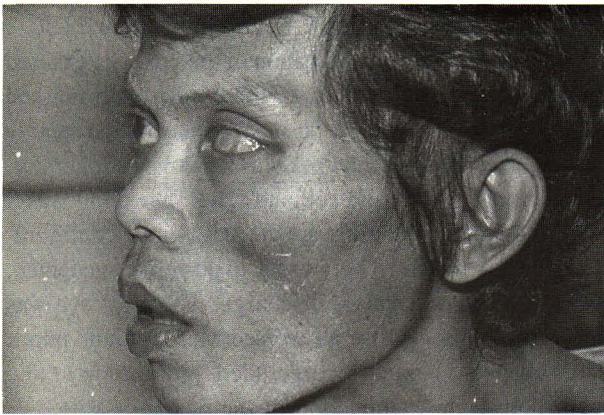
Figure 3,4 After five days of the treatment, the proptosis and chemosis decreased.

After five days of the above therapy the proptosis and chemosis decreased (Fig. 3,4). Evisceration was refused. The left eye became atrophic, the patient was lost to follow up.

Discussion

Ocular disease is a frequent feature of AIDS. A variety of ocular disorders in association with this syndrome was described^(1,2). Among the prominent ocular abnormalities seen have been cotton wool spots and cytomegalovirus retinitis⁽³⁻⁶⁾.

Grossniklaus et al⁽⁹⁾ had reported two young male intravenous drug abusers who were treated for acute glaucoma in the left eye and who proved to have *Bacillus cereus* panophthalmitis within 24 hours. The recent article by Ullman et al⁽¹⁰⁾ reported an AIDS related ocular manifestation in a drug abuser, *Bacillus cereus* panophthalmitis.

Our patient had a combination in some parts of the reported cases., A drug abuser who had AIDS, presented with acute glaucoma secondary to endophthalmitis in the left eye and progressed to panophthalmitis in 24 hours.

References

1. Holland GN, Gottlieb MS, Yee RD, Schanker HM, Pettit TH. Ocular disorders associated with a new severe acquired cellular immunodeficiency syndrome. *Am J Ophthalmol* 1982 Apr; 93(4) : 393-402
2. Smolin G, Friedlaender MH, et al. AIDS and ophthalmology, *Int Ophthalmol Clin* 1989 summer; 29(2) : 70-135
3. Holland GN, Pepose JS, Petter TH, Gottlieb MS, Yee RD, Foos Ry. Acquired humune deficiency syndrome. Ocular manifestations. *Ophthalmology* 1983 Aug; 90(8) : 859-73
4. Rosenberg PR, Uliss AE, Friedland GM, Harris CA, Small CB, Klein RS. Acquired immunodeficiency syndrome. Ophthalmic manifestation in ambulatory patients. *Ophthalmology* 1983 Aug; 90(8) : 874-3

To our knowledge, the association of intravenous drug abuse and endogenous *B.cereus* infection is well known^(11,12) It was shown to be the most common bacterial contaminant in the injection paraphernalia of drug addicts⁽¹³⁾. Unfortunately no proven causative organism was found in our patient.

Summary

A 30-year-old Thai male intravenous drug abuser, with postive antibody to HIV, presented with an acute glaucoma secondary to endogenous endophthalmitis in his left eye and rapidly deteriorated into panophthalmitis. No definite causative organism was detected. The infection and inflammation could be controlled with medications. However the eye eventually developed phthical eye and the patient was lose to follow up.

Acknowledgement

The authors would like to thank Mrs. Sawanee Panarum with regard to the preparation of this manuscript.

5. Bachman DM, Rodrigues MM, Chu FC, Straus SE, Cogan DG, Macher AM. Culture-proven cytomegalovirus retinitis in a homosexual man with the acquired immunodeficiency syndrome. *Ophthalmology* 1982 Jul; 89(7) : 797-804
6. Neuwirth J, Gutman I, Hofeldt AJ, Behrens M, Marquardt MD, Abramovsky Kaplan I, Kelsey P. Cytomegalovirus retinitis in a young homosexual male with acquired immunodeficiency. *Ophthalmology* 1982 Jul; 89(7) : 805-8
7. Newman NM, Mandel MR, Gullet J, Fujikawa L. Clinical and histologic findings in opportunistic ocular infections; part of a new syndrome of acquired immunodeficiency. *Arch Ophthalmol* 1983 Mar; 101(3) : 396-401
8. Khadem M, Kalish SB, Goldsmith J, Fetkenhour C, O'Grady RB, Phair JP, Chrobak M. Ophthalmologic findings in acquired immune deficiency syndrome (AIDS). *Arch Ophthalmol* 1984 Feb; 102(2) : 201-6
9. Grossenklaus H, Bruner WE, Frank KE, Purnell EW. *Bacillus cereus* panophthalmitis appearing as acute glaucoma in a drug addict. *Am J Ophthalmol* 1985 Aug; 100(2) : 334-5
10. Ullman S, Pflugfelder SC, Hughes R, Forster RK. *Bacillus cereus* panophthalmitis manifesting as an orbital cellulitis. *Am J Ophthalmol* 1987 Jan; (103(1) : 105-6
11. Hatem G, Merritt JC, Cowan CJ Jr. *Bacillus cereus* panophthalmitis after intravenous heroin. *Ann Ophthalmol* 1979 Mar; 11(3) : 431-40
12. McLane NJ, Carroll DM. Ocular manifestations of drug abuse. *Surv Ophthalmol* 1986 Mar-Apr; 30(5) : 298-313
13. Tuazon CU, Hill R, Sheagren JN. Microbiologic study of street heroin and injection paraphernalia. *J Infect Dis* 1974 Mar; 129(3) : 327-9