

Retinoblastoma at Chulalongkorn Hospital

Pairoj Pipitsangjan*
Siripash Ubolsing*

Pipitsangjan P, Ubolsing S. Retinoblastoma at Chulalongkorn Hospital. Chula Med J 1991 Feb; 35(2) : 83-89

This retrospective study was done from the medical records of patients who had proven histological diagnosis of retinoblastoma in Chulalongkorn University Hospital from January 1982 to December 1989. There were 30 patients in 8 years with an average of 3.85 cases per year. The age range at time of diagnosis was from 2 months - 5 years (mean 2 2/12 years). There was a slight preponderance in males (56.7%). In this series, 20 patients had unilateral (66.7%) and 10 patients had bilateral (33.3%) tumors. The most frequent presenting symptom was leukocoria (60%). Positive tumor cells in the bone marrow were found in 4/28 cases (14.3%). The tumors extended to the optic nerve in 13/30 cases (43.3%). Treatment for this tumor depended on the degree of bilaterality and extent of the tumor.

Reprint request : Pipitsangjan P, Department of Ophthalmology, Faculty of Medicine, Chulalongkorn University, Bangkok 10330, Thailand.

Received for publication. October 19, 1990.

ไพโรจน์ พิพิชแสงจันทร์, ศิริพัช อุบลสิงห์. เนื้องอกเรติโนบลาสโตมาในโรงพยาบาลจุฬาลงกรณ์. จุฬาลงกรณ์
เวชสาร 2534 กุมภาพันธ์: 35(2) : 83-89

การศึกษาย้อนหลังผู้ป่วยเนื้องอกเรติโนบลาสโตมา (Retinoblastoma) จากบันทึกทะเบียนประวัติผู้ป่วย
ในช่วงตั้งแต่เดือนมกราคม 2525 - ธันวาคม 2532 รวมระยะเวลา 8 ปี มีจำนวนผู้ป่วยทั้งหมด 30 คน คิดเป็น
อุบัติการณ์ 3.85 รายต่อปี ช่วงอายุที่ผู้ป่วยมาตรวจและได้รับการวินิจฉัยตั้งแต่อายุ 2 เดือน - 5 ปี (เฉลี่ย 2 2/12 ปี)
พบเป็นเด็กผู้ชายมากกว่าเด็กผู้หญิงเล็กน้อย (17 : 13) ผู้ป่วยที่เป็นเนื้องอกตาเดียวมี 20 ราย (66.7%) และที่เป็น
ทั้ง 2 ตา มี 10 ราย (33.3%) อาการนำที่พบบมากที่สุดคือ การเห็นรูม่านตามีสีขาว (ที่กลางตาคำ) (Leukocoria)
พบ 18 ราย (60%), จากการตรวจไขกระดูกในผู้ป่วย 28 ราย พบว่ามีเพียง 4 ราย ที่มีเซลล์มะเร็งกระจายเข้าสู่
ไขกระดูก และการตรวจทางพยาธิวิทยาทั้ง 30 ราย พบว่ามีเนื้องอกที่กระจายสู่เส้นประสาทออปติค (optic nerve)
13 ราย สำหรับรักษาเนื้องอกชนิดนี้ขึ้นกับความรุนแรง, การเป็นข้างเดียวหรือทั้งสองข้าง, การกระจายของเนื้องอกสู่
ส่วนต่างๆ และความสนใจของญาติผู้ป่วยในการยินยอมรักษา

Retinoblastoma is the most common intraocular malignancy of childhood, and occurs in approximately 1 in 17,000 - 34,000 of live births.⁽¹⁾ Retinoblastoma may be present at birth or may arise in the retina during the first few years of life. The tumor usually remains confined to the eye for months or several years, but it may metastasize by various routes and if untreated is almost invariably fatal.

There is no racial or sexual predisposition. Only 6% of patients have a family history of retinoblastoma. The tumor has been proved to be autosomal dominant

with approximately 80% penetrance. However the majority of cases are sporadic. Even sporadic cases will transmit to offspring in about 10-15% of cases.⁽¹⁾ When a child with retinoblastoma is born to normal parents with no family history of the disease, there is a 1% chance that subsequent children will have retinoblastoma.

The common symptoms and sign are leukocoria (white pupil) and proptosis (fig 1,2). Some of the patients may present with uncommon signs such as squint, spontaneous hyphema, blurred vision, endophthalmitis and secondary glaucoma, etc.

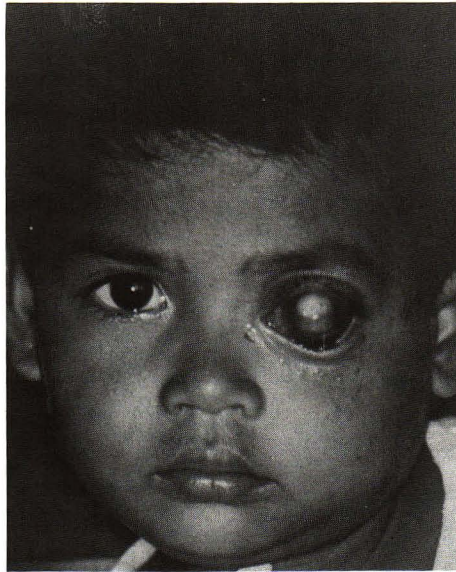


Figure 1. The retinoblastoma patient shows proptosis of left eye.

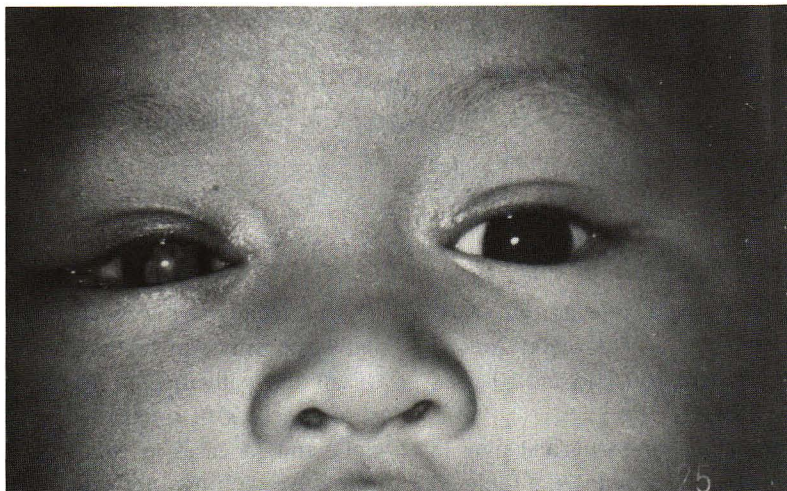


Figure 2. The other patient shows leukocoria of right eye.

The diagnosis depend on finding yellow - white mass by indirect ophthalmoscopy and calcification in the orbital roentgenogram. Definitive diagnosis is made by histopathological examination of the tumor.

The number of cases has gradually increased, probably due to early diagnosis and treatment, as well as to prolong survival of the hereditary cases and their offspring.

The treatment of retinoblastoma depends on size, location extension of the tumor and acceptance of the parents.^(2,3) For unilateral cases, if the tumor is small and confined to the globe, it may be treated with photocoagulation or cryotherapy. After therapy the children should be followed up regularly. Enucleation is indicated in large tumor and for the tissue diagnosis. If the tumors extend beyond the globe, the enucleation followed by radiation and chemotherapy are suggested.

For bilateral cases, the enucleation in the more advanced eye is performed and the second eye is treated in the same manner as in unilateral cases.

Material and Method

A retrospective study was done from the medical records of patients who had been proved histologically to have retinoblastoma, in the ophthalmology Department, Chulalongkorn Hospital from January 1982 to December 1989. This report includes incidence, age, sex difference, bilateral cases compared to unilateral cases, presenting symptoms, bone marrow examination, extension of tumor and treatment.

Result

- There were 30 patients in 8 years with the average of 3.85 cases per year. The incidence in male was slightly higher than in female with the ratio of 17 :13. (Table 1)

Table 1. Incidence of Pathological Diagnosis of Retinoblastoma in Chulalongkron Hospital.

Year	Number of patient		
	Male	Female	Total
1982	3	2	5
1983	1	3	4
1984	2	1	3
1985	3	2	5
1986	-	1	1
1987	4	1	5
1988	2	2	4
1989	2	1	3
Total	17 (56.7%)	13 (43.3%)	30 (100%)

The age ranged from 2 months - 5 years. The mean age at first visit was 2 2/12 years. Among 30 cases, 20 cases were unilateral (66.7%) and 10 cases were bilateral (33.3%) (Table 2)

The frequent presenting symptoms and signs in this report were leukocoria, and proptosis. (Table 3)

Bone marrow aspiration was done in 28 cases and was positive for retinoblastoma in 4 cases (14.3%). Of all the pathological reports in 30 patients, there were 16 cases of tumors which were confined to the globe and 14 cases in which the tumors had extended to involve the optic nerve as well (Table 4.)

Table 2. The Presenting age and laterality.

Age (year)	Unilateral	Bilateral	Total
less than 1 year	3	3	6
1+ - 2	4	3	7
2+ - 3	8	4	12
3+ - 4	3	-	3
4+ - 5	2	-	2
Total	20 (66.7%)	10 (33.3%)	30 (100%)

Table 3. The presenting symptoms and signs.

Symptoms & Signs	Number of patient	
Leukocoria	18	(60%)
Proptosis	9	(10%)
Strabismus	1	(3.3%)
Trauma	1	(3.3%)
Poor vision	1	(3.3%)

Table 4. The pathological examination.

Intraocular tumor	16
Intraocular with sclera, choroid and optic nerve involvement	11
Intraocular with optic nerve and retrobulbar tissue involvement	3

Table 5. Treatment of Unilateral cases.

Enucleation	8 cases
Enucleation + Radiation	5 cases
Enucleation + Radiation + Chemotherapy	7 cases

Table 6. Treatment of bilateral cases.

1 st eye : - Enucleation	10 cases
2 nd eye : - Enucleation	3 cases
Cryotherapy	2 cases
Chemotherapy + Radiation	2 cases
Refuse treatment	3 cases

Discussion

The incidence of retinoblastoma was reported at Ramathibodi Hospital in 1970 - 1982 as 7.5 cases per year,⁽⁴⁾ at Siriraj Hospital in 1965 - 1970 as 16 cases per year,⁽⁵⁾ at Chulalongkorn Hospital in 1963 - 1968 as

4.5 cases per year⁽⁶⁾ and another one in 1972 - 1977 as 3.83 cases per year⁽⁷⁾ The present study report an incidence of 3.85 cases per year.

The age incidence and the degree of bilaterality among various series is indicated in Table 7.

Table 7. The age and sites involved compared with other series.

Hospital	Age			Site involve(%)	
	Year	Range	Average	Uni.	Bil.
Chulalongkorn ⁽⁶⁾	1963-1968	5 mo-5 yr	3 1/12 yr	85%	15%
Siriraj ⁽⁵⁾	1965-1970	4 mo-7 yr	2 11/12 yr	88.8%	11.2%
Ramathibodi ⁽⁴⁾	1970-1982	1 1/2 mo- 6 1/2 yr	2 6/12 yr	71.11%	28.89%
Chulalongkorn ⁽⁷⁾	1972-1977	1 5/12 mo- 7 yr	3 7/12 yr	73.9%	26.1%
Chulalongkorn *	1982-1989	2 mo-5 yr	2 2/12 yr	66.7%	33.3%

* = The present report

The age of onset in the present report tends to be younger than in previous reports. There was a slight preponderance in male, as in the other studies.⁽⁴⁻⁷⁾ The incidence of bilateral case is slightly increased and found more in younger patients than that of unilateral case. (Table 2,7)

The most common presenting symptom in this report is leukocoria, the same as that reported from Ramathibodi Hospital⁽⁴⁾ and San Francisco.⁽⁸⁾

The other previous series⁽⁵⁻⁷⁾ showed proptosis as the most common presenting symptom. This means that in the present report, the patients came in earlier than those in the previous reports.^(4,5) The tumor is still confined to the globe. Also the pathological examina-

tion shows that more than a half of the cases are intraocular tumors. (Table 4.)

The result of treatment in this report cannot be shown because many patients are lost to follow up.

Summary

There were 30 histologically proven retinoblastoma patients in the Chulalongkorn Hospital during January 1982 - December 1989. The age ranged from 2 months to 5 years, 33.3% of case were bilateral, 66.7% of cases were unilateral. The most frequent symptom was leukocoria. In 14.3% of cases the tumor cell was found in the bone marrow, and in 46.7% of cases the tumor extended to the optic nerve. The treatment was dependent on size, location extension and laterality of tumors.

References

1. Ellsworth R.M. Retinoblastoma. In : Duane TD, Jaeger EA, eds. *Clinical Ophthalmology*. Vol. 3. rev. ed. Philadelphia : Harper & Row, 1987. 1-18
2. Franufelder FT, Roy FH, Meyer SM, eds. *Current Ocular Therapy* Vol. 3. Philadelphia : W.B. Saunders, 1990. 306-8
3. American Academy of Ophthalmology. *Focal points* 1990, Clinical Modules Academy of Ophthalmologists. Vol. 8. Retinoblastoma. 1-2
4. Kunarisarut Skowrat, Hathirat Phongjan, Kitsukchit Songyod. Retinoblastoma in Ramathibodi Hospital, *J Med Assoc Thai* 1987 Jul; 70(7) : 397-400
5. Laosunthorn M. Retinoblastoma; *Siriraj Hosp Gaz* 1972 Apr; 24(4) : 472-9
6. Leelawong N, Piloksiri S. Retinoblastoma, *Chula Med J* 1970 Jul; 15(3) : 234-50

7. ศิริพัช อุบลสิงห์. การศึกษาเรื่อง Retinoblastoma เสนอ
บทความในการประชุมวิชาการใหญ่ประจำปี 2521 ของ
คณะแพทยศาสตร์ จุฬาลงกรณ์มหาวิทยาลัย, เอกสาร
ประกอบคำบรรยาย, 2521.
8. American Academy of Ophthalmology. Pediatric
Ophthalmology and Strabismus. section 6.
San Francisco, 1989-1990.