

The ultrasound diagnosis of neonatal adrenal hemorrhage.

Darunee Boonjunwetwat*
Wunchai Laoprasert*

Boonjunwetwat D, Laoprasert W. The ultrasound diagnosis of neonatal adrenal hemorrhage. Chula Med J 1989 Jun; 33(6) : 443-448

Neonatal adrenal hemorrhage may be diagnosed accurately by serial ultrasound studies. Initially, ultrasonography characteristically shows a hyperechoic mass in the suprarenal area. Subsequent serial ultrasound scans show decreasing echogenicity of the mass which becomes cystic in appearance within two weeks. Ultrasound helps to differentiate adrenal hemorrhage from tumor and avoid the unnecessary operation. The procedure is easily performed, noninvasive, low cost and lacking in radiation effect.

Reprint request : Boonjunwetwat D, Department of Radiology, Faculty of Medicine, Chulalongkorn University, Bangkok 10330, Thailand.

Received for publication. June 8, 1989.

ครุณี บุญยืนเวทวัฒน์, วันชาติ เล้าประเสริฐ. การวินิจฉัยภาวะเลือดออกของต่อมหมวกไตในทารกแรกเกิด ด้วยคลื่นเสียงความถี่สูง. จุฬาลงกรณ์เวชสาร 2532 มิถุนายน: 33 (6) : 443-448

รายงานผู้ป่วยทารกแรกเกิด 1 ราย มีภาวะเลือดออกที่ต่อมหมวกไต ได้รับการวินิจฉัยด้วยคลื่นเสียงความถี่สูง (อัลตราซาวด์) โดยการตรวจซ้ำ 3 ครั้ง ภายในระยะเวลา 2 อาทิตย์ พบลักษณะภาพอัลตราซาวด์ของต่อมหมวกไต ในครั้งแรกเป็นก้อนขนาดใหญ่ที่มี *echo* สูง หลังจากนั้นติดตามการตรวจซ้ำอีก 3 ครั้ง พบมีการเปลี่ยนแปลงของ *echo* ภายในก้อนจะลดลงจนมีลักษณะเป็น *sonolucent* ภายใน 2 อาทิตย์ ซึ่งบ่งชี้ว่าเป็นของเหลวหรือน้ำ จากผลการเปลี่ยนแปลงของลักษณะภาพในก้อนโดยการตรวจด้วยอัลตราซาวด์ซ้ำหลายครั้ง ช่วยให้สามารถวินิจฉัยภาวะเลือดออกของต่อมหมวกไตได้ถูกต้องแม่นยำ ซึ่งเป็นวิธีการตรวจที่เหมาะสมที่สุดสำหรับทารกแรกเกิด สามารถทำได้ง่ายและติดตามการตรวจได้หลายครั้ง โดยไม่มีผลเสียต่อทารก เพราะปราศจากการใช้รังสี

Adrenal hemorrhage in the new born occurs most frequently between the second and seventh day of life.⁽¹⁾ The presenting symptoms vary with the degree of bleeding. Classical clinical features of massive adrenal hemorrhage in the new born are signs of blood loss, jaundice and palpable mass.^(2,3) Imaging diagnosis must be performed to evaluate the nature of the mass. Intravenous urogram is helpful to the diagnosis by demonstrating a relatively radiolucent area in the suprarenal fossa with displacement of kidney outward and inferiorly^(2,4,5) The diagnosis depends on the renal function, as the collecting systems are sometimes poorly visualized and obscured by overlying gas.⁽⁶⁾ Ultrasound is extremely useful in diagnosing adrenal hemorrhage, because of its noninvasive nature, high accuracy and lack of radiation. Serial follow up examinations are easily performed.^(6,7) The characteristic features of adrenal hemorrhage have been described in the literatures. This report presents a case of neonatal adrenal hemorrhage diagnosed by follow up ultrasound study, and the classical ultrasonographic appearance of adrenal hemorrhage.

Case report

A 2,950 grams female infant at term, product of a gravidal, paral 1,25-year-old mother, was delivered at 40 weeks by forceps owing to the 3 days premature

ruptured membrane. Her apgar scores were 9. The physical examination was normal at birth. At the age of 16 hours, she refused feeding and appeared drowsy. Physical examination revealed pallor with signs of shock. A mass was palpated at right flank. Hematocrit was 36%. The blood smear was compatible with acute blood loss. The blood urea was normal. The serum creatinine was elevated. The urine contained protein ++ and 15 red blood cells per high power field. Ultrasound was performed. The technique of ultrasonography was simple. The infant was in prone and decubitus position. Both transverse and longitudinal scans were obtained, using 5 MHz linear array phase transducer. Abdominal ultrasonography showed an inhomogeneous hyperechoic mass with small sonolucent area at superior aspect of right kidney (Fig. 1A). The right kidney appeared normal and displaced inferiorly. Serial ultrasound scans were performed at 3,7 and 14 days intervals. The echogenicity of the mass gradually decreased and turned to cystic appearance (Fig. 1 B, C, D). Minimal free fluid was also noted at left suprarenal fossa (Fig. 2). Adrenal hemorrhage was diagnosed. The infant was treated with blood transfusion and antibiotics. The palpable mass decreased in size. The infant was discharged after 17 days of hospitalization.

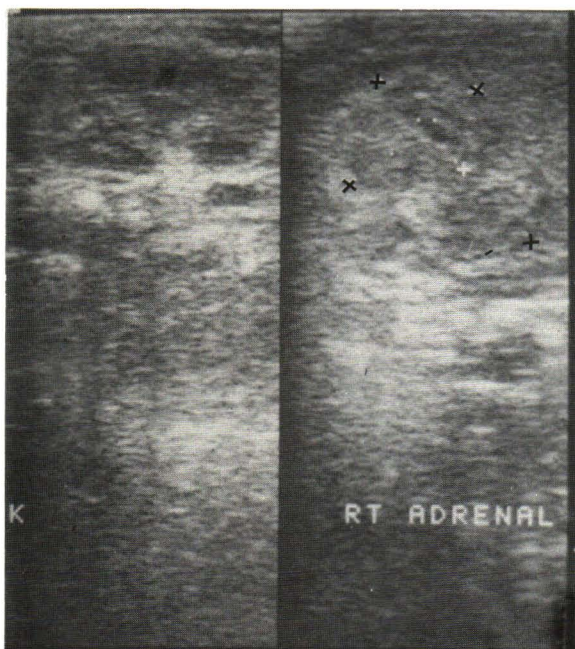


Figure 1A. Right adrenal hemorrhage. Longitudinal scan showing a hyperechoic mass (++) with small sonolucent area at right suprarenal fossa.

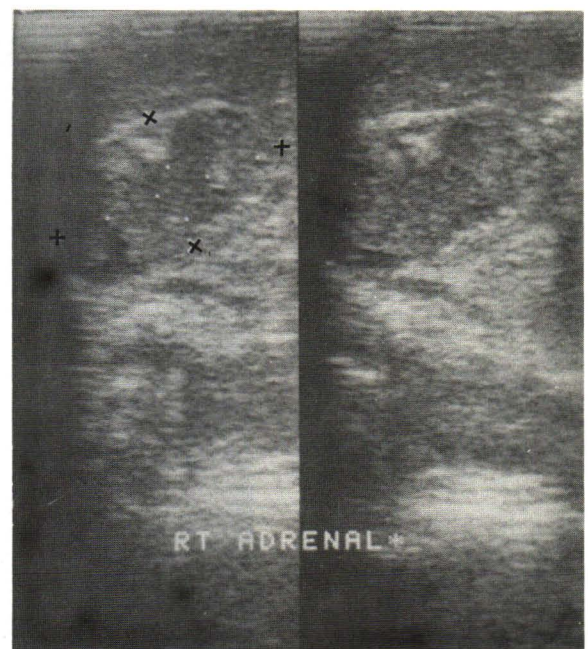


Figure 1B. Following scan 3 days later showing decrease in echogenicity of the mass (++)

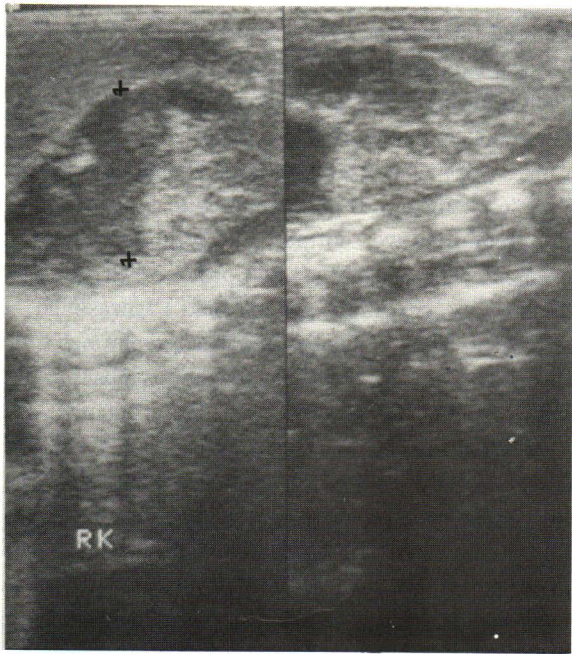


Figure 1C. Follow up scan 7 days later showing further decreased echogenicity of the mass (+ +).

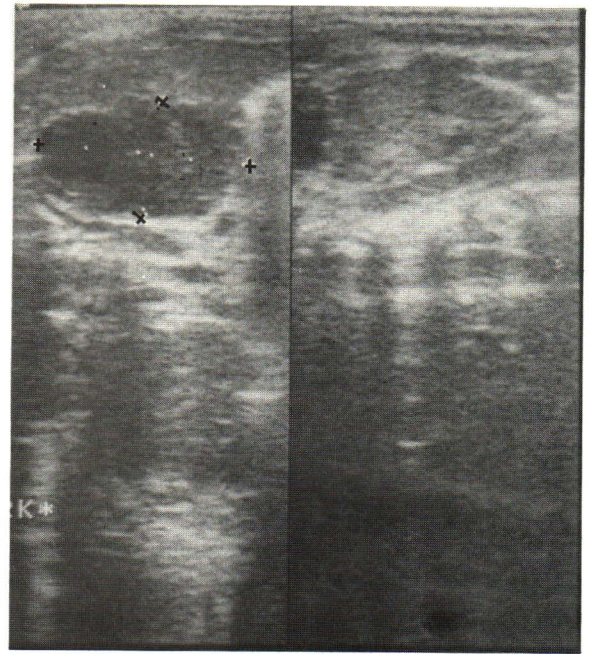


Figure 1D. Follow up scan 14 days later showing decreased echogenicity of the mass which became cystic in appearance (+ +).

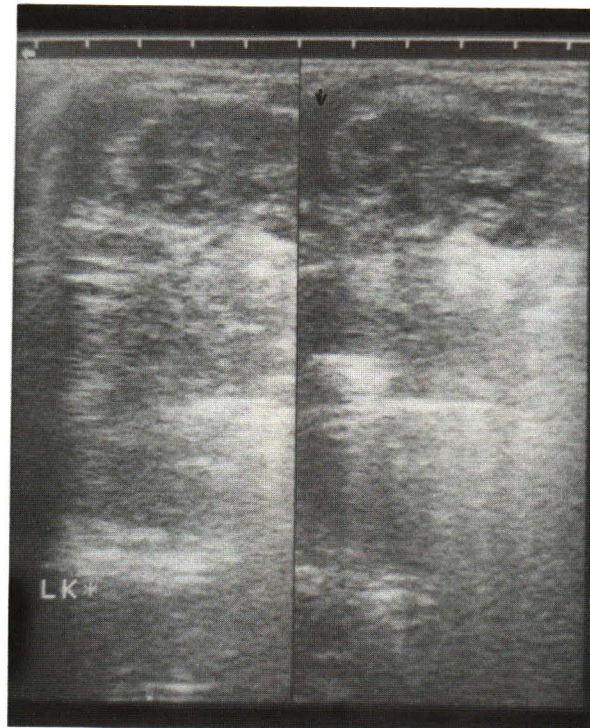


Figure 2. Left adrenal fossa. Longitudinal scan showing free fluid at left suprarenal fossa (↑).

Discussion

The surviving infant with adrenal hemorrhage was first reported by Corcoran and Strauss in 1924.⁽⁸⁾ The incidence in survivors is difficult to ascertain. One autopsy series reported neonatal adrenal hemorrhage as 1.7 in every 1,000 births.^(6,9) The etiology is unknown. The common accepted causes are trauma during birth including prolong labor, abnormal presentations, forcep delivery and vigorous resuscitative measures.^(3,5) Other etiologic factors are fetal hypoxia, septicemia, thrombocytopenia, coagulation defect, disseminated thromboembolic disease, hemorrhagic disease of the new born and syphilis.^(1,2,5) Massive adrenal hemorrhage is frequently found on the right side. The explanation for two sided difference in susceptibility of adrenal hemorrhage alludes to the venous drainage. The right adrenal vein drains directly into the inferior vena cava. When there is a rise in pressure in the inferior vena cava, causing passive distension and engorgement of the draining vein, thrombosis and hemorrhage occur.^(1,2,10) On the left side, the adrenal vein joins the renal vein which also receives the first lumbar and internal spermatic (or ovarian) veins, as well as frequently communicating with the hemiazygos which drains into superior vena cava; thus a rise in pressure in the inferior vena cava will be conducted away through these communicating veins. Another theory explains that the right adrenal gland has the greater susceptibility to hemorrhage because of the compression between the liver and spine.^(2,10) Besides, Bargmann, 1933 and Heinivaara 1954, found that the new born adrenal gland is different from the adult. The adrenal vein, the central vein and its medullary branches of the new born adrenal gland are absent of bundles of longitudinal muscle fibers as found in the adult gland. When the muscle bundles contract, the lumen of the adrenal vein is narrow and act as a protection against a sudden transient pressure increase in the inferior vena cava. In new born, this protective mechanism against increased pressure in the inferior vena cava, as might occur with abdominal compression during delivery, is absent leading to venous congestion and hemorrhage.⁽¹⁾

The frequently presenting symptoms are anemia, hypotensive shock, jaundice and flank mass which are

caused by bleeding, formation of hematoma and resorption of the blood.^(1,5,7,11,12) Adrenal insufficiency is rare.⁽¹⁾ Urine examination shows proteinuria and hematuria.⁽⁵⁾ Neonatal adrenal hemorrhage can be diagnosed accurately by clinical presentation and investigations. Excretory urogram of adrenal hemorrhage shows a radiolucent mass in the suprarenal area. The kidney is displaced downward.^(2-4,6) Round or peripheral or thin line calcification of the mass may be found in the follow up plain film within 3 or 4 weeks, or as early as 12 days after hemorrhage.⁽¹³⁾ The calcification shrinks and becomes the shape and size of the original adrenal gland which persists for life.⁽¹⁾ Nowadays, ultrasound plays the most important role in diagnosis of adrenal hemorrhage. The diagnosis is made by serial follow up scans. In the early phase of bleeding, the ultrasonographic pattern of the mass often shows hyperechoic or complex mass.^(5-7,11) Follow up scans show decrease in echogenicity and size of the mass. The mass turns cystic like and anechoic due to lysis and resorption of the blood.^(5,11) The ultrasound gives the early diagnosis for the proper management. The differential diagnosis of the hyperechoic or complex mass at the suprarenal area in the infant include neuroblastoma, hamatoma, and abscess.^(2,3,5-7,10,14,15) Pheochromocytomas have been reported.⁽¹⁴⁾ Follow up ultrasound studies has a role in establishing the diagnosis, since neuroblastoma often shows progression of the mass and metastasis to liver, or skin involvement.^(3,5) In the cystic form, the differential diagnosis include abscess, parasitic, epithelial, endothelial and pseudocysts.^(10,14)

Treatment of neonatal adrenal hemorrhage is conservative with blood transfusion and antibiotics. Intravenous corticosteroid is given in the severely shocked or bilateral cases.⁽¹⁰⁾ Adrenal insufficiency is the late complication and rarely found.⁽³⁾ Surgical exploration is needed in the case of severe uncontrolled bleeding or abscess formation.^(10,14)

Conclusion

This report presented a case neonatal adrenal hemorrhage. The clinical symptoms were anemia, shock and right flank mass with history of forcep extraction. The diagnosis was made by serial ultrasound studies.

อ้างอิง

1. Black J, Williams DI. Natural history of adrenal hemorrhage in the newborn. Arch Dis Child 1973 Feb; 48(258) : 183-90
2. Kuhn J, Jewett T, Munschauer R. The clinical and radiographic features of massive neonatal adrenal hemorrhage. Radiology 1971 Jun ; 99(3) : 647-52

3. Sober I, Hirsch M. Unilateral massive adrenal hemorrhage in newborn infant. *J Urol* 1965 Apr ; 93(4) : 430-4
4. Brill PW, Krasna IH, Aaron H. An early rim sign in neonatal adrenal hemorrhage. *AJR* 1976 Aug ; 127(2) : 289
5. Mittelstaedt CA, Volberg FM, Merten DF, Brill PW. The conographic diagnosis of neonatal adrenal hemorrhage. *Radiology* 1979 May ; 131(2) : 453-8
6. Lawson EE, Teele RL. Diagnosis of adrenal hemorrhage by ultrasound. *J Pediatr* 1978 Mar ; 92(3) : 423
7. Mineau DE, Koehler PR. Ultrasound diagnosis of neonatal adrenal hemorrhage: case report. *AJR* 1979 Mar; 132(3) : 443
8. Corcoran WJ, Strauss AA. Suprarenal hemorrhage in the newborn. *JAMA* 1974 Feb 23; 82(8) : 626-8
9. De Sa DJ, Nicholls S. Hemorrhagic necrosis of the adrenal gland in perinatal infants: a clinico-pathological study. *J Pathol* 1972 Mar; 106(3) : 133-50
10. Khuri FJ, Alton DJ, Hardy BE, Cook GT, Churchill BM. Adrenal hemorrhage in neonates: report of 5 cases and review of the literatures. *J Urol* 1980 Nov; 124(5) : 684-7
11. Cohen EK, Daneman A, Stringer DA, Sota C, Thorner P. Focal adrenal hemorrhage : a new US appearance. *Radiology* 1986 Dec; 161(3) : 731-3
12. Rose J, Berdon WE, Sullivan E. Prolong jaundice as presenting sign of massive adrenal hemorrhage in newborn. *Radiology* 1971 Feb ; 98(2) : 263
13. Wagner AC. Bilateral hemorrhagic pseudocyst of the adrenal gland in a newborn. *AJR* 1961 Sep; 86(3) : 540-5
14. Favara BE, Akers DR, Franciosi RA. Adrenal abscess in a neonate. *J Pediatr* 1970 Oct ; 77(4) : 682-5
15. Guin GH, Gilbert EF, Jones DB. Incidental neuroblastoma in infants. *Am J Clin Pathol* 1969 Jan ; 51(1) : 126-36
16. Barron SH, Emanuel B. Adrenal cyst : a case report and a review of the pediatrics literature. *J Pediatr* 1961 Oct ; 59(4) : 592-9