

# Transscleral sutured posterior chamber intraocular lens implantation technique: Double suture without scleral flap at King Chulalongkorn Memorial Hospital, 1995-2003

Prasart Laksanaphuk\*

Pirunrat Jiaraksuwan\* Sirichai Pasadhika\*

**Laksanaphuk P, Jiaraksuwan P, Pasadhika S. Transscleral sutured posterior chamber intraocular lens implantation technique: Double suture without scleral flap at King Chulalongkorn Memorial Hospital: 1995 - 2003. Chula Med J 2007 May - Jun; 51(5): 255 - 62**

**Objective** : *To describe a surgical technique of scleral suturing of posterior chamber intraocular lens (IOL) (double suture without scleral flap), and to evaluate surgical results and their complications.*

**Setting** : *Department of Ophthalmology, King Chulalongkorn Memorial Hospital*

**Design** : *Retrospective descriptive non-comparative case series.*

**Method** : *Medical records of patients who had scleral sutured posterior chamber intraocular lens implantation without the use of scleral flap were reviewed. All procedures were performed by a single surgeon (PL). Pre - and post-operative best corrected visual acuities were compared. Lens centration and postoperative complication were evaluated.*

**Results** : *The mean pre-operative age was 55 years. Ninety percent (36 of 40 eyes) had improvement of best-corrected visual acuity after the surgery. Intraocular lenses were well-centered in 39 of 40 eyes (97.25 %). Nine of forty eyes developed mild vitreous hemorrhage which spontaneously resolved without further intervention. No endophthalmitis was reported.*

\*We have no conflicts of interest about any instruments.

\*Department of Ophthalmology, Faculty of Medicine, Chulalongkorn University

**Conclusion** : *This modified technique is an alternative procedure for scleral sutured posterior chamber intraocular lens implantation. The technique appears to be safe with well-centered IOL and satisfactory final visual results.*

**Keywords** : *Scleral sutured IOL, Technique.*

Reprint request: Laksanaphuk P. Department of Ophthalmology, Faculty of Medicine,  
Chulalongkorn University, Bangkok 10330, Thailand.

Received for publication. June 20, 2007.

ประกาศนียบัตร ฤกษ์พุก, พิรุณรัตน์ เจียรักสุวรรณ, สิริชัย ปาสาทิก้า. เทคนิคการผ่าตัดแขวนเลนส์ตาเทียมโดยใช้ไหมคู่และไม่สร้างสเคลอรัลแฟลปที่โรงพยาบาลจุฬาลงกรณ์ ตั้งแต่ พ.ศ. 2538-2546. จุฬาลงกรณ์เวชสาร 2550 พ.ศ. - มิ.ย; 51(5): 255 - 62

- วัตถุประสงค์** : นำเสนอเทคนิคการผ่าตัดแขวนเลนส์ตาเทียมโดยใช้ไหมคู่ ไม่สร้างสเคลอรัลแฟลป และประเมินผลการผ่าตัดตลอดจนภาวะแทรกซ้อน
- สถานที่ทำการศึกษา** : โรงพยาบาลจุฬาลงกรณ์
- รูปแบบการวิจัย** : การศึกษาแบบย้อนหลังเชิงพรรณนา ไม่มีกลุ่มเปรียบเทียบ
- วิธีการศึกษา** : ทำการศึกษาเฉพาะผู้ป่วยที่เข้ารับการผ่าตัดแขวนเลนส์ตาเทียมด้วยเทคนิคนี้ โดยเปรียบเทียบค่าสายตาที่ดีที่สุด (Best corrected visual acuity, BCVA) ก่อนและหลังผ่าตัด และประเมินตำแหน่งเลนส์ตาเทียมตลอดจนภาวะแทรกซ้อนหลังการผ่าตัด
- ผลการศึกษา** : ผู้ป่วย 39 คน (40 ตา) อายุเฉลี่ย 55 ปี มี BCVA ที่ดีขึ้น 36 ตา (90 %) : เลนส์ตาเทียมอยู่ในตำแหน่งตรงกลาง 39 ตา (97.25 %) มีเลือดออกในวุ้นตา 9 ตา ซึ่งสามารถหายได้เองโดยไม่ต้องเข้ารับการผ่าตัดซ้ำ และไม่พบการติดเชื้อหลังการผ่าตัด
- วิจารณ์และสรุป** : เทคนิคการผ่าตัดแขวนเลนส์ตาเทียมแบบนี้เป็นอีกหนึ่งทางเลือกที่มีความปลอดภัย เลนส์ตามีตำแหน่งที่มั่นคงและให้ผลการมองเห็นที่ดี
- คำสำคัญ** : การผ่าตัดแขวนเลนส์ตาเทียม, เทคนิค

Intraocular lens (IOL) implantation is the treatment of choice for aphakic correction. In the absence of capsular support, anterior chamber IOL, iris sutured IOL and transscleral sutured IOL implantation are the options of treatment. Anterior chamber IOL implantation may lead to corneal decompensation, uveitis and secondary glaucoma from trabecular meshwork damage, even though it can reduce operative time. Iris sutured IOL implantation can cause anterior uveitis and intraoperative hemorrhage. Transscleral sutured IOL implantation is a way to place IOL closely to natural crystalline lens and safety for corneal endothelium. However, it can be associated with complications such as vitreous hemorrhage, choroidal hemorrhage, retinal detachment, cystoid macular edema and suture exposure.

There are various techniques of transscleral sutured IOL implantation including how to introduce suturing needles (*ab externo* or *ab interno* technique), incision type (scleral tunnel incision or limbal incision), how to secure the haptic with fixing suture, the number of points of posterior chamber IOL fixation, and the technique to avoid suture/knot erosion. Each technique requires various specific supplemental surgical instruments.<sup>(1)</sup>

The purpose of this study is to describe a surgical technique for transscleral sutured posterior chamber IOL (double suture without scleral flap), and to evaluate surgical results and complications.

## Method

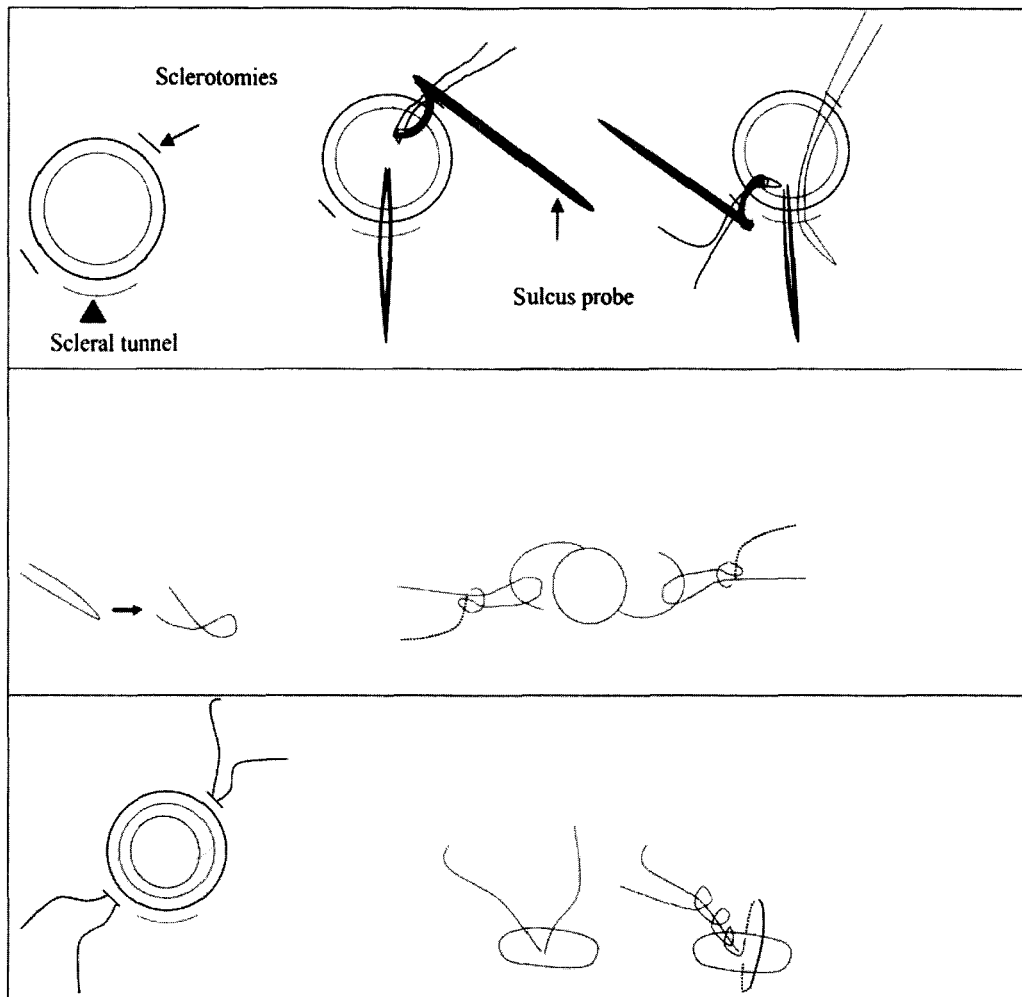
Medical records of patients who received transscleral sutured posterior chamber IOL implantation between January 1995 and December

2003 at King Chulalongkorn Memorial Hospital by Dr. Prasart Laksanaphuk were reviewed. Permission for review medical records was approved by the Ethics Committee, Faculty of Medicine, Chulalongkorn University. Data collections included demographic data (age, sex), indications for surgery, pre- and post-operative visual acuities (until the latest follow up), IOL position (evaluated by slit lamp biomicroscope), complications and the need of further operation.

## Surgical technique (Figure 1)

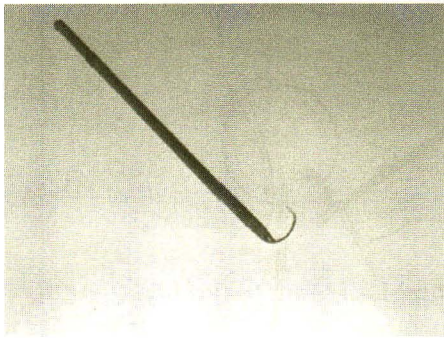
1. Conjunctival peritomy was done.
2. Scleral tunnel incision was created in 7 mm at 12 o'clock.
3. Sclerotomies were made using Microvitreoretinal (MVR) blade at 2 and 8 o'clock.
4. Suture was inserted (Mersilene 10/0) via sclerostomies using special eyed needle and Mcpherson forceps through scleral tunnel. IOL was secured by tying of double suture.
5. IOL was inserted into the ciliary sulcus and the suture was gently pulled to adjust for the proper position of IOL.
6. Scleral suture was done and knots were buried under scleral groove at the same time.
7. Superior scleral tunnel wound was closed using nylon 10/0.
8. Conjunctival peritomy was closed.

This technique was modified by Dr. Prasart Laksanaphuk. However, special eyed needle was first invented by Dr. Chaiyen Ratnavijairn. It was called "sulcus probe" for sulcus implantation IOL with or without capsule. It composed of eyed-round curve needle attached to special needle holder. (Figure 2, 3)




**Figure 1.** Surgical technique.

1. After conjunctival peritomy was done, scleral tunnel incision was created in 7 mm at 12 o'clock and sclerotomies were made using Microvitrectoretinal (MVR) blade at 2 and 8 o'clock, 1 mm. from limbus
2. Suture was inserted (Mersilene 10/0) via sclerostomies using special eyed needle and Mcpherson forceps through scleral tunnel.
3. IOL was secured by tying of double suture using slip knot or clove hitch.
4. IOL was inserted into the ciliary sulcus and the suture was gently pulled to adjust for the proper position of IOL.
5. Scleral suture was done and knots were buried under scleral groove at the same time.



**Figure 2.** Sulcus probe.



**Figure 3.** Head tip of sulcus probe is similar to eyed-round curve needle for bridle suture.

### Statistical analysis

#### Descriptive analysis

### Result

There were fifty-two eyes of 51 patients who underwent transcleral sutured posterior chamber intraocular lens implantation from January 1995 to December 2003. Medical records were obtained from 41 patients. Medical records of 10 patients were missing. There were 31 men and 10 women with a mean age of 55 years old. The range of follow up period was from 1 week to 6 years. One patient was lost to follow up after operation.

Pre- and post-operative best corrected visual acuity was compared. Pre-operative visual acuity was less than 20/200 in 29 patients (70.7 %), 20/70 to 20/

**Table1.** Patients divided by preoperative diagnosis.

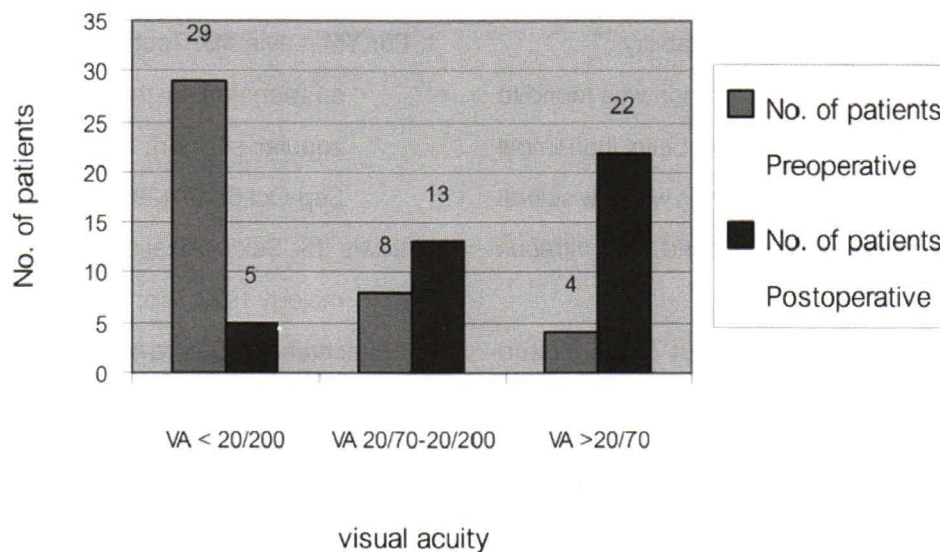
Diagnosis	No. of patient
Post couching	2
Spontaneous lens dislocation	9
Spontaneous IOL dislocation	9
Traumatic lens dislocation	9
Ruptured PC	11
Aphakia (post lens aspiration)	1

200 in 8 patients (19.5 %), and 20/70 or better in 4 patients (9.75 %). Post-operative visual acuity was less than 20/200 in 5 patients (12.5 %), 20/70 to 20/200 in 13 patients (32.5 %), and 20/70 or better in 22 patients (55 %). (Figure 4.) Thirty-six eyes (90 %) had improved best-corrected visual acuity (BCVA) after surgery. One eye had no difference of BCVA. Three eyes had decreased BCVA; one of these three was caused by multiple surgeries and consequently bullous keratopathy; one developed traumatic phthisis bulbi; and the other one had total retinal detachment and cystoid macular edema.

Intraocular lenses were well-centered in all cases at 1 month postoperatively. IOL decentration in 1 eye was found six months later, during the follow up period.

There was vitreous hemorrhage in 9 eyes (22.5 %), glaucoma in 4 eyes (10 %), retinal detachment in 2 eyes (5 %), cystoid macular edema in 3 eyes (7.5 %), epimacular membrane in 1 eye (2.5 %), prolapsed iris at wound in 1 eye (2.5 %), loose stitch in 1 eye (2.5 %), and suture exposure in 1 eye (2.5 %). Endophthalmitis were not found.

Of the two eyes with retinal detachment, one was fixed by pneumatic cryoretinopexy, and the other underwent multiple surgeries. Final visual acuity was



**Figure 4.** Pre-operative and post-operative visual acuity of patients undergoing transcleral sutured posterior chamber IOLS.

20/40 and hand motion respectively. Epimacular membrane was diagnosed in one eye which was treated by vitrectomy and membrane peeling. Post-operative visual acuity was 20/30.

### Discussion

As for transscleral sutured IOL implantation technique, there are several different steps introduced by ophthalmic surgeons worldwide as follows: the method of introducing suturing needles (*ab externo* or *ab interno*), the method of entering IOL (scleral tunnel incision or limbal incision), the method of securing the haptic with fixing suture, the number of points of posterior chamber IOL fixation and the method of avoiding suture/knot erosion. There were various assisted instruments used by different techniques.<sup>(1)</sup>

In this study, we found that our technique produced high IOL centration rate. There were 9 eyes with mild vitreous hemorrhage which resolved

spontaneously without further intervention. It may be from anatomical variation of blood vessels that we cannot see when sclerotomies were done. No endophthalmitis was reported. We found suture exposure in one eye after one year of follow up.

Suture exposure may be avoided by creating scleral flap to cover suture sites; still the rate of suture erosion was found as high as 20 % in one report.<sup>(2)</sup> Undoubtedly, suture exposure can lead to endophthalmitis.<sup>(3)</sup> Some surgeons prefer to create scleral groove and bury the knot underneath, this technique can help reduce operating time. However, there are still some risks of suture exposure.<sup>(4)</sup>

In our study, double suture with needles penetrated via sclerotomies. We can secure IOL by suturing to close sclerotomies, and also to adjust the proper position of IOL. The knots can be buried into sclerostomies.

Chang-Ping Lin *et al.* described transscleral sutured IOL technique without scleral flap. The knot

was buried in the scleral groove and 4-point fixation of IOL was made to increase IOL stability.<sup>(5)</sup>

Superior scleral tunnel incision was found to help maintain anterior chamber depth better than limbal corneal incision especially in the eyes with low scleral rigidity, small palpebral fissures, and high vitreous pressure.<sup>(6,7)</sup>

There were studies about the assisted instruments to facilitate the procedure and decrease the step of the operation. Vaipayee *et al.* described the use of a special needle holder to place the suture precisely into the ciliary sulcus.<sup>(8)</sup> Pannu *et al.* presented a special needle that does not require any needle holder which is easy to use in any quadrant even in a deeply sunken eye.<sup>(9)</sup> The intraocular exit points of the needle were unseen so the accurate suture placement was decreased. We present a special needle that is a curved needle which does not require the holder and suture by *ab externo* (outside-in) approach. (Figure 2, 3) This technique can be modified by using eyed-round curve needle for bridle suture, Mersilene 10/0 instead of special needle holder and propylene 10/0, respectively.

Retrospectively, this study had limitations including variable lengths of follow up periods, varieties of preoperative diagnosis, incomplete data and missing medical records. In our hospital, medical records were automatically discarded if patients do not show up again longer than 5 years.

In conclusion, we found that this modified technique is an alternative for scleral sutured posterior chamber intraocular lens implantation. This technique appears to be safe with high IOL centration rate and satisfactory final visual results.

## References

1. Por YM, Lavin MJ. Techniques of intraocular lens suspension in the absence of capsular/zonular support. *Survey Ophthalmol* 2005 Sep-Oct;50(5):429-62
2. Lewis JS. Sulcus fixation without flaps. *Ophthalmology* 1993 Sep;100(9):1346-50
3. Schechter RJ. Suture-wick endophthalmitis with sutured posterior chamber intraocular lenses. *J Cataract Refract Surg* 1990 Nov;16(6):755-6
4. Mittelviehhaus H, Wiek J. A refined technique of transscleral suture fixation posterior chamber lenses developed for cases of complicated cataract surgery with vitreous loss. *Ophthalmic Surgery* 1993 Oct;24(10):698-701
5. Lin CP, Tseng HY. Suture fixation technique for posterior chamber intraocular lenses. *J Cataract Refract Surg* 2004 Jul;30(7):1401-4
6. Young AL, Leung GY, Cheng LL, Lam DS. A modified technique of scleral fixated intraocular lenses for aphakic correction. *Eye* 2005 Jan;19(1):19-22
7. Schmidt JC, Nietgen GW, Freisberg L, Neisskenwirth NN. Modified transscleral suture for sulcus fixation of posterior chamber lenses. *J Cataract Refract Surg* 2002 Jan;28(1):15-7
8. Vajpayee RB, Angra SK, Sandramouli S, Rewari R. Direct scleral fixation of posterior chamber intraocular lenses using a special needle-holder. *Ophthalmic Surgery* 1992 Jun;23(6):383-7
9. Pannu JS. A new suture technique for ciliary sulcus fixation in the absence of posterior capsule. *Ophthalmic Surgery* 1988 Oct;19(10):751-4