

Original article

Surgical aspects of adrenal tumors in children

Sirima Liukitithara^{a,b}, Paisarn Vejchapipat^{a,*}, Katawaetee Decharun^a, Apirak Santingamkun^a

^aDepartment of Surgery, Faculty of Medicine, Chulalongkorn University and King Chulalongkorn Memorial Hospital, Bangkok, Thailand

^bDepartment of Surgery, Medical Education Center Hatyai Hospital, Songkhla, Thailand 90110

Background: Adrenal tumors are uncommon in children. They can be divided into 2 categories, namely: adrenomedullary tumor and adrenocortical tumor. Surgical aspects of these conditions receive little attention.

Objective: The objective of this study was to describe clinical data, operative findings, and operative complications in children with adrenal tumors.

Methods: Patients, aged 0 - 15 years, undergoing adrenalectomy between January 2007 and December 2016 were retrospectively reviewed.

Results: Thirty-seven patients underwent adrenalectomies. Male to female ratio was 1.31 to 1. Median age of the patients was 44 months (range, 2 months-14 years). Pathological examination revealed 27 adrenomedullary tumors (19 neuroblastomas, 5 ganglioneuroblastomas, 2 ganglioneuromas, and 1 pheochromocytoma) and 10 adrenocortical tumors (8 adrenocortical carcinomas, 1 adrenocortical adenoma, and 1 micronodular adrenal hyperplasia). Most patients (35/37) underwent open adrenalectomies.

As for neuroblastomas, most patients were in stage IV. Two ganglioneuromas and one ganglioneuroblastoma were diagnosed and treated as neuroblastoma before adrenalectomy. Pre-operative median tumor-size was 6.3 cm. In neuroblastic cases, complete resection could be achieved in 54.0% (14/26). Post-operative complications were reported in 19.0% (5/26) including chylous ascites, pancreatitis, and sepsis.

As for adrenocortical tumors, all were functioning. Cushing syndrome (70.0%) is the most common presentation followed by precocious puberty (60.0%). Only one adrenocortical carcinoma patient presented with adrenal mass and lung metastasis. Most adrenocortical tumors exhibited hypervascularity. Median tumor-size was 6.3 cm (range 0.4 to 23 cm). Tumor with local invasion was found in 2 cases. No peri-operative complication was reported.

Conclusions: As for adrenomedullary tumors, neuroblastoma stage IV is the main indication for surgery in our series. This implies either delayed diagnosis or delayed medical attention. For adrenocortical tumors, surgical resection could be safely performed without significant morbidity.

Keywords: Adrenalectomy, adrenal tumors, children.

Adrenal tumors are uncommon in children. They can be divided into 2 categories, namely: adrenomedullary tumor (neuroblastoma, ganglioneuroblastomas, ganglioneuromas, etc.) and adrenocortical tumor (adrenocortical adenoma, carcinoma, etc.). Although neuroblastoma is a common solid abdominal tumor in children, adrenocortical tumor is a rare tumor. Its clinical symptoms varied such as asymptomatic palpable mass, metastatic symptoms and hormonal functioning symptoms. They sometimes resulted in late

presentation. Surgical resection is known as a main treatment for adrenocortical tumor^(1,2) and as a part of multimodality therapy for neuroblastoma.⁽³⁾ Clinical data and overall results of adrenalectomy in children have been rarely reported. The objective of this study was to review surgical aspects of children who underwent adrenalectomy at our institution within 10 years.

Materials and methods

The study was approved by Institution Review Board (IRB) of our institution (IRB no. 103/60). All patients (age 0 -15 years) undergoing adrenalectomy between January 2007 and December 2016 were retrospectively reviewed. Patient demographics, clinical symptoms, pre-operative imaging, operative details, tumor pathology, post-operative complication,

*Correspondence to: Paisarn Vejchapipat, Department of Surgery, Faculty of Medicine, Chulalongkorn University and King Chulalongkorn Memorial Hospital, Bangkok, Thailand
E-mail: paisarnv@gmail.com

Received: April 14, 2020

Revised: May 8, 2020

Accepted: June 3, 2020

and clinical outcome were recorded. Pre-operative work up data, including bone marrow biopsy/aspiration, bone scan, chest and abdominal CT scan, were collected. Tumor diameter was assessed using pre-operative imaging. In neuroblastoma, pre-operative tissue diagnosis including MYCN amplification status, International Neuroblastoma Pathology Classification (INPC) and the extent of disease is determined by the presence or absence of image-defined risk factors (IDRFs) were reviewed.

We evaluated preoperative staging for neuroblastoma according to International Neuroblastoma Staging System (INSS) ⁽⁴⁾, and Children's Oncology Group (COG) risk group assignment for neuroblastoma. As for adrenocortical carcinoma (ACC), COG staging system was used. The staging system for pediatric ACC has been modified by COG. Pediatric ACC are divided into four groups: stage I - completely resected tumors < 100 g, stage II - completely resected tumors ≥ 100 g, stage III - residual disease or inoperable tumors, and stage IV - distant metastatic disease. ⁽⁵⁾ The complete degree of resection was assessed as recorded by operative notes. Gross total resection (GTR) was defined as no visible or palpable disease at the end of operation. Less than GTR included those patients undergoing no surgery, biopsy

only, partial resection (50.0 – 90.0%), or near-gross total resection (> 90.0% but with palpable or visible tumor remaining). ⁽³⁾

Intra-operative complications, peri-operative complications (within one month after surgery) were reviewed. In addition, post-operative overall survival was calculated from the date of surgery to the date of death of any cause or to the last follow-up date.

Results

Thirty-seven patients underwent adrenalectomies. Male to female ratio was 1.31 to 1. Median age of patients was 44 months (range, 2 months-14 years). Pathological examination revealed 27 adrenomedullary tumors and 10 adrenocortical tumors. As for adrenomedullary tumors, there were 19 neuroblastomas, 5 ganglioneuroblastomas, 2 ganglioneuromas, and 1 pheochromocytoma. For adrenocortical tumors, there were 8 adrenocortical carcinomas, 1 adrenocortical adenoma, and 1 micronodular adrenal hyperplasia. Most patients (35/37) underwent open adrenalectomies. Laparoscopic adrenalectomies were performed in one patient with micronodular adrenal hyperplasia and one patient with adrenocortical carcinoma. The clinical data of all patients were summarized in Table 1.

Table 1. Characteristics of adrenal tumor patients with pathologic results.

	Adrenomedullary tumors (n = 27)	Adrenocortical tumors (n = 10)	Total (n = 37)
Median age at diagnosis (months)	43.5 (2-168)	36.0 (10-144)	44.0 (2-168)
Male: Female	17: 10	4: 6	21: 16
Presentations			
Abdominal distention	15	3	18
Fever	12	0	12
Ataxia	1	0	1
Neck/subcuticular mass	2	0	2
Pain	8	0	8
Pale with fatigue	4	0	4
Cushing syndrome	0	7	7
Precocious puberty	0	6	6
Hypertension	9	9	18
Median tumor size diameter (cm.)	6.5 (3.1–18.0)	6.3 (0.4–23.0)	6.5 (0.4–23.0)
Tumor pathology			
Benign	3	2	5
Malignant	24	8	32
Metastasis at diagnosis	20	2	22

Neuroblastic tumors (26 cases)

There were 19 neuroblastomas, 5 ganglioneuroblastomas, and 2 ganglioneuromas. Male to female ratio was 16:10. Left-sided to right-sided ratio was 13:10. Three patients had large tumors that involved both adrenal glands. Median age of patient was 43.5 months (range, 2 months to 13 years). The most common presenting symptom was abdominal distension (14/26 or 54.0%). Metastatic work up including bone scan, chest computerized tomography (CT) and bone marrow aspirate/biopsy were performed in 96.0% (25/26). One case had no metastatic work up due to the pre-operative diagnosis as benign disease. MYCN amplification status had been reported in only 6 cases with result that three had MYCN amplification >10 copies. Pre-operative tissue diagnoses were achieved in 58.0% (15/26). Median tumor size was 6.3 cm (range, 3.1 to 18.0 cm).

Seventy-three percent of patients with neuroblastoma were in high risk group according to Children's Oncology Group (COG) risk group assignment for neuroblastoma. Moreover, almost all neuroblastoma (18/19) were in stage-4 with bone marrow involvement or bone metastasis. They had been treated with pre-operative chemotherapy (95.0%). One patient with stage 4 neuroblastoma was operated without pre-operative chemotherapy due to misdiagnosis as adrenocortical tumor.

As for ganglioneuroblastomas, 2 patients were in stage 4. Another 2 patients were in stage 3 and the other one was in stage 1. As for ganglioneuroma 1 patient was in stage 3 and the other one was

in stage 1.

Preoperatively, 42.0% (11/26) of the patients had no image-defined risk factors (IDRFs). Gross total resection was achieved in all of these patients. The remaining 15 patients had IDRFs and gross total resection was achieved in only in 3 cases (20.0%). Overall, complete gross resection could be done in 54.0% (14/26), as shown in Figure 1.

Post-operative complications occurred in 19.0% (5/26) including 1 chylous ascites, 1 pancreatitis, and 3 sepsis. All complications were successfully managed without surgical intervention. Median follow-up time was 18 months (range 1 - 80 months). As for neuroblastoma, the 1-year and 3-year survival rates were 84.0% and 47.0%, respectively, as shown in Figure 2.

Adrenocortical tumors (10 cases)

There were 8 adrenocortical carcinomas, 1 adrenocortical adenoma, and 1 micronodular adrenal hyperplasia. Male to female ratio was 4:6. Left-sided to right-sided ratio was 7:3. Median age of patients was 3 years (range, 10 months to 12 years). All were functioning tumors. The most common presentation was weight gain due to Cushing syndrome (70.0%), followed by precocious puberty (60.0%). Bone scan and chest CT scan were evaluated in 80.0% (8/10). Twenty-five percent (2/8) of patients with adrenocortical carcinoma presented with lung metastasis at the time of diagnosis. Median tumor-size was 6.3 cm (range 0.4 to 23.0 cm). Dehydroepiandrosterone sulfate (DHEA-S) was elevated in 75.0% of adrenocortical carcinoma.

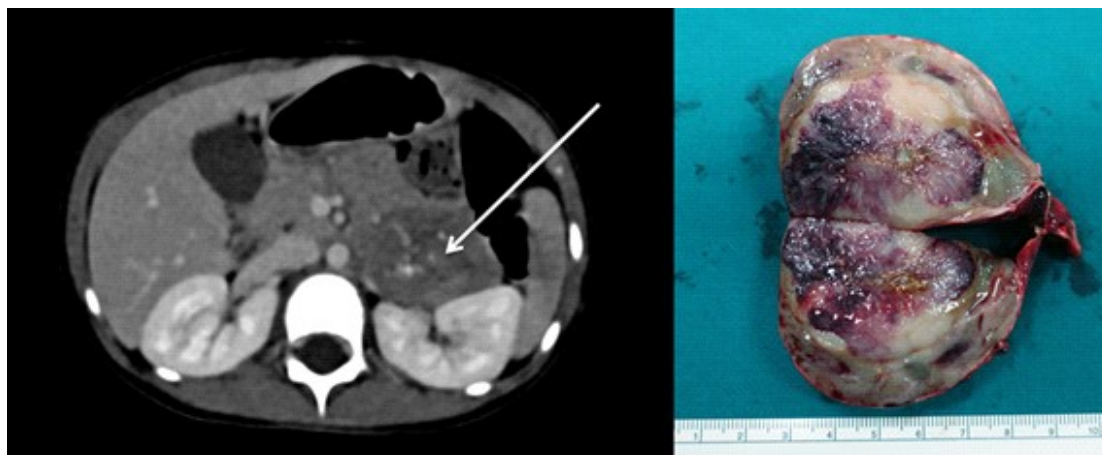


Figure 1. Neuroblastoma (arrow) stage IV and absence of image-defined risk factors with complete gross resection.

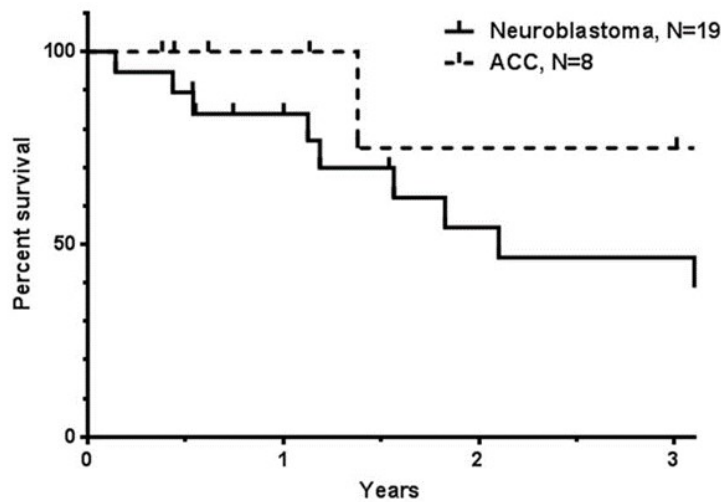


Figure 2. Survival curves of patients with neuroblastoma and patients with adrenocortical carcinoma (ACC).

As for adrenocortical tumors, gross total resection was achieved in 90.0% (9/10), as shown in Figure 3. As for adrenocortical carcinoma, there were 3 patients in stage I, 2 patients in stage II, one patient in stage III, and 2 patients in stage IV. Adjuvant systemic therapy was utilized in 38.0% (3/8) of children who underwent surgical resection. (Stage III and IV). One patient with stage I developed lung metastasis 2 years after first operation despite of gross total resection with negative margin. Systemic therapy was utilized and lung wedge resection was carried out. Genetic study of two patients with adrenocortical carcinoma revealed *TP53* mutations without classic Li-Fraumeni syndrome. Median follow-up time was 17 months (range 5 - 81 months). The 1-year and 3-year survival rates were 100.0% and 75.0%, respectively, as shown in Figure 2.

Discussion

Adrenal tumors in children are divided into adrenomedullary tumors and adrenocortical tumors. Neuroblastoma is the most common adrenomedullary tumors, accounts for 60.0 – 90.0% followed by ganglioneuroblastoma, ganglioneuroma and pheochromocytoma. However, adrenocortical tumors in children are rare. These include adrenocortical adenoma (16.6%), adrenocortical carcinoma (2.1%)⁽⁶⁾ and micronodular adrenal hyperplasia.⁽⁷⁾ In our series, neuroblastoma is the most common adrenal tumor, accounts for 51.0% of all. However, adrenocortical carcinoma were found in higher proportion (22.0%) compared to the other report.⁽⁶⁾ These may be due to pathologically difficult assessment between adrenocortical carcinoma and adenoma. The main clinical presentation of

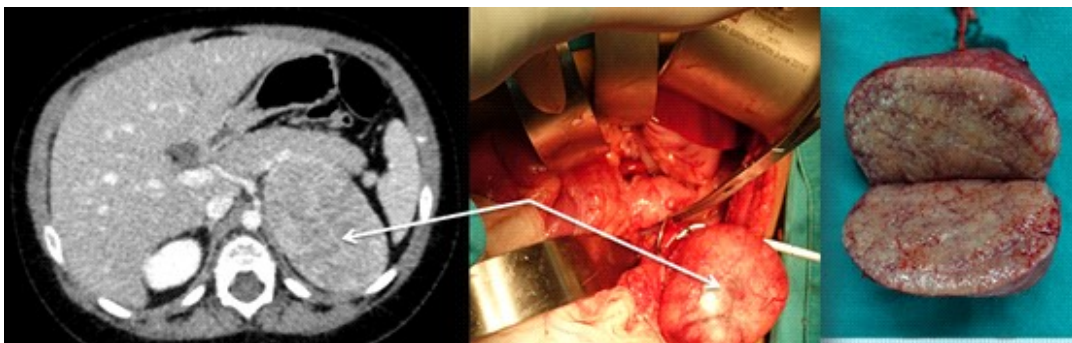


Figure 3. Adreno-cortical carcinoma (arrow) stage 1 with complete gross resection.

neuroblastoma is pain from metastatic disease⁽⁶⁾ whereas Cushing syndrome⁽⁶⁾ or virilization^(1,8) is the most presenting symptom of adrenocortical tumors both benign and malignant.

Neuroblastic tumors

Neuroblastoma is the most common extra-cranial solid tumor in childhood. The incidence is about 10.54 cases per 1 million per year in children younger than 15 years.⁽⁹⁾

In our series, abdominal distention/mass is the main symptom of neuroblastoma that brought children to the hospital. Onset of presentation was approximately one year with almost all patients in stage 4 at diagnosis.

According to Children's Oncology Group (COG)⁽⁹⁾, neuroblastoma patients are currently stratified into low, intermediate, and high-risk groups based on age at diagnosis (< 365 days, 365 - 548 days or < 548 days), International Neuroblastoma Staging System (INSS) stage (1, 2, 3, 4, 4s), MYCN status (amplification or non-amplified), International Neuroblastoma Pathologic Classification (INPC) (favorable or unfavorable), and tumor cell ploidy (DNA index = 1.0 or > 1.0). In addition, presence or absence of image-defined risk factors (IDRFs) is used as an assignment of therapy and predicts outcome. In our series, not all suspected neuroblastoma patients got fully metastatic work up for stratified into COG risk group. For example, when case of positive distant metastasis or bone marrow involvement was identified, if patient age was more than one and a half years old, these would be treated as high risk group. INPC might not be identified at all. Some patients were referred to our center just for surgery, so some data were missing. Almost all our neuroblastoma patients (95.0%) were presented in stage 4 disease, even including ganglioneuroblastoma and ganglioneuroma, the patients in stage 4 disease were still accounting for 77.0%.

Gross total resection for neuroblastic tumors, in our report, could be achieved in 54.0%. Regardless of systemic and other therapy, the benefit of gross total resection for high-risk neuroblastoma remains controversial. Englum BR, *et al*⁽³⁾, concluded that gross total resection in high-risk neuroblastoma patients is not associated with improved overall survival compared to incomplete resection. Nevertheless, these results suggest that > 90.0% resection is associated with improved overall survival compared to less than

90.0% resection. Therefore, in high risk neuroblastoma patients, surgery is still a part of multimodality therapy, gross total resection might be an ultimate goal for high-risk neuroblastoma, but > 90.0% resection should be attempted. As for high risk group neuroblastoma, the 5-year survival rates were 35.0 – 47.0%.^(3,10) In our series, the 3-year survival rates were 47.0%, which is consistent with other reports.

Adrenocortical tumors

The overall age-adjusted annual incidence for adrenocortical carcinoma was 0.72 per million in the United States.⁽²⁾ Cushing syndrome is the most common presenting symptom of adrenocortical tumors. Most patients had significant arterial hypertension. All adrenocortical tumors in this report were functioning tumor. Median tumor-size was 6.3 cm (range 0.4 to 23 cm), which was smaller compared to 11 - 12 cm^(2,10) in adult studies. Sabbaga CC, *et al*.⁽¹⁾ demonstrated that the survival rate was influenced by duration of symptoms. When symptoms had been present for less than 6 months, the survival was 70.0%, compared with 9.0%, when symptoms with more than 6 months.

Adrenocortical carcinoma staging in adults typically follows either the American Joint Committee on Cancer, known as TNM staging system, or a modified staging system proposed by the European Network for The Study of Adrenal Tumors (ENSAT).^(10,11) These staging systems have not been extended to children. Instead, the staging system for pediatric adrenocortical carcinoma has been modified by the Children's Oncology Group (COG). According to the COG staging system, pediatric adrenocortical carcinoma are divided into four groups based on complete degree of resection, tumor size and metastasis at diagnosis.⁽⁵⁾

The prognosis of adrenocortical carcinoma in adult was very poor, 2- and 5- year overall survival rate 64 and 40.0%.⁽¹⁰⁾ Interestingly, the study in pediatric population showed better prognosis, overall 1- and 3-year survival was 70.0% and 64.0%⁽¹²⁾, especially very young patients (< 2 years old), overall survival is 83.0%.⁽¹⁾ This is consistent with our series (1- and 3- year survival was 100.0% and 75.0%, respectively). Still, the prognosis of adrenocortical carcinoma is strongly related to completeness of surgical resection^(1, 2, 10) and size of tumor.⁽¹²⁾ Adjuvant systemic therapy has been used in post-operative residual disease or distant metastasis⁽⁵⁾, but the

outcome still unsatisfactory. Gross total resection with negative margin should be aimed at initial management. Adjuvant systemic therapy showed some benefits and long term monitor for recurrence disease is important.

Roughly 50.0% of very early onset ACCs occurs in children with germ-line *TP53* mutations.⁽¹³⁾ In our reviewed, genetic study in ACCs were done only 2 patients and positive for *TP53* mutations.

Surgical choices for adrenalectomy, laparoscopy versus laparotomy, remains controversial. Many studies showed laparoscopic adrenalectomy in children was safe and had equal outcome compared to laparotomy in highly selective patients.⁽¹⁴⁾ However, adrenal tumors, especially neuroblastoma and adrenocortical carcinoma, usually have local adherence to surrounding organs and were large tumor size. Negative resected margin for adrenocortical tumor is strongly related to satisfactory outcome. Therefore, laparoscopic adrenalectomy could be performed just only in highly selected patient with small tumor size. In our series, two cases were performed by laparoscopy. Pathological report revealed one micronodular adrenal hyperplasia and one adrenocortical carcinoma. Tumor size is 0.4 and 2.0 cm, respectively.

We conclude that, for adrenomedullary tumors, neuroblastoma stage IV is the main indication for surgery in our series. This implies either delayed diagnosis or delayed medical attention. AS for adrenocortical tumors, surgical resection could be safely performed without significant morbidity.

Conflict of interest

The authors declares that there is no conflict of interest.

References

1. Sabbaga CC, Avilla SG, Schulz C, Garbers JC, Blucher D. Adrenocortical carcinoma in children: clinical aspects and prognosis. *J Pediatr Surg* 1993;28:841-3.
2. Kebebew E, Reiff E, Duh QY, Clark OH, McMillan A. Extent of disease at presentation and outcome for adrenocortical carcinoma: have we made progress? *World J Surg* 2006;30:872-8.
3. Englum BR, Rialon KL, Speicher PJ, Gulack B, Driscoll TA, Kreissman SG, et al. Value of surgical resection in children with high-risk neuroblastoma. *Pediatr Blood Cancer* 2015;62:1529-35.
4. Castel V, Garcia-Miguel P, Canete A, Melero C, Navajas A, Ruiz-Jimenez JJ, et al. Prospective evaluation of the International Neuroblastoma Staging System (INSS) and the International Neuroblastoma Response Criteria (INRC) in a multicentre setting. *Eur J Cancer* 1999;35:606-11.
5. ARAR0332: Treatment of adrenocortical tumors with surgery plus lymph node dissection and multiagent chemotherapy [Internet]. 2006 [cited 2017 Jan 4]. Available from: <https://www.childrensoncologygroup.org/arar0332>.
6. Lin X, Wu D, Chen C, Zheng N. Clinical characteristics of adrenal tumors in children: a retrospective review of a 15-year single-center experience. *Int Urol Nephrol* 2017;49:381-5.
7. Powell AC, Stratakis CA, Patronas NJ, Steinberg SM, Batista D, Alexander HR, et al. Operative management of Cushing syndrome secondary to micronodular adrenal hyperplasia. *Surgery* 2008;143:750-8.
8. Gonc EN, Ozon ZA, Cakir MD, Alikasifoglu A, Kandemir N. Need for comprehensive hormonal workup in the management of adrenocortical tumors in children. *J Clin Res Pediatr Endocrinol* 2014;6:68-73.
9. Neuroblastoma treatment (PDQ®)—health professional version [Internet]. 2017 [cited 2017 Jan 4]. Available from: <https://www.cancer.gov/types/neuroblastoma/hp/neuroblastoma-treatment-pdq>.
10. Calissendorff J, Calissendorff F, Falhammar H. Adrenocortical cancer: mortality, hormone secretion, proliferation and urine steroids - experience from a single centre spanning three decades. *BMC Endocr Disord* 2016;16:15.
11. Lughezzani G, Sun M, Perrotte P, Jeldres C, Alasker A, Isbarn H, et al. The European Network for the Study of Adrenal Tumors staging system is prognostically superior to the international union against cancer-staging system: A North American validation. *Eur J Cancer* 2010;46:713-9.
12. Gulack BC, Rialon KL, Englum BR, Kim J, Talbot LJ, Adibe OO, et al. Factors associated with survival in pediatric adrenocortical carcinoma: An analysis of the National Cancer Data Base (NCDB). *J Pediatr Surg* 2016;51:172-7.
13. Else T, Rodriguez-Galindo C. 5th International ACC symposium: hereditary predisposition to childhood ACC and the associated molecular phenotype: 5th International ACC symposium session: Not just for kids! *Horm Cancer* 2016;7:36-9.
14. Lopes RI, Denes FT, Bissoli J, Mendonca BB, Srougi M. Laparoscopic adrenalectomy in children. *J Pediatr Urol* 2012;8:379-85.