

CLINICAL USES OF VENTRICULAR, CISTERNAL AND SPINAL SCINTIGRAPHY

Charas Suwanwela, M.D.

Vichai Poshyachinda, M.D.

Makumkrong Poshyachinda, M.D.

Visualization of the cerebrospinal fluid spaces and studies of the flow of cerebrospinal fluid with radioisotopes have proved valuable in the diagnosis of many neurological conditions. In 1954, Sweet et al⁽¹¹⁾ reported the use of radioisotope in the study of formation, flow and absorption of the cerebrospinal fluid. The evidences indicated that whereas small molecules and ions such as water and electrolytes are exchanged between the cerebrospinal fluid and the systemic circulation at a very high rate, the disappearance of protein from the lateral ventricles is primarily dependent upon a relatively slow through the classical pathway to the site of absorption. Bauer and Yuhl⁽¹⁾ in 1953 and Perryman et al⁽⁹⁾ in 1958 reported the feasibility of radioisotopic myelography by means of ¹³¹I. The distribution of radioactivity after intrathecal injection of ¹³¹I was demonstrated by external scintillation scanning. Rieselbach et al⁽⁹⁰⁾ in 1962 showed that rose bengal ¹³¹I injected intrathecally in monkeys outlined the subarachnoid pathways of the brain. Scintigraphy of the cerebrospinal fluid space has since been extensively used in patients with various conditions. The evidences which have accumulated over the last 15 years have proved the reliability of this method in the evaluation of hydro-

cephalus especially in differentiating between communicating and non-communicating one, in demonstration of subarachnoid blockage, in detection of leakage of cerebrospinal fluid from the nose or ear, and in determining the patency of cerebrospinal fluid shunts.

Material and method.

At the chulalongkorn Hospital Medical School, Bangkok, scintillation scanning of the cerebrospinal fluid space was first used in July, 1968. It has since been used in 48 patients.

The present communication is a report on the usefulness of this method in this group of patients. Radioactive iodinated human serumalbumin (¹³¹I-RISA) has been our tracer of choice. It is injected intrathecally or intraventricularly. The amount injected is 5-15 μ Ci in less than 1.0 millilitre. The syringe is flushed a few times with the patients cerebrospinal fluid. Serial photoscanning of the spine and head are made at 1, 3 to 6, 24 and 48 hours after the injection. Depending on the clinical findings and the result of the early scans, some intervals may be skipped or more scans may be made at closer interval. When suitable, specimens of cerebrospinal fluid, blood, nasal and aural discharge are collected and the measured radioactive content is compared.

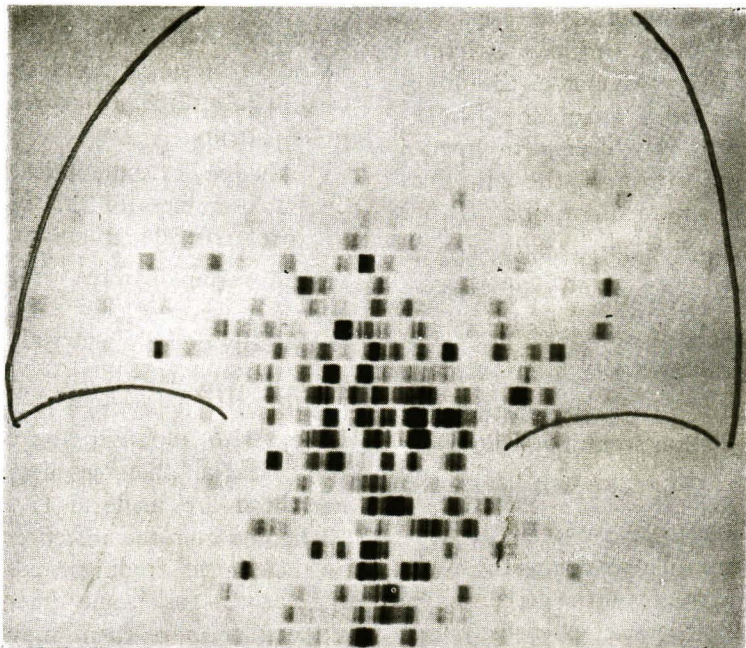
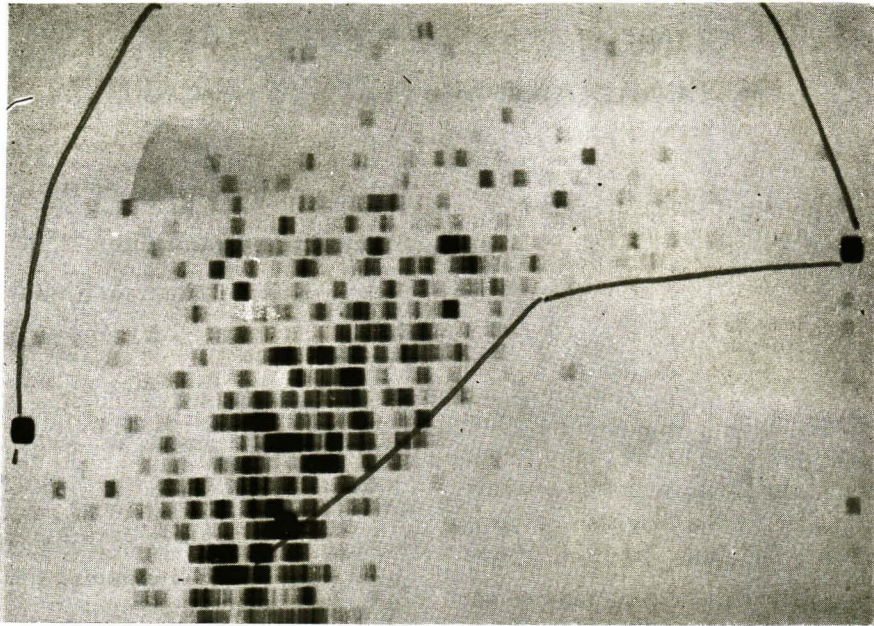


Figure 1. a and b. Normal cisternal scintigram made 3 hours after intrathecal injection of ^{131}I - RISA; a. lateral projection with markers at nasion, mastoid process and external occipital protuberance, b. anteroposterior projection with marker at nasion. The radioactivity is shown in the basal cistern.

The diagnosis of the patients are further verified by neuroradiological and operative findings. Table 1 indicates the various conditions included in this study.

Results

After intrathecal injection the tracer can be followed up the spinal canal to the basal cistern and cortical subarachnoid space. In a normal adult, the radioactivity is detectable in the spinal canal and none in the cranium at 1 hour after injection. The basal cistern is shown in the scan made 3 hours after injection (Figure 1.) At 24 hours, the radioactivity has largely disappeared but some is present over the convexity of the brain near the sagittal sinus. In children the flow is faster than in the adult. The ^{131}I -RISA usually reaches the basal cistern within 1 to 2 hours.

A Hydrocephalus

Twenty-nine patients with hydrocephalus were studied. The test was found to be useful in many aspects. (Table 2)

1. Study of C.S.F. flow and absorption after intrathecal injection.

Among 20 hydrocephalic patients studied after lumbar injection, the normal pattern of flow as described above was seen in 7 patients, 6 of whom were associated with tuberculous meningitis and 1 with congenital communicating hydrocephalus.

Complete obstruction of the basal cistern with no entry of ^{131}I -RISA even after 24 hours was seen in 2 patients, one of whom was from tuberculous meningitis while the other had diffused arachnoid adhesion secondary to cisternal cisticercosis proven at autopsy.

A specific pattern is recognized in 8 patients who had hydrocephalus in association with tuberculous meningitis. The radioisotope entered the basal cistern at 1 hour after injection and remained in high concentration over a wide area on the surface of the brain 4 to 24 hours after the injection. We believe that this finding is indicative of interference of C.S.F. flow in the cortical and basal subarachnoid space as well as its absorption. It is called a delayed absorption pattern.

Case illustration 1. An 11 year-old boy was admitted because of headache, vomiting and drowsiness for 2 months. Dimness of vision in both eyes was also noted. Papilledema was found on admission. Investigations including ventriculography showed a communicating hydrocephalus. The ventricular fluid contained 70 lymphocytes per cubic millilitre with low sugar. The first scintigraphic study was done and revealed a delayed absorption pattern (Figure 2). He was treated with isonicotinic hydrazide, paraaminosalicylic acid, streptomycin and prednisolone with some improvement. In spite of the medication, the headache reappeared at times and he became blind. Exploration of the optic nerve and anterior third ventriculotomy was done. Arachnoid thickening was found and microscopic examination revealed chronic inflammation with lymphocytic infiltration. The patient did not improve after the operation and the frontal operative area bulged. A second C.S.F. scintigraphic study was made 4 months after the first one and was unchanged. Resistant tuberculous infection was suspected, and kanamycin and ethambutol were given. His symptoms improved dramatically and the decompression became soft and sunken. The third C.S.F. scintigraphic study was made 1 month after the initiati-

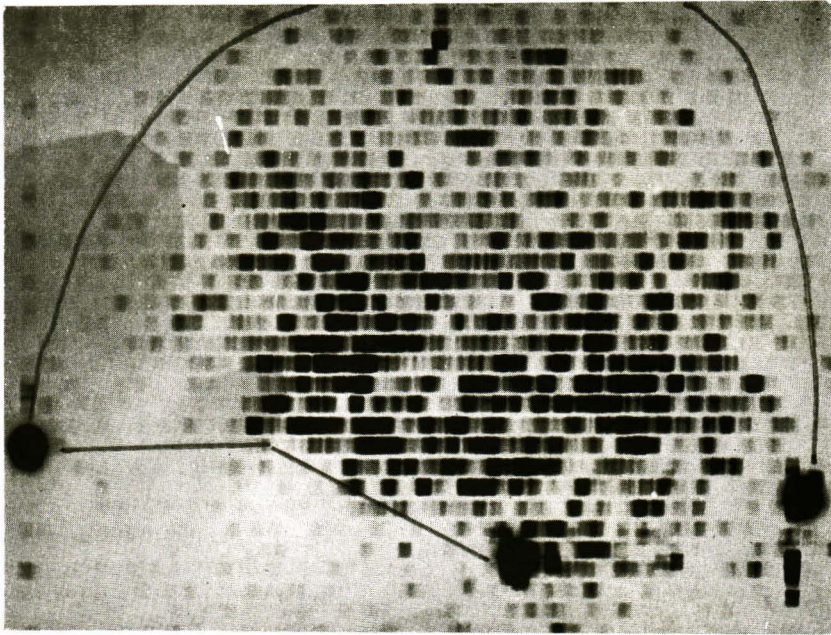


Figure 2. Lateral scintigram showing delayed absorption pattern. It was done 4 hours after intrathecal injection of ^{131}I -RISA. Note the irregular areas of high radioactivity over the surface of the brain. Scintigram done at 24 hours after injection in this patient remained essentially unchanged except for the lower concentration.

Table 1 indicates the various conditions studied by radioisotopic scan of the cerebrospinal fluid space.

Hydrocephalus	
– associated with meningitis	15
– congenital and obstructive	8
– postoperative	3
– associated with myelomeningocele	1
Encephalomeningocele	12*
Rhinorrhoea	2
Spinal cord tumor	1
Intracranial hematoma	2
Normal	<u>4</u>
	48

(* one patient has associated hydrocephalus).

Table 2 shows the result of studies in patients with hydrocephalus.

1. Study of flow and absorption after intrathecal injection	
a. normal pattern	7
b. delayed absorption pattern	8
c. complete obliteration of basal cistern	2
d. postoperative hydrocephalus	3
2. Study of flow after intraventricular injection.	
a. blockage of foramen of Monro	2
b. blockage of aqueduct	1*
c. communicating hydrocephalus	3
d. detection of patency of shunt	2*
3. Combined intrathecal and intraventricular injections.	
a. postoperative hydrocephalus	1
(* one patient had both blockage of aqueduct and obstructed shunt.)	

on of new medications and was in the normal pattern.

This delayed absorption pattern, in our opinion, is therefore not due to fibrous arachnoid adhesion and irreversible. Active infection with interference of flow and absorption is the most likely explanation.

Three patients with postoperative hydrocephalus were studied. All had bulging of the scalp over the cranial defect at the operative site. One patient showed normal pattern with patency of the subarachnoid space and no entry of ¹³¹I-RISA into the bulging. An internal hydrocephalus was later confirmed. The other two patients had delayed absorption pattern with cystic collection of the isotope at the operative site (Figure 3). Subarachnoid-peritoneal shunt in both patients resulted in disappearance of the bulging.

2. Study of C.S.F. flow after intraventricular injection.

In 7 patients, intraventricular injection of ¹³¹I-RISA was performed. After equilibration, scintigraphy was done to outline the ventricular system.

Localization of the radioisotope in one lateral ventricle (Figure 4.) was seen in 2 patients who were proven later with air study to have obstruction at the foramen of Monro from a third ventricular mass and from brain distortion in association with fronto-ethmoidal encephalo-meningocele. This finding is therefore helpful in the diagnosis.

Filling of both lateral ventricles as well as third and fourth ventricles was seen in 2 patients proven to have communicating hydrocephalus (Figure 5). In one patient with aqueductal obstruction, visualization of both lateral ventricles and third ventricle with of the absence

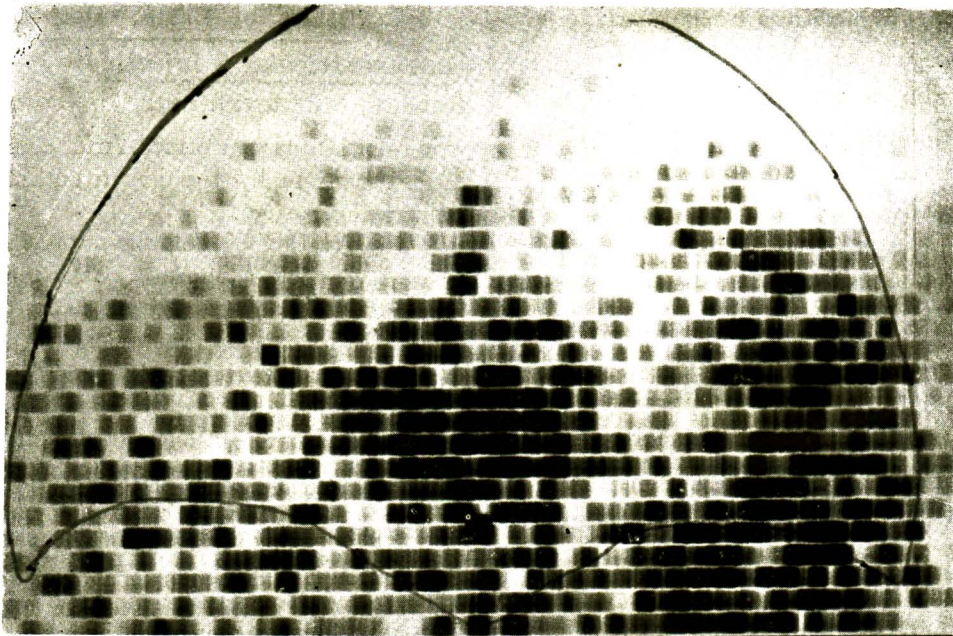
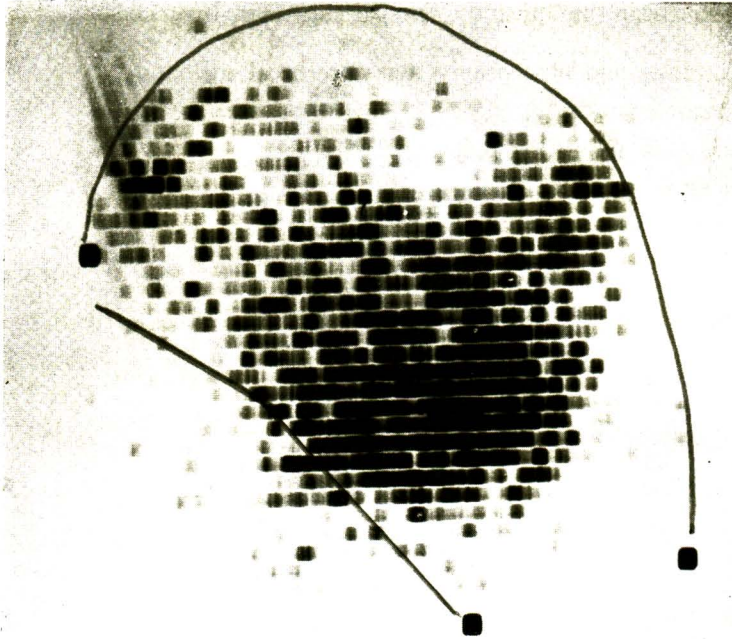


Figure 3. a and b. Lateral and antero-posterior scintigrams after intrathecal injection of ^{131}I -RISA in a patient with postoperative hydrocephalus. Delayed absorption pattern with large cystic collection at the temporal region corresponding to the operative site.

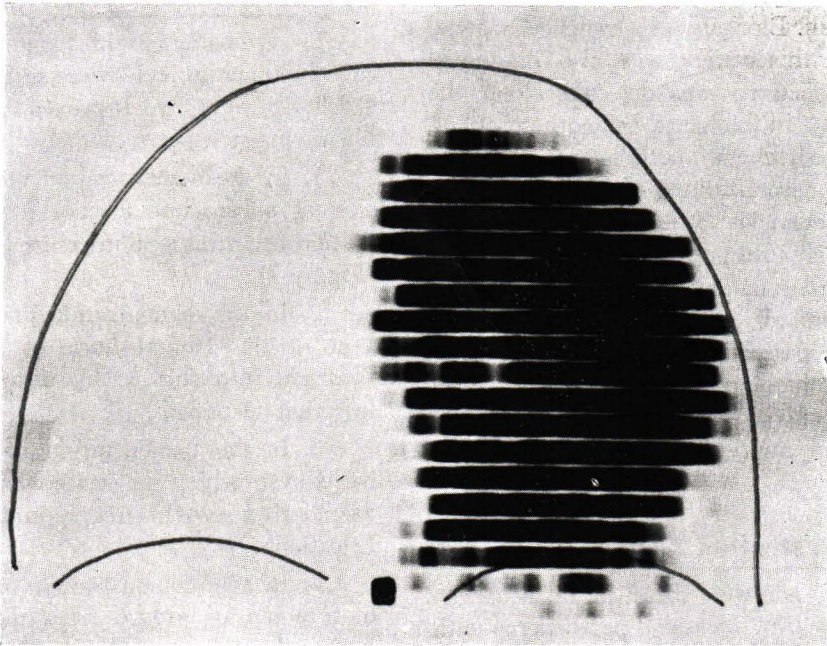


Figure 4. Antero - posterior scintigram after intraventricular injection of ^{131}I - RISA showing hydrocephalus with obstruction at the foramen of Monro. No radioactivity was detected over the opposite lateral and third ventricles.

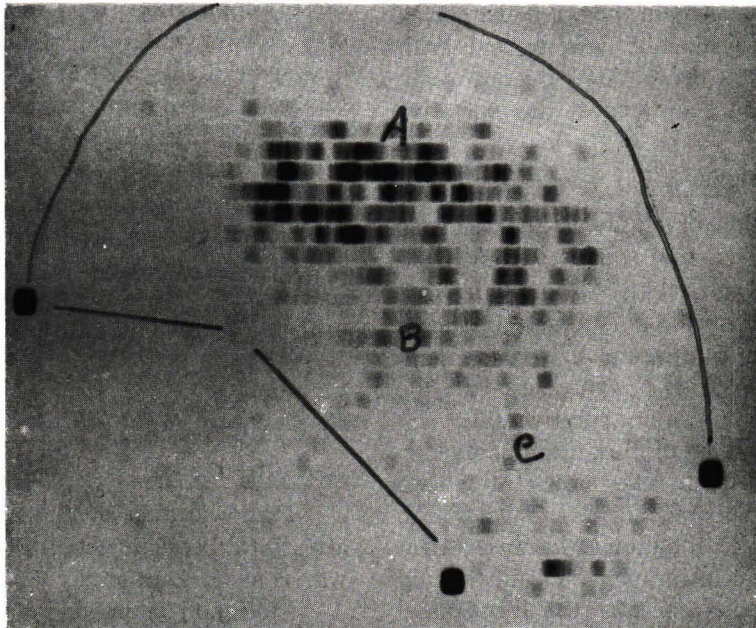


Figure 5. Lateral scintigram after intraventricular injection of ^{131}I - RISA in a patient with communicating hydrocephalus. The lateral (A), third (B) and fourth (C) ventricles as well as cisterna magna could be outlined,

fourth ventricle was demonstrated in the scintigram. Blockage of a ventriculo-atrial shunt in this patient was also diagnosed since no activity was detected along the shunt and in the heart. In another patient, however, filling of both lateral ventricles without visualization of the third and fourth ventricles 5 hours after injection was falsely interpreted since a communicating hydrocephalus was demonstrated in the air study.

One patient had a ventriculo-peritoneal shunt demonstrated by the presence of radioactivity along catheter and in the peritoneal cavity (Figure 6)

Case illustration 2. An 8 year-old girl was admitted because of headache, vomiting drowsiness and papilledema without localizing sign. Air ventriculography showed dilatation of the lateral and third ventricles with deformity of the fourth ventricle. Exploration of the posterior cranial fossa showed tuberculous granulation and tubercles on the cerebellar cortex and basal cistern. She was treated with antituberculous drugs. After the operation; large swelling developed at the operative site.

Cerebrospinal fluid scan after intrathecal injection of ^{131}I -RISA showed radioactivity in the spinal subarachnoid space and basal cistern with no entry into the occipital swelling. Another scan after intraventricular injection showed communication between the ventricles and the cystic swelling at the operative site.

On the basis of this finding, a ventriculo-atrial shunt was successfully used instead of a subarachnoid-peritoneal shunt.

In specific situation as in this patient the C.S.F. scintigraphy is valuable in clarifying some aspect of the intracranial pathology.

B. Encephalomeningocele

Twelve patients with fronto-ethmoidal encephalomeningocele were studied by the C.S.F. scintigraphy. It proved to be valuable in many aspects, namely:

1. In the demonstration of the extension of subarachnoid space into the herniation by intrathecal injection (7 patients), (Figure 7);

2. In the demonstration of the extension of the frontal horn of the lateral ventricle into the sac by intraventricular injection (1 patient);

3. In the demonstration of porencephalic cyst which is occasionally seen in association with encephalomeningocele (2 patients);

4. In the demonstration of blockage of foramen of Monro from distortion of brain, the unilateral hydrocephalus being shown after intraventricular injection;

5. In the demonstration of a ball-valve action, a mechanism in operation in some patients with this disease. Intrathecal injection in a 13 year-old boy with progressively enlarging encephalomeningocele showed entry of the radioisotope from the basal cistern into the herniation within 3 hours. Injection of the radioisotope directly into the cavity of the sac, however, showed no communication into the intracranial cavity even after 24 hours. A one-way flow between the intracranial subarachnoid space and the meningocele is therefore established.

C. Cerebrospinal fluid rhinorrhoea and otorrhoea.

Demonstration of the fistulous tract after intrathecal injection of radioisotope was done in 2 patients.

Collection of nasal and aural drainage after intrathecal injection helps to verify

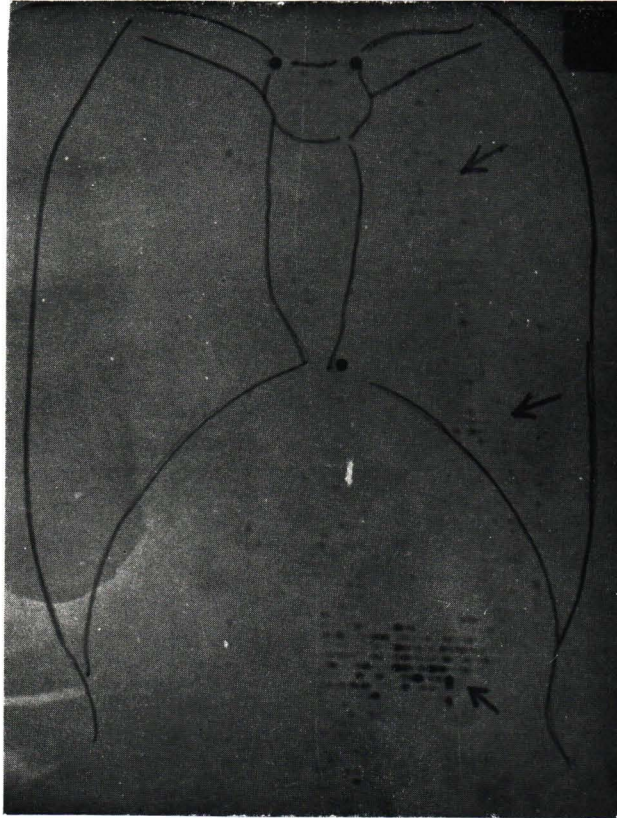


Figure 6. Scintigram of the head and trunk in a patient with a ventriculoperitoneal shunt. The radioactivity was shown along the shunt and in the peritoneal cavity, proving the patency of the shunt.

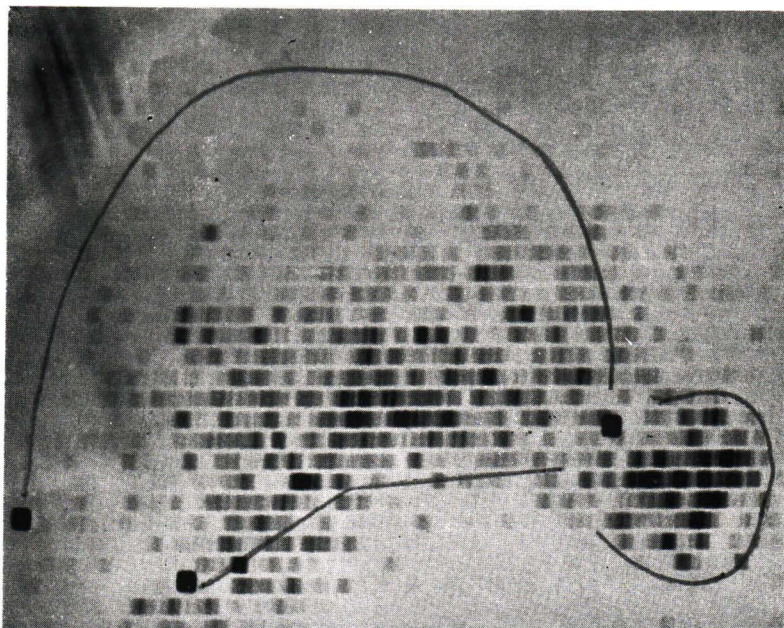


Figure 7. Lateral scintigram after intrathecal injection of ^{131}I -RISA showing the extension of subarachnoid space into the sac of sincipital encephalomeningocele.

the presence of a fistula in 2 patients. High radioactive count in the fluid collected from nose or ear, close to the count in the cerebrospinal fluid, proved the

nature of the fluid. On the contrary, profused nasal discharge after trauma in a patient was not cerebrospinal fluid. (Table 3.)

Table 3

Patient	Discharge	Blood count/min/ml.	Discharge (maximal activity) count/min/ml.	CSF (lumbar) count/min/ml.	Time after injection hours
1. S.S.	C.S.F. Otorrhoea	728	48700	-	4
2. S.B.	C.S.F. Rhinorrhoea	(1) 1353	44737	-	4
		(2) 416	-	12251	48
3. U.	Posttraumatic nasal discharge	(1) 227	325	44846	12
		(2) 32	161	2813	60

Table 3 shows the count rate of radioactivity in the blood, collected discharge and cerebrospinal fluid after intrathecal injection of ^{203}Hg -chlormerodrin. In the first two patients, the discharge from ear and nose had high radioactivity and thus was proven to be cerebrospinal fluid. In the third patient the radioactivity in the discharge was much lower than in the cerebrospinal fluid.

D. Myelography

Level of the obstruction of the spinal subarachnoid space was demonstrated in one patient with spinal cord tumor. The radioisotopic column ended at the site of the obstruction.

E. Intracranial cystic lesions

Direct injection of the radioisotope into an intracranial cystic lesion such as cyst, hematoma and abscess helps in the delineation of the cavity of the lesion. It was successfully used in 2 patients, one intracerebral and one subdural hematoma

Discussion

Radioisotopic visualization of the cerebrospinal fluid space offers a new approach to the study of the central nervous system. It gives the morphologic data on the subarachnoid and ventricular areas as well as physiologic dynamics of the flow, communication and absorption of the cerebrospinal fluid which cannot be obtained by any other method. It is also advantageous in being a simple and inno-

cuous method comparing to the neuroroentgenographic investigations. The resolutions of the scintigram however, is not as sharp and informative as the angiographic or air studies. Normal landmarks of the skull do not appear in the scan; the localization of an abnormality is therefore not as accurate as in the roentgenography.

The scintigraphy of the space containing cerebrospinal fluid had proved valuable in demonstrating its size and shape as well as the communications from the site of injection. Blockage of the pathway in the spinal canal, basal cisterns and ventricles has been shown. Abnormal communication into a cystic space, an encephalomeningocele and a cerebrospinal fluid fistula are also demonstrated. It is also useful in detecting patency of a cerebrospinal fluid shunt.

Serial scintigrams and time factor extend the scope of the C.S.F. scintigraphy to a dynamic study of its flow and absorption which has not been possible by any other method now in use. alteration of the cerebrospinal fluid dynamics in various diseases especially hydrocephalus can now be demonstrated. Many factors are found to be responsible for the production of communicating hydrocephalus. Normal absorption pattern is seen in a number of hydrocephalic patients suffering from tuberculous meningitis. They have high protein level in the cerebrospinal fluid. We believe that the retention of fluid with resulting increased pressure is the result of exudation of protein into the subarachnoid space by the inflammatory process. The flow and absorption are not necessarily altered. On the contrary, a delay in flow is a clearly recognizable phenomenon in some patients. The in-

flammatory process with thick exudate and fibrin can undoubtedly interfere with the flow in the narrow subarachnoid space and the small holes in the arachnoid villi. This condition has been proven to be reversible in one patient. Arachnoid adhesion, a well recognized entity known to cause hydrocephalus, is again shown in the radioisotopic scan.

Summary

The clinical uses of scintigraphy of the cerebrospinal fluid space in the investigations of 48 patients with various diseases are outlined. Scintigrams of the spaces and dynamic study of the flow and absorption of cerebrospinal fluid are demonstrated. It has proved to be a reliable, informative, simple and innocuous method.

References

1. Bauer, F.K., and Yuhl, F.T.: Myelography by means of I^{131} . *Neurological* 3: 341, 1953.
2. Brocklehurst, G.: Use of radio-iodinated serum albumin in the study of cerebrospinal fluid flow. *J. Neurol. Neurosurg. Psychiat.* 31:162, 1968.
3. Di Chiro, G.: New radiographic and isotopic procedures in neurological diagnosis *JAMA.* 188:524, 1964.
4. Di Chiro, G., Reames, P.M., and Matthews, W.E.: RISA-ventriculography and RISA-cisternography. *Neurology* 14: 185, 1964.
5. Di Chiro, G., and A.S., Jr.: Evaluation of surgical and spontaneous cerebrospinal fluid shunts by isotope scanning. *J. Neurosurg.* 24:743, 1966.
6. Di Chiro, G., Ommaya, A.K., Ashburn, W.L., and Briner, W.H.: Isotope

cisternography in the diagnosis and follow up of cerebrospinal fluid rhinorrhoea. *J Neurosurg.* 28:522, 1968.

7. Kagen, A., Tsuchiya, G., Patterson, V., and Sugar, O.: Test for patency of ventriculovascular shunt for hydrocephalus with radioactive iodinated serum albumin. *J. Neurosurg.* 20:1025, 1963.

8. Matin, P., Goodwin, D.A., and Nardo, G.L.: Cerebrospinal fluid scanning and ventricular shunts. *Radiology* 94:435, 1970.

9. Perryman, C.R., Noble, P.R., and Bragdon, F.H.: Myeloscintigraphy: a useful procedure for localization of spinal lesions. *Am. J. Roentgenol.* 81:104, 1958.

10. Rieselbach, R.E.: Subarachnoid distribution of drugs after lumbar injection. *New Engl. J. Med.* 267:1273, 1962.

11. Sweet, W.H., Brownell, G.L., School, J.A., Bowsher, D.R., Benda, P. and Stickley, E.E.: The formation, flow and absorption of cerebrospinal fluid; newer concepts based on studies with isotopes. *Res. Publ. Ass. new. ment. Dis.* 34:101, 1954.

12. Tator, C.H., Fleming, J.F.R., Sheppard, R.H. and Turner, B.A.: Radioisotopic test for communicating hydrocephalus. *J. Neurosurg.* 28:327, 1968.
