

## Impingement syndrome of the shoulder

Jirun Apinun\*

Somsak Kuptniratsaikul\*\*

**Apinun J, Kuptniratsaikul S. Impingement syndrome of the shoulder. Chula Med J 2012  
May – Jun; 56(3): 343 - 58**

*Impingement syndrome of the shoulder is a common cause of shoulder pain. There are three types of shoulder impingement, namely, subacromial, subcoracoid, and internal impingement. They are described according to the location that impingement occurs. Each can present in isolation or combined with the others. Understanding in pathophysiology and pathomechanics of the impingement syndrome is essential in the treatment of the patient. Both static and dynamic factors play certain roles in the etiology of impingement. Clinical evaluation of the syndrome requires thorough physical examination and appropriate investigations. Goals of treatment include pain relief and restoration of the shoulder function. Any structural problems should be addressed and corrected. Moreover, associated physiologic and biomechanical factors must be treated. Nonsurgical management should be the initial mode of treatment. Surgical treatment is indicated if conservative treatment fails to improve the patient's symptoms.*

**Keywords :** *Impingement syndrome, subacromial impingement, subcoracoid impingement, internal impingement.*

Reprint request : Kuptniratsaikul S. Department of Orthopedics, Faculty of Medicine,  
Chulalongkorn University, Bangkok 10330, Thailand.

Received for publication: May 10, 2011.

\* Division of Orthopedics, King Chulalongkorn Memorial Hospital, Thai Red Cross Society

\*\* Department of Orthopedics, Faculty of Medicine, Chulalongkorn University

**จิรินทร์ อภินันท์, สมศักดิ์ คุปต์นิรัติศัยกุล. ภาวะการกดทับของเส้นเอ็นบริเวณหัวไหล่.  
จุฬาลงกรณ์เวชสาร 2555 พ.ศ. - ม.ย.; 56(3): 343 - 58**

ภาวะการกดทับของเส้นเอ็นเป็นสาเหตุสำคัญของอาการปวดไหล่ที่พบได้บ่อย ได้แก่ ภาวะการกดทับของเส้นเอ็นบริเวณหัวไหล่ ซึ่งสามารถแบ่งย่อยได้เป็น 3 ประเภทตามตำแหน่งที่เกิดการกดทับ ได้แก่ การกดทับไตปุ่มกระดูกอะโครเมียม, การกดทับหลังต่อปุ่มกระดูกโคราคอยด์ และการกดทับที่เกิดขึ้นภายในข้อไหล่ โดยภาวะการกดทับทั้ง 3 ชนิดนี้อาจเกิดร่วมกันได้ ความรู้และเข้าใจในพยาธิสรีรวิทยา และกลไกการเกิดโรคเป็นสิ่งจำเป็นอย่างยิ่งในการรักษาผู้ป่วยที่มีภาวะกดทับของเส้นเอ็นบริเวณหัวไหล่ การตรวจร่างกายอย่างละเอียดและการส่งตรวจวินิจฉัยที่เหมาะสมเป็นสิ่งสำคัญในการประเมินผู้ป่วยทางคลินิก เป้าหมายในการรักษาได้แก่ การรักษาอาการปวดและทำให้ผู้ป่วยสามารถกลับมาใช้งานหัวไหล่ได้อย่างเป็นปกติ โดยขจัดทั้งปัจจัยทางกายวิภาค ปัจจัยทางสรีรวิทยา และชีวกลจักรที่เป็นสาเหตุของการเกิดโรค การรักษาควรเริ่มด้วยวิธีการรักษาแบบอนุรักษ์จนเมื่ออาการไม่ดีขึ้นจึงใช้วิธีการรักษาโดยการผ่าตัด

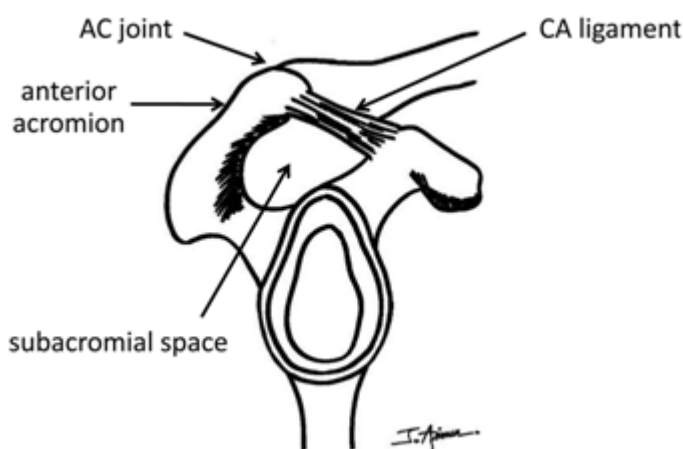
**คำสำคัญ :** ภาวะการกดทับของเส้นเอ็นบริเวณหัวไหล่, การกดทับของเส้นเอ็นไตปุ่มกระดูกอะโครเมียม, การกดทับของเส้นเอ็นหลังต่อปุ่มกระดูกโคราคอยด์, การกดทับของเส้นเอ็นที่เกิดขึ้นภายในข้อไหล่.

Pain around the shoulder that worsened by elevation of the shoulder is mostly caused by impingement syndrome. A thorough examination is always required for the evaluation of this condition due to variability of the physical findings, different entities and wide spectrum of the diseases, and several underlying factors that interplay among one another. Shoulder impingement can be categorized into three types, namely, subacromial impingement, subcoracoid impingement, and internal impingement.

### Subacromial impingement

Subacromial impingement, also known as outlet impingement, classic impingement, or external impingement, is described as compression of the bursa, the rotator cuff, and the long head of the biceps tendon in the subacromial space.<sup>(1)</sup> The compression typically occurs between 70° and 120° of arm elevation (the impingement arc). The superior border of this space is the coracoacromial arch, formed by the anterior acromion, the coracoacromial (CA) ligament, and the acromioclavicular (AC) joint. The

inferior border of this space is the humeral head. (Figure 1) Impingement occur if there is a change in any structure that diminishes the size of the space or the volume of tissue in the space is increased. Acromial morphology may contribute to the impingement syndrome. Bigliani *et al.*<sup>(2)</sup> classified acromion shape as type I (flat), type II (curved), and type III (hooked). (Figure 2) They also demonstrated the relationship between type III acromion with rotator cuff tears. Acromial spurs, the hypertrophic thickened CA ligament, inferiorly projecting osteophytes from AC joint, and an unstable os acromiale site also cause irritation to the underlying bursa and tendons. Elevation of the humeral head from the weakened rotator cuff can pinch the overlying tissue against the acromion. Scapular dyskinesia, defined as the alteration in the resting scapular position and dynamic scapular motion, results in lack of acromial elevation in the moving arm and decrease the maximal rotator cuff function.<sup>(3,4,5)</sup> The edema and inflammation of the bursal tissues and the tendon passed under the coracoacromial arch increase the volume of tissue,

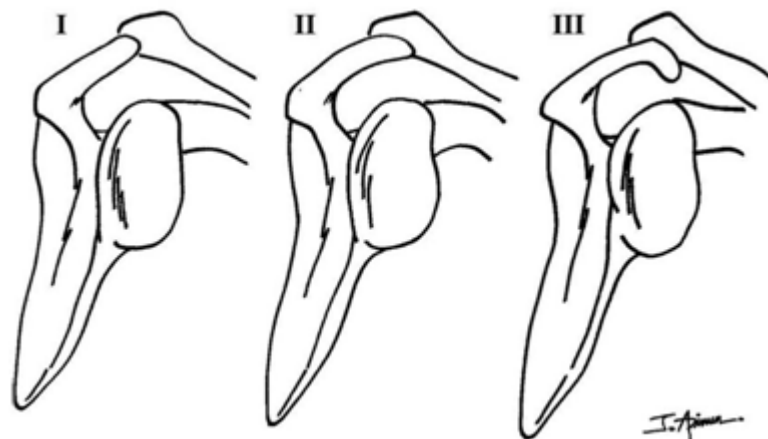


**Figure 1.** Borders of subacromial space. The superior border formed by the anterior acromion, the CA ligament, and the AC joint. The inferior border is the humeral head.

and therefore the likelihood of impingement is increased. Moreover, the tissue inflammation caused by the impingement will worsen the degree of impingement itself, creating a vicious cycle of impingement.

Neer<sup>(1)</sup> described subacromial impingement syndrome as a progressive continuation of disease ranging from stage I characterized by edema and hemorrhage of the tendon which are reversible, stage II as fibrosis and tendinitis with permanent histologic changes resulted in recurrent pain with activity, to stage III manifested the bone spurs and tendon ruptures leading to progressive disability. The typical symptoms suggestive of subacromial impingement include the anterolateral shoulder pain with overhead activities and night pain while lying on the affected side. Loss of motion or weakness may be associated with pain. Physical examination should be performed on both sides. The Range of motion in all directions is assessed. The specific physical findings for subacromial impingement include pain with passive internal rotation in 90° forward flexion of the shoulder (Hawkins' test) and pain with passive arm elevation

in the scapular plane (Neer's impingement sign) which is resolved by 10 mL of lidocaine injection into the subacromial space (Neer's impingement test). (Figure 3) The strength testing of supraspinatus, infraspinatus, and subscapularis is helpful for evaluation of the integrity of the rotator cuff. Examination of the scapula is done both when the patient is in resting posture and dynamic motion. Medial border prominence, protraction, elevation, rotation, or winging of the scapula should be documented. (Figure 4) Side-to-side asymmetry of the distance between the inferior medial scapular tip and the spine, which is greater than 1.5 cm, has the correlation with excessive scapular internal rotation.<sup>(6)</sup> Positive results of dynamic maneuvers that relieve the symptoms of pain or weakness, such as scapular assistance test and scapular retraction test, indicate the involvement of scapular dyskinesis in the etiology of impingement.<sup>(5)</sup> (Figure 5) The factors influencing scapular dyskinesis should be evaluated proximally and distally.<sup>(7)</sup> Proximal factors include excessive thoracic kyphosis, increased cervical lordosis, lumbar lordosis, pelvic tilt, hip rotational



**Figure 2.** Acromial morphology – Type I (flat), Type II (curved), Type III (hooked).

abnormalities, instability of the hip and trunk, trunk inflexibility, tightness in the pectoralis minor or the short head of biceps, and periscapular muscle weakness. Instability or pain resulted from AC or glenohumeral joint injuries are defined as distal factors of scapular dyskinesia. Malunited fracture of the

clavicle with shortening or angulation and posterior capsular tightness can also create these abnormal scapular patterns and positions. Examination of the cervical spine and neurovascular evaluation of both upper extremities should be accomplished to rule out neurovascular causes of the pain.

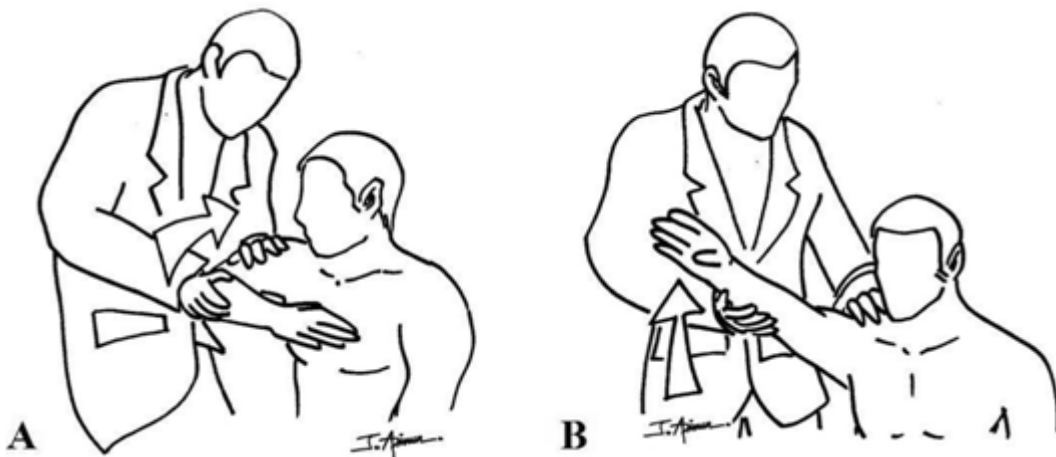
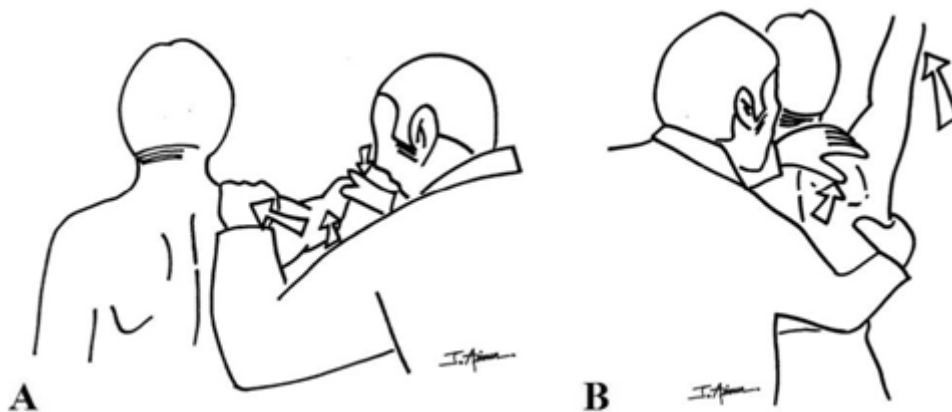


Figure 3. (A) Hawkins' test. (B) Neer's impingement sign.

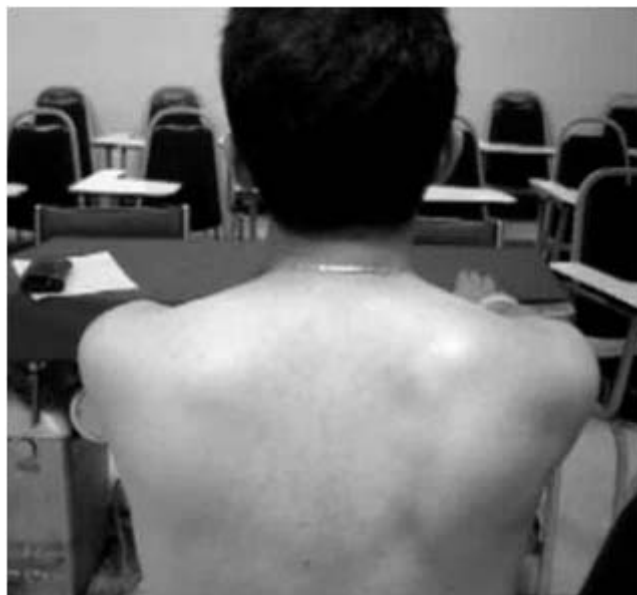

Figure 4. Medial border prominence of right scapula.



**Figure 5.** (A) Scapular retraction test. The examiner stabilize the entire medial border of the retracted scapula against the thorax. (B) Scapular assistance test. The examiner stabilize the upper medial border and rotate the inferomedial border as the patient's arm is abducted.

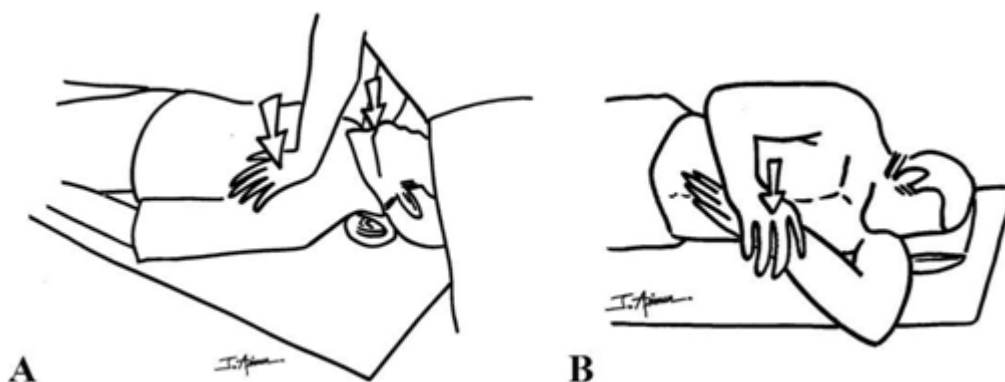
Radiographic studies include an anteroposterior (AP) view in the scapular plane, an axillary view, and a supraspinatus outlet view. The AP view helps distinguish between other sources of pain, such as calcific tendinitis and arthritis of the glenohumeral and AC joint. The superior migration of the head of humerus can also be demonstrated. It has been suggested that an acromiohumeral distance less than 7 mm is consistent with a rotator cuff tear.<sup>(8)</sup> The axillary view is most useful for demonstration of the os acromiale if present. The supraspinatus outlet view (a lateral view of the scapula with the beam oriented 10° caudally) is used to classify the acromial morphology and determine the presence of acromial spurs. Magnetic resonance imaging (MRI) allows thorough evaluation of the soft tissues and bony structures. Routine MRI is not recommended in the early stage of the disease. However, if the symptoms persist or significant rotator cuff pathology is suspected, MRI is recommended.

The initial management of a patient with subacromial impingement is nonoperative treatment.

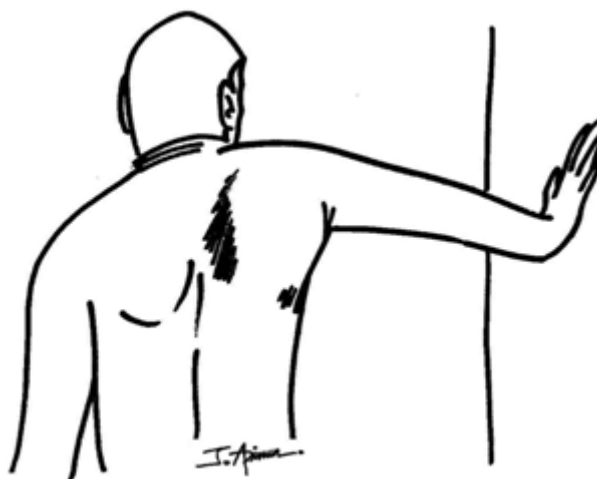
Avoidance of inciting activities and nonsteroidal anti-inflammatory drugs (NSAIDs) should be the initial modes of treatment. Subacromial steroid injection is effective in the short term for alleviating pain and improving the range of motion of the shoulder.<sup>(9)</sup> Repeated injections should be avoided because of the potential adverse effects on tendon integrity.<sup>(10,11)</sup> Modalities, such as ultrasound, iontophoresis, ice/heat, electrical stimulation, have not been shown to be efficacious.<sup>(12)</sup> Basis of rehabilitation is to treat the associated physiologic and biomechanical factors and reestablish normal coupled scapulohumeral rhythm. A rehabilitation program should begin with restoration of flexibility -: sleeper stretches for posterior capsular tightness, open book stretches for coracoid-based inflexibility, and general flexibility exercises for the trunk. (Figure 6) Restoration of the muscle activation strength and sequences should start proximally and end distally.<sup>(13,14)</sup> Optimal rotator cuff function can only be achieved from a stabilized, retracted scapular base.<sup>(15,16)</sup> Therefore, the emphasis on rotator cuff rehabilitation should occur

after proximal stability is established. Periscapular muscle activation is facilitated by the synergistic proximal trunk and hip muscle activations. Exercise sets should include the following: integrated hip and trunk extension and scapular retraction movements (lawn mower pulls); scapular pinches; closed chain scapular clock exercises; and integrated trunk extension, scapular retraction, and arm extension exercises (low row exercises).<sup>(17)</sup> (Figure 7) After scapular control is achieved, rotator cuff rehabilitation should be implemented with an emphasis on cocontraction of the muscles in force couples and

integrated scapular stabilization-humeral head depression exercises. Rotator cuff exercises may progress from the closed to open chain position, from the horizontal to the vertical to the diagonal direction, and from slow to fast speed. Each type of progression increases rotator cuff muscle activation.<sup>(18)</sup> It may take 6 weeks before substantial benefit can be recognized. The program should be continued as long as the patient is making progress. An increase in pain on doing open chain rotator cuff exercises indicates a wrong emphasis at the wrong stage of the rehabilitation protocol.




**Figure 6.** (A) Open book stretches for coracoid-based inflexibility. (B) Sleeper stretches for posterior capsular tightness.



**Figure 7.** Closed chain scapular clock exercise. The hand is placed on the wall with varying degrees of abduction and flexion.

If the symptoms persist after a 3- to 6-month program of nonoperative treatment, subacromial decompression is therefore indicated. The goals of surgery are to debride the subacromial bursa, release the CA ligament, and achieve a flat, smooth acromial undersurface extending from the AC joint to the anterolateral corner of the acromion. Subacromial decompression can be done in either open or arthroscopic manner. In the arthroscopic group of patients, more rapid regaining flexion and strength were evident in the first 3 months postoperatively but there was no difference in the long term.<sup>(19,20)</sup> Another advantage of arthroscopic surgery includes shorter hospitalization, less use of narcotic medication, and earlier return to work and daily living activities. Arthroscopy also provides a direct visualization of the glenohumeral joint and the deep surface of the rotator cuff. Because the origin of the deltoid is over the entire anterior acromion, either open or arthroscopic acromioplasty can detach a substantial amount of the

deltoid origin. (Figure 8) Torpey *et al.*<sup>(21)</sup> indicated that 4-mm bony removal would detach approximately half the deltoid fibers, whereas 6-mm bony removal would detach approximately 75% of the fiber origin. Based on average anterior acromial thickness of 6.5 to 8.0 mm,<sup>(22)</sup> resection of 2-4 mm of the bone is recommended in order to prevent excessive bone removal. More than 5 mm of resected bone can lead to an increased risk of acromial fracture and superior humeral head migration.<sup>(23)</sup> The subacromial bursa is a potent source of pain and possesses increased levels of inflammatory mediators.<sup>(24,25)</sup> Therefore, the superficial bursa should be completely removed. However, removal of the deep bursa that is adherent to the tendon may not be needed. Removal of inferior clavicular spur and medial acromial osteophyte at AC joint should be done to achieve flat, smooth undersurface for tendon gliding. In the presence of symptomatic os acromiale, fragment excision or open reduction with internal fixation should be done.



**Figure 8.** Lateral view of the attachment of CA ligament and deltoid fascia on the entire anterior acromion. Acromioplasty, either open or arthroscopic, can detach a substantial amount of the deltoid origin.

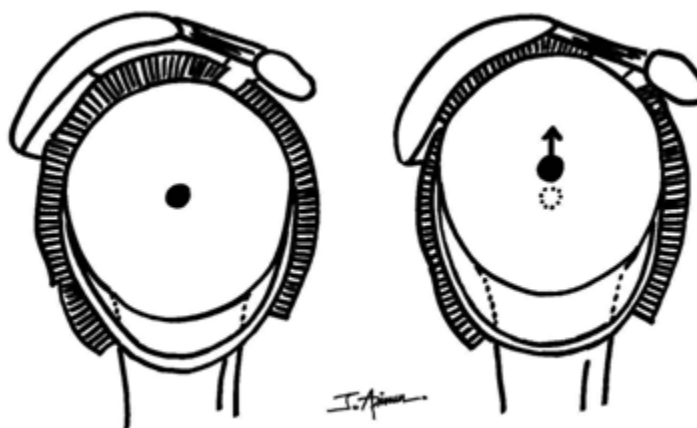


### Subcoracoid impingement

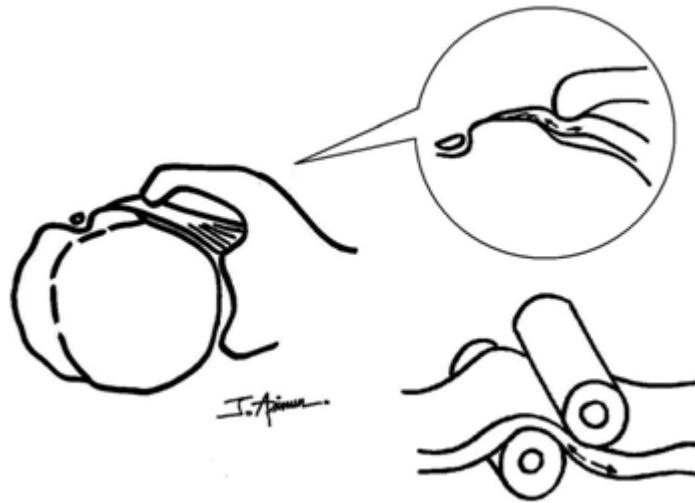
Subcoracoid impingement is characterized by impingement of the subscapularis tendon in the subcoracoid space. The subcoracoid space is defined as the potential space between the coracoid process and lesser tuberosity of the humerus. It is occupied by the anterior glenohumeral joint capsule, the subscapularis tendon, the subcoracoid bursa, and still has room for gliding of these soft tissues during shoulder motion. The clearance in this space can be affected by idiopathic individual variation and traumatic/iatrogenic alteration of the osseous structures that form the space boundaries. The anatomic morphometric studies of scapula were described in the literature.<sup>(26,27)</sup> Relationship between morphology of lesser tuberosity of humerus and subcoracoid impingement syndrome was demonstrated by Friedman *et al.*<sup>(28)</sup> They found a higher incidence of prominent lesser tuberosities in the symptomatic patients compared with the asymptomatic volunteers. Malunited fractures of coracoid process, lesser tuberosity, or glenoid and operations such as Bristow or Trillat procedure and glenoid osteotomy have been implicated concerned as a cause of subcoracoid impingement. The

increasing volume of the contents in the space caused by inflammation, amyloid deposits, calcification, ganglion cyst, displacement of biceps tendon, and scar of the coracohumeral ligament, any of these can diminish the clearance and results in impingement in the subcoracoid space. The secondary subcoracoid impingement can be caused by the anterior instability of the humeral head<sup>(29)</sup> and upward migration of the humerus.<sup>(30)</sup> (Figure 9) Lo and Burkhart<sup>(31)</sup> suggested that, in subcoracoid impingement, the subscapularis tendon is squeezed between the coracoid and lesser tuberosity and fail in tension at the articular side (the roller-wringer effect). (Figure 10)

The typical symptom is anterior shoulder pain exacerbated by forward flexion and internal rotation combined with horizontal adduction. The pain may refer to the front of upper arm and forearm. Physical findings reveal tenderness over the coracoid process. The modified Hawkins test (Hawkins' impingement test with cross-arm adduction) frequently reproduces the localized pain in the front of the shoulder. Subscapularis testing may elicit the pain or weakness. Lidocaine injection into the subcoracoid region provides marked pain relief.<sup>(30,32)</sup>



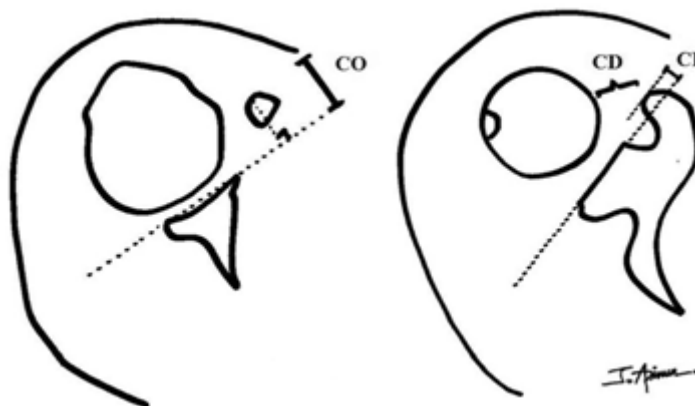
**Figure 9.** As the tip of the coracoid process lies at the level above the maximum diameter of the humeral head, the upward migration of the humeral head can be the cause of the secondary subcoracoid impingement.



**Figure 10.** The roller-wringer effect. The subscapularis tendon is squeezed between the coracoid and lesser tuberosity and fail in tension at the articular side.

Plain radiographs in AP and axillary views may be helpful in detection of anatomical abnormalities and calcification. Frequently, however, more sophisticated investigations are required. Computerized tomography (CT scan) and MRI are useful in measurement of the coracohumeral distance (CD : the minimum distance between the coracoid process and lesser tuberosity), the coracoid overlap (CO : the projection of the coracoid tip beyond the line of the glenoid), and the coracoid index (CI : similar

to CO but the reference is the coracoid base).<sup>(32-37)</sup> (Figure 11) However, the standard value in normal and symptomatic population cannot be established. The imaging modalities, setting position of the arm, and gender can affect the measured values. However, anecdotal evidence suggests that  $CD < 10$  mm,  $CO$  and  $CI > 15-20$  mm may correlate with subcoracoid impingement.<sup>(38)</sup> MRI also allows excellent visualization of the soft tissue components within the subcoracoid space.



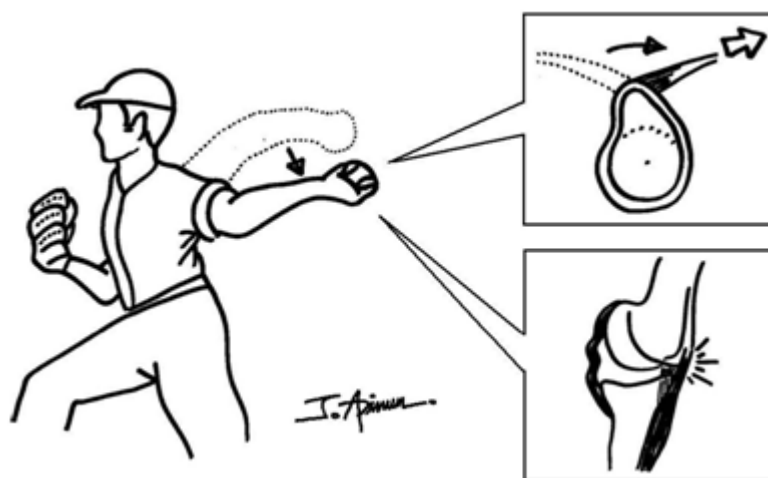
**Figure 11.** Representative axial cuts from CT / MRI scan are used to measure the coracoid overlap (CO : the projection of the coracoid tip beyond the line of the glenoid), the coracohumeral distance (CD : the minimum distance between the coracoid process and lesser tuberosity), and the coracoid index (CI : similar to CO but the reference is the coracoid base)

Most cases of idiopathic subcoracoid impingement can be successfully treated with conservative method. <sup>(30)</sup> Provocative positions should be avoided. NSAIDs and nonnarcotic analgesics are helpful to alleviate the pain. Physical therapy program includes correction of any pectoralis major contracture, strengthening of the rotator cuff and scapular stabilizers. <sup>(39)</sup> Subcoracoid corticosteroid injection may be used. <sup>(40)</sup> Surgical decompression of the subcoracoid space may be undertaken after failure of conservative management. Coracoplasty can be done by open or arthroscopic technique. Arthroscopic coracoplasty can be performed through a subacromial approach <sup>(41)</sup> or through the rotator interval. <sup>(42)</sup> Advantages of the arthroscopic coracoplasty include the avoidance of conjoined tendon attachment, less surgical dissection, and ability to treat other intraarticular or subacromial pathologies concurrently. The targeted site for bony removal is the posterolateral aspect of the coracoid tip. Some authors advocated the resection of the CA ligament, <sup>(30,40)</sup> whereas others

recommended the maintenance of the CA ligament integrity. <sup>(43)</sup> Lo *et al.* <sup>(42)</sup> suggested that the clearance between coracoid and subscapularis should be increased to approximately 7 mm after coracoplasty. In cases of secondary subcoracoid impingement caused by anterior shoulder instability, operative stabilization is the key procedure of the treatment. <sup>(29)</sup>

### Internal impingement

Internal impingement was first described by Walch *et al.* <sup>(44)</sup> as the contact between the articular side of the rotator cuff and the posterosuperior glenoid rim in abduction-external rotation position as seen during late cocking and early acceleration phases of throwing. It was demonstrated only on the throwing shoulder of overhead athletes and not the other side. It can be asymptomatic or leads to a broad spectrum of interrelated pathologies, including undersurface tear of the rotator cuff, superior labral anterior posterior (SLAP) lesion, and cystic change on the humeral head. (Figure 12)



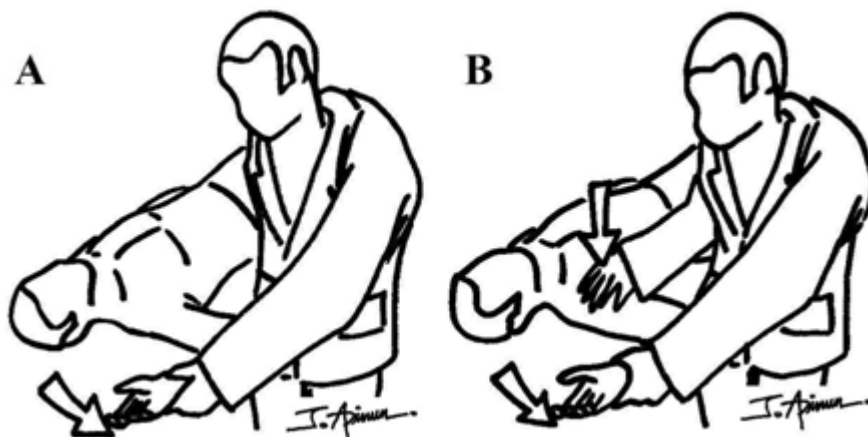
**Figure 12.** With the arm in a position of abduction and external rotation during late cocking phase, the maximized peel-back forces of biceps increase the shearing forces on the labrum. The greater tuberosity abuts against the superior glenoid. The torsional and shearing stresses on the rotator cuff fibers are increased. The repetitively stretched anterior capsule creates capsular laxity and microinstability.

The pathomechanics of internal impingement are a combination of capsular microinstability, excessive external rotation, and humeral retroversion. Stretching of the anterior capsule from the repetitive throwing, especially in athletes with improper throwing mechanics (hyperangulation or opening up during the acceleration phase), create anterior microinstability. With capsular laxity increases, external rotation of the humerus increases significantly.<sup>(45)</sup> Excessive external rotation of the humerus exerts increased shearing forces on the labrum and increased torsional and shearing stresses on the rotator cuff fibers.<sup>(46)</sup> Increases in humeral retroversion, which cause the adaptation of range of motion (ROM) into an externally rotated position without loss of total arc of motion, may be the protective bony adaptation against overstretching of the anterior capsule and internal impingement in the throwing athletes.

The patients commonly complain of shoulder pain during the late cocking and early acceleration phases of throwing. The performance in pitching

is generally affected by the pain. Posterior glenohumeral joint line tenderness may be found during the examination. Meister *et al.*<sup>(47)</sup> described the posterior impingement sign as the test for internal impingement. Ninety degree passive abduction and maximally external rotation of the arm reproduce the pain or discomfort in the posterosuperior aspect of the shoulder and the relocation test relieves the symptoms. (Figure 13) Rotator cuff and SLAP testing may yield positive results. Passive ROM and laxity degree of both shoulders should be evaluated. Glenohumeral internal rotation deficit (GIRD) is defined as a loss of internal rotation more than  $25^{\circ}$  compared with the opposite shoulder or less than  $25^{\circ}$  of absolute value of internal rotation.<sup>(48)</sup>

Standard plain radiographs include AP view in the scapular plane, an axillary view, and a supraspinatus outlet view. MRI is used to confirm the suspected capsulolabral and rotator cuff pathology. However, in most of cases, the diagnosis is made on the basis of history and physical examination.



**Figure 13.** (A) Posterior impingement sign. Ninety-degree passive abduction and maximally external rotation of the arm reproduce pain or discomfort in the posterosuperior aspect of the shoulder. (B) Relocation test. Posterior-directed force applied on the humeral head alleviates the pain.

Nonsurgical treatment is the primary treatment in the patients with internal impingement. Ice and NSAIDs may be used to reduce pain and inflammation. The athlete is instructed to abstain from throwing for 2 to 6 weeks. The internal rotation deficit caused by inflammation and tightness of the internal rotators and posterior musculature should be improved by an aggressive program of posterior capsular stretching in conjunction with scapular stabilization, core stabilization, and rotator cuff strengthening. Surgical treatment is considered if the nonsurgical managements fail. Diagnostic arthroscopy is carried out to assess the labral tear and rotator cuff pathology. A tear in the labrum should be debrided or re-approximated to the glenoid rim. Undersurface rotator cuff tear can be debrided or repaired up to the size of the tear. If anterior microinstability is present, anterior plication or thermal shrinkage should be carried out. Release of the posterior capsule is indicated to improve internal rotation after failure of well-conducted stretching program.

## References

1. Neer CS 2nd. Anterior acromioplasty for the chronic impingement syndrome in the shoulder: a preliminary report. *J Bone Joint Surg Am* 1972 Jan;54(1):41-50
2. Bigliani LU, Morrison DS, April EW. The morphology of the acromion and its relationship to rotator cuff tears. *Orthop Trans* 1986; 10; 228
3. Lukasiewicz AC, McClure PW, Michener L, Pratt N, Sennett B. Comparison of 3-dimensional scapular position and orientation between subjects with and without shoulder impingement. *J Orthop Sports Phys Ther* 1999 Oct; 29(10): 574-83
4. Ludewig PM, Cook TM. Alterations in shoulder kinematics and associated muscle activity in people with symptoms of shoulder impingement. *Phys Ther* 2000 Mar; 80(3): 276-91
5. Kibler WB, McMullen J. Scapular dyskinesis and its relation to shoulder pain. *J Am Acad Orthop Surg* 2003 Mar-Apr; 11(2): 142-51
6. Schwellnus MP, Procter N. The repeatability of clinical and laboratory tests to measure scapular position and movement during arm abduction. *Int J Sports Med* 2003; 4(2); 1-11
7. Rubin B, Kibler WB. Fundamental principles of shoulder rehabilitation: conservative to postoperative management. *Arthroscopy* 2002 Nov-Dec; 18(9 Suppl 2): 29-39
8. Green A. Chronic massive rotator cuff tears: Evaluation and management. *J Am Acad Orthop Surg* 2003 Sep-Oct; 11(5): 321-31
9. Blair B, Rokito AS, Cuomo F, Jarolem K, Zuckerman JD. Efficacy of injections of corticosteroids for subacromial impingement syndrome. *J Bone Joint Surg Am* 1996 Nov; 78(11): 1685-9
10. Akpınar S, Hersekli MA, Demirors H, Tandogan RN, Kayaselcuk F. Effects of methylprednisolone and betamethasone injections on the rotator cuff: an experimental study in rats. *Adv Ther* 2002 Jul-Aug; 19(4): 194-201
11. Tillander B, Franzen LE, Karlsson MH, Norlin R. Effect of steroid injections on the rotator cuff: an experimental study in rats. *J Shoulder*

- Elbow Surg 1999 May-Jun; 8(3): 271-4
12. Kibler WB, Sciascia A. What went wrong and what to do about it: Pitfalls in the treatment of shoulder impingement. Instr Course Lect 2008; 57; 103-12
  13. Kibler WB, McMullen J, Uhl TL. Shoulder rehabilitation strategies, guidelines, and practices. Op Tech Sports Med 2000; 8; 258-67
  14. McMullen J, Uhl TL. A kinetic chain approach for shoulder rehabilitation. J Athl Train 2000 Jul; 35(3): 329-37
  15. Smith J, Dietrich CT, Kotajarvi BR, Kaufman KR. The effect of scapular protraction on isometric shoulder rotation strength in normal subjects. J Shoulder Elbow Surg 2006 May-Jun; 15(3): 339-43
  16. Kibler WB, Sciascia AD, Dome DC. Evaluation of apparent and absolute supraspinatus strength in patients with shoulder injury using the scapular retraction test. Am J Sports Med 2006 Oct; 34(10): 1643-7
  17. Kibler WB. Scapular involvement in impingement: Signs and symptoms. Instr Course Lect 2006; 55; 35-43
  18. Wise MB, Uhl TL, Mattacola CG, Nitz AJ, Kibler WB. The effect of limb support on muscle activation during shoulder exercises. J Shoulder Elbow Surg 2004 Nov-Dec; 13(6): 614-20
  19. Sachs RA, Stone ML, Devine S. Open vs arthroscopic acromioplasty: a prospective, randomized study. Arthroscopy 1994 Jun; 10(3): 248-54
  20. van Holsbeeck E, DeRycke J, Declercq G, Martens M, Verstreken J, Fabry G. Subacromial impingement: open versus arthroscopic decompression. Arthroscopy 1992; 8(2): 173-8
  21. Torpey BM, Ikeda K, Weng M, van der Heeden D, Chao EY, McFarland EG. The deltoid muscle origin. Histologic characteristics and effects of subacromial decompression. Am J Sports Med 1998 May-Jun; 26(3): 379-83
  22. Nicholson GP, Goodman DA, Flatow EL, Bigliani LU. The acromion: morphologic condition and age-related changes. A study of 420 scapulas. J Shoulder Elbow Surg 1996 Jan-Feb; 5(1): 1-11
  23. Flatow EL, Coleman WW, Kelkar R, Pollock RG, Soslowsky LJ, Mow VC, et al. The effect of anterior acromioplasty on rotator cuff contact: an experimental and computer stimulation. J Shoulder Elbow Surg 1995 Jan-Feb; 4(1 Suppl S): 53S-54S
  24. Blaine TA, Kim YS, Voloshin I, Chen D, Murakami K, Chang SS, et al. The molecular pathophysiology of subacromial bursitis in rotator cuff disease. J Shoulder Elbow Surg 2005 Jan-Feb; 14(1 Suppl S): 84S-89S
  25. Gotoh M, Hamada K, Yamakawa H, Inoue A, Fukuda H. Increased substance P in subacromial bursa and shoulder pain in rotator cuff diseases. J Orthop Res 1998 Sep; 16(5): 618-21
  26. Bhatia DN, de Beer JF, du Toit DF. Coracoid process anatomy: implications in radiographic imaging and surgery. Clin Anat 2007 Oct; 20(7): 774-84

27. Gumina S, Postacchini F, Orsina L, Cinotti G. The morphometry of the coracoid process- its aetiologic role in subcoracoid impingement syndrome. *Int Orthop* 1999;23(4): 198-201
28. Friedman RJ, Bonutti PM, Genez B. Cine magnetic resonance imaging of the subcoracoid region. *Orthopedics* 1998 May; 21(5): 545-8
29. Patte D. The subcoracoid impingement. *Clin Orthop Relat Res* 1990 May;(254):55-9
30. Gerber C, Terrier F, Ganz R. The role of the coracoid process in the chronic impingement syndrome. *J Bone Joint Surg Br* 1985 Nov; 67(5): 703-8
31. Lo IK, Burkhart SS. The etiology and assessment of subscapularis tendon tears: a case for subcoracoid impingement, the roller-wringer effect, and TUFF lesions of the subscapularis. *Arthroscopy* 2003 Dec; 19(10): 1142-50
32. Dines DM, Warren RF, Inglis AE, Pavlov H. The coracoid impingement syndrome. *J Bone Joint Surg Br* 1990 Mar; 72(2): 314-6
33. Gerber C, Terrier F, Zehnder R, Ganz R. The subcoracoid space. An anatomic study. *Clin Orthop Relat Res* 1987 Feb; (215): 132-8
34. Bonutti PM, Norfray JF, Friedman RJ, Genez BM. Kinematic MRI of the shoulder. *J Comput Assist Tomogr* 1993 Jul-Aug; 17(4): 666-9
35. Friedman RJ, Bonutti PM, Genez B. Cine magnetic resonance imaging of the subcoracoid region. *Orthopedics* 1998 May; 21(5): 545-8
36. Tan V, Moore RS Jr, Omarini L, Kneeland JB, Williams GR Jr, Iannotti JP. Magnetic resonance imaging analysis of coracoid morphology and its relation to rotator cuff tears. *Am J Orthop (Belle Mead NJ)* 2002 Jun; 31(6): 329-33
37. Giaroli EL, Major NM, Lemley DE, Lee J. Coracohumeral interval imaging in subcoracoid impingement syndrome on MRI. *Am J Roentgenol* 2006 Jan; 186(1): 242-6
38. Buss DD, Freehill MQ, Marra G. Typical and atypical shoulder impingement syndrome: diagnosis, treatment, and pitfalls. *Instr Course Lect* 2009; 58: 447-57
39. Russo R, Togo F. The subcoracoid impingement syndrome: Clinical, semeiologic, and therapeutic considerations. *Ital J Orthop Traumatol* 1991 Sep; 17(3): 351-8
40. Suenaga N, Minami A, Kaneda K. Postoperative subcoracoid impingement syndrome in patients with rotator cuff tear. *J Shoulder Elbow Surg* 2000 Jul-Aug;9(4):275-8
41. Karnaugh RD, Sperling JW, Warren RF. Arthroscopic treatment of coracoid impingement. *Arthroscopy* 2001 Sep; 17 (7); 784-7
42. Lo IK, Burkhart SS. Arthroscopic coracoplasty through the rotator interval. *Arthroscopy* 2003 Jul-Aug;19(6):667-71.
43. Kleist KD, Freehill MQ, Hamilton L, Buss DD, Fritts H. Computed tomography analysis of the coracoid process and anatomic structures of the shoulder after arthroscopic coracoid decompression: A cadaveric study. *J Shoulder Elbow Surg* 2007 Mar-Apr;16(2): 245-50

44. Walch G, Boileau P, Noel E, Donell ST. Impingement of the deep surface of the supraspinatus tendon on the posterosuperior glenoid rim: An arthroscopic study. *J Shoulder Elbow Surg* 1992 Sept-Oct;1(5): 238-45
45. Schneider DJ, Tibone JE, McGarry MH, Grossman MG, Veneziani S, Lee TQ. Biomechanical evaluation after five and ten millimeter anterior glenohumeral capsulorrhaphy using a novel shoulder model of increased laxity. *J Shoulder Elbow Surg* 2005 May-Jun;14(3): 318-23
46. Burkhart SS. Internal impingement of the shoulder. *Instr Course Lect* 2006;55:29-34
47. Meister K, Buckley B, Batts J. The posterior impingement sign: diagnosis of rotator cuff and posterior labral tears secondary to internal impingement in overhand athletes. *Am J Orthop (Belle Mead NJ)* 2004 Aug; 33(8): 412-5
48. Burkhart SS, Morgan CD, Kibler WB. The disabled throwing shoulder: spectrum of pathology Part I: pathoanatomy and biomechanics. *Arthroscopy* 2003 Apr; 19(4): 404-20