

รายงานผู้ป่วย

## **A difficult case of foreign body in the tracheobronchial trees: combined rigid & flexible bronchoscopy technique**

Prakobkiat Hirunwiwatkul\*

**Hirunwiwatkul P. A difficult case of foreign body in the tracheobronchial trees:  
combined rigid & flexible bronchoscopy technique. Chula Med J 1997 May;  
41(5): 381-8**

*Removal of a foreign body is commonly achieved by using a rigid ventilating bronchoscope. We report here a difficult case of a foreign body that was lodged in the distal part of bronchial tree and this suggested the combined technique of using both rigid and flexible bronchoscopes to remove the foreign body under clear direct vision.*

**Key words:** *Foreign body, Tracheobronchial tree.*

Reprint request : Hirunwiwatkul P, Department of Otolaryngology, Faculty of Medicine,  
Chulalongkorn University, Bangkok 10300, Thailand

Received for publication. March 15,1997.

---

\* Department of Otolaryngology, Faculty of Medicine, Chulalongkorn University.

ประกอบเกียรติ หิรัญวิวัฒน์กุล. สิ่งแปลกปลอมติดอยู่ในหลอดลมส่วนปลาย : การรักษาโดยใช้กล้องส่องตรวจหลอดลมชนิดแข็งร่วมกับกล้องส่องตรวจหลอดลมชนิดโค้งงอได้. จุฬาลงกรณ์เวชสาร 2540 พ.ค;41(5): 381-8

การรักษาในกรณีมีสิ่งแปลกปลอมเข้าไปติดอยู่ในหลอดลม โดยทั่วไปแพทย์สามารถใช้กล้องส่องตรวจหลอดลมชนิดแข็งส่องเข้าไปตรวจโดยวิธีวางยาสลบ และเอาสิ่งแปลกปลอมนั้นออกมาได้โดยไม่ยากนัก แต่ในกรณีที่สิ่งแปลกปลอมเข้าไปติดในหลอดลมส่วนปลาย การส่องตรวจโดยใช้กล้องส่องตรวจหลอดลมชนิดแข็งอาจไม่สามารถตรวจได้อย่างชัดเจน และการพยายามใช้คีบคีบจับเอาสิ่งแปลกปลอมนั้นออกมาอาจเป็นสิ่งที่ยากหรือทำไม่ได้หรืออาจทำให้สิ่งแปลกปลอมดังกล่าวถูกดันเข้าไปลึกขึ้นกว่าเดิมได้ รายงานนี้ได้นำเสนอวิธีการรักษาในกรณีดังกล่าวโดยใช้กล้องส่องตรวจหลอดลมชนิดแข็งร่วมกับกล้องส่องชนิดโค้งงอได้ ซึ่งทำให้สามารถคีบเอาสิ่งแปลกปลอมออกมาได้โดยสามารถเห็นสิ่งแปลกปลอมนั้นอย่างชัดเจน

Aspiration of a foreign body into the respiratory tract is a common and serious occurrence in childhood. Vegetable substances, particularly peanuts and grains, are the most common type of foreign body ingested. In the majority of cases the foreign body is aspirated into the right lung. Removal of the foreign body is commonly achieved by using a rigid ventilating bronchoscope. In rare cases the foreign body can not be removed during bronchoscopy due to too distal site of location. In such cases, our patients were referred to the surgical department for thoracotomy.

We report here a difficult case of foreign body that was lodged in the distal part of the bronchial trees and this suggested the combined technique of using both rigid and flexible bronchoscopes to remove the foreign body under clear direct vision.

### Case report

A chinese male 48 year old patient came to the hospital with the problem of foreign body ingestion. He stated that while chewing a plastic tube (the tube sold with UHT milk packages), he crushed the tube and accidentally swallowed a small piece. But he could not pass it into the stomach. He said that at the moment he coughed severely and felt that there was foreign body obstructing his throat. He felt a little pain when he swallowed water in order to try to push the foreign body into the stomach. He did not feel better after trying to treat himself so he came to hospital for proper management.

### Physical examination

Vital signs: BT=37.0°C, PR=88, BP=120/80, RR=18/min

Anterior & posterior rhinoscopy: normal

Oral cavity & oropharynx: normal

Fiberoptic laryngoscopy: normal

Neck: normal

Chest: mild rhonchi in right lower lobe, normal breath sound in left lung

Heart: normal S1 S2, no murmur

### Investigations

CBC: Hb=13.9, Hct=40, WBC=9500 (N=55 L=44 M=1), Plt=adequate

UA: normal

X-RAY chest:

No demonstrable opaque foreign body

Thickening of lung markings with minimal reticulonodular and fibrotic infiltration in both upper lobes with pleural thickening at both upper lobes which could have been an old granulomatous lesion.

Hyperaeration of both lungs.

**Impression: no demonstrable opaque F.B.**

X-RAY lateral neck & chest (soft tissue technique):

The examination revealed no opaque foreign body in the lateral chest view.

There was anterior bulging of the soft tissue of the neck at C6-C7 with tiny density anteriorly (foreign body?).

Mild degree of pectus excavatum of the sternum.

***Impression: Thickening of Prevertebral Soft Tissue at C5-C6 With Tiny Densities as Described.***

**Management**

Set OR for direct laryngoscopy + bronchoscopy + esophagoscopy under GA

The first procedure: Direct laryngoscopy  
normal larynx and hypopharynx, no foreign body seen

The next procedure: Rigid esophagoscopy  
normal esophagus, no foreign body seen

The next procedure: Rigid bronchoscopy

Trachea = normal


Right bronchus = white tube in the right lower lobe (posterior basal segment)

Left bronchus = normal

After detection of the foreign body (Fig.1) in the posterior basal segment of right lower lobe (Fig.2-3), removal was tried by using grasping forceps. Because the endoscopic view was limited from the rigid instrument, and since the site of the foreign body was too distal, the foreign body could not be removed by this technique.

An attempt was made to use fiberoptic bronchoscopy together with rigid bronchoscopy. The eyepiece lens of the rigid bronchoscope was removed and the lumen of the rigid bronchoscope occluded with a thin rubber sheet (cut from a

surgical glove). The rubber sheet was then punctured to create a hole to allow the fiberoptic scope to enter the lumen of the rigid bronchoscope with an air-seal technique. The fiberoptic scope could be smoothly passed to approach the target site while the anesthesiologist could ventilate the patient continuously. The target site was examined and the foreign body found to be a white plastic tube which color was similar to the secretion in the tracheobronchial trees. When the secretion around the foreign body was completely removed, it was found that the tube sleeve was close to the wall of the bronchial tree. This condition is very difficult for removal by the standard technique of using a rigid bronchoscope with forceps. But by using the combined technique, the foreign body could be distinctly seen and the biopsy forceps passed through the channel in the fiberoptic scope to remove the foreign body under direct vision and with no difficulty.



**Figure 1.** Foreign body found in bronchus

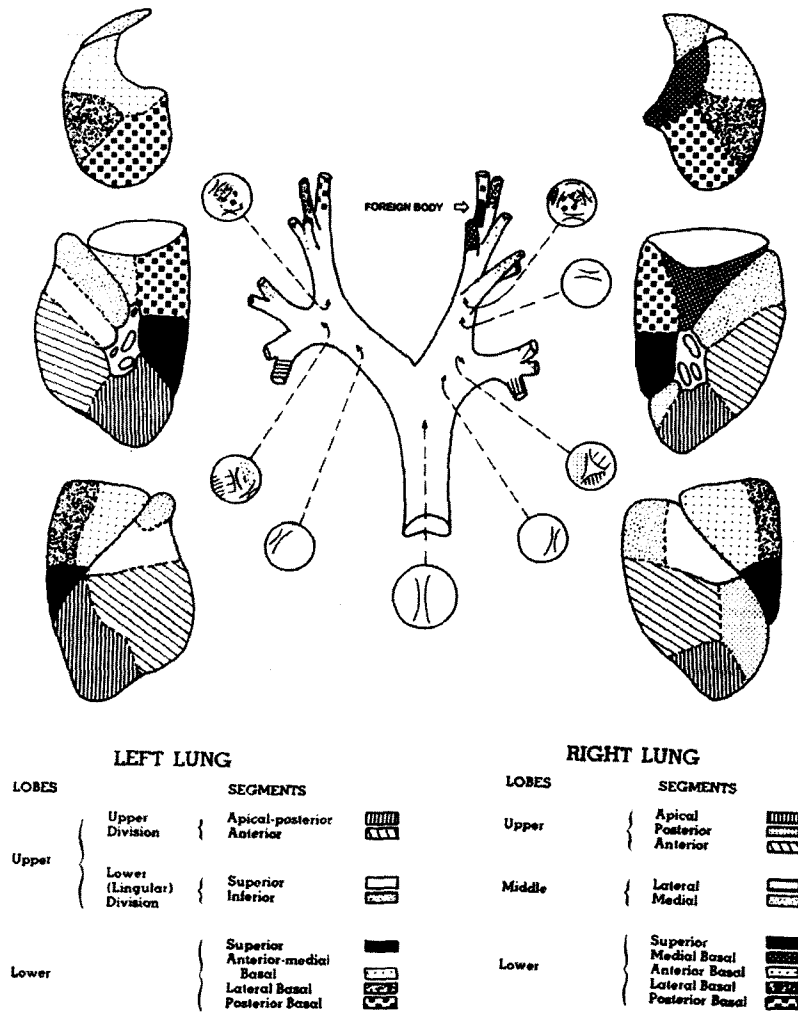


Figure 2. Showing bronchial tree and the site of foreign body

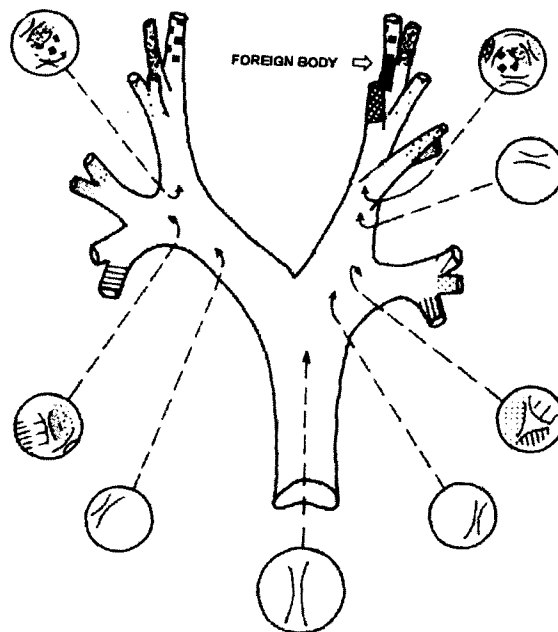


Figure 3. The site of foreign body in bronchial tree

## Result

Postoperatively the patient was given one dose of steroid (10 mg dexamethasone) and antibiotic (parenteral augmentin in one day followed by oral augmentin for 7 days). The patient have no cough or other abnormalities postoperatively and follow-up film chest was normal.

## Discussion & Comments

Aspiration of a foreign body into the respiratory tract is a serious accident in childhood. In the majority of cases the foreign body was aspirated into the right lung. In rare cases foreign body could be lodged in the distal part of bronchial trees and these may not be removed by standard rigid bronchoscopy due to the too distal site of foreign body and limitation of vision of rigid bronchoscopy. Bronchiectasis and persistent intractable pneumonia may develop. So many patients were referred to the surgical department for thoracotomy.

We report a difficult case of foreign body that was lodged in the distal part of bronchial trees and suggest the combined technique using rigid and flexible bronchoscope to remove a foreign body. By this technique we can see the distal bronchi with no hurry because while we exam, the anesthesiologist can ventilate the patient's lungs continuously. So we have time to examine the details of foreign body: site of obstruction, shape, size. We also can clean the operative field by using suction in flexible bronchoscope and can use the forceps passing

through the channel in the fiberoptic scope to grasp the foreign body in the best direction. We can see the foreign body at the end of the forceps clearly while we grasp it and while we draw back the fiberoptic scope through the lumen of rigid scope. We can keep the rigid scope in the fixed position while we remove the foreign body together with the flexible scope. If the foreign body falls from the forceps, we can try again with no more trauma from repeated rigid bronchoscopy.

The alternative method to perform in this situation may be using avial adaptor connected with endotracheal tube. By this method, anesthesiologist can ventilate while surgeon can use flexible endoscope to pass into the lumen of endotracheal tube. When the flexible endoscope is passed to the site of foreign body, surgeon can use the forceps to remove foreign body.

Using rigid telescope with rigid bronchoscope<sup>(1)</sup> is possible to do in the case like this, but I think in Thailand we can seek the flexible bronchoscope easier than the rigid telescope & other necessary instruments for this purpose. Many Thai doctors have much experience in flexible bronchoscopy, so combined using flexible and rigid bronchoscopy is not difficult. Because of the availability and experience in flexible bronchoscopy, I hope many Thai doctors can solve some difficult cases of foreign body in tracheobronchial trees and the incidence of thoracotomy will be reduced.

However using combined flexible and rigid bronchoscope may be limited to the adult

patients. In young children the lumen of the trachea may be small. The smallest flexible bronchoscope with therapeutic channel for biopsy may not be passed into the lumen of rigid bronchoscope.

The most common symptoms and signs of airway foreign bodies are coughing, wheezing and decreased air entry which differ from those of laryngotracheobronchitis, a disease common in children. This triad should alert the physician to the possibility of foreign body, even if no definite history of foreign body aspiration is made.

Chest x-rays have been found to be helpful but not mandatory because approximately one-third of our patients had normal findings. Only a few cases had visualized foreign bodies in the plain films so other changes in the x-ray should be identified. The roentgenographic examinations should include inspiratory and expiratory films because the type of change depends upon the object, its size relative to that of the bronchus and the changes of bronchial diameter during respiratory phase.

Most of the inhaled foreign bodies in our studies were organic which is similar to several other reports. Fruit seeds, not peanuts or beans as in other nations were the most common objects in our experience. The difference in the nature of the foreign bodies reflects the eating habits of people in different countries.

The inhaled foreign bodies were most commonly found in the trachea. These findings could be explained by the large unchewable seeds

which were different from smaller pieces of peanuts or beans commonly found in bronchial system.

Direct laryngoscopy and rigid bronchoscopy is the treatment of choice and should be performed in an institution where trained personnel are available. The use of less direct methods, such as bronchodilator or postural drainage, may lead to complications. Using flexible fiberoptic procedure to remove the foreign body in the airway (under local anesthesia) may cause an airway obstruction because the foreign body lodged in the subglottis<sup>(2)</sup>. Most physicians in Thailand have experience in flexible systems. The opportunities for young physicians to learn about rigid systems now become limited only in the training of otolaryngology, pediatric and cardiothoracic surgery. This warn us not to have too much confidence in the ability of flexible fiberscope system to remove this kind of large foreign body and remind us of the need to continue adequate training in the rigid systems.

General anesthesia should be used in almost all of the cases to facilitate the endoscopic procedure and the removal of the foreign body. It reduces trauma to the anatomic structures and eliminates discomfort and psychic trauma. However, general anesthesia is contraindicated in severe obstructive cases because of the increased risk of total obstruction of the airway in these patients.

Tracheotomy or thoracotomy may be necessary in a patient with impacted foreign body in the trachea or sharp object in the small airway after unsuccessful endoscopic removal.

Persistent pneumonitis was the most common postoperative complication. This may be the cause of death in patients with foreign body in the airway.

### Conclusions

Aspiration of foreign objects is a common cause of death of young children. Mostly foreign bodies in the airway were successfully removed by using rigid ventilating bronchoscope. In rare cases foreign body could be lodged in the distal part of bronchial trees (such as the basal segments of lower lobes) and these may not be removed by standard rigid bronchoscope due to too distal site of foreign body and limitation of vision of rigid bronchoscope. In some cases we

found foreign body attached to the wall of bronchi (such as plastic tube), this condition was difficult for surgeon to have success in removal by using rigid bronchoscope only.

Combined using flexible and rigid bronchoscope may be necessary to remove foreign body in these difficult situations. The patient in this report was successfully treated by this technique without any complications.

### References

1. Marzo SJ, Hotaling AJ. Trade-off between airway resistance and optical resolution in pediatric rigid bronchoscopy. *Ann Otol Rhinol Laryngol.* 1995 Apr; 104:282-7
2. Ikeda M, Kitahara S, Inouye T. Large radiolucent tracheal foreign body found by CT scan caused dyspnea: an admonition on flexible fiberoptic foreign body removal. *Surg Endosc.* 1996 Feb; 10(2):164-5