

## Primary spinal melanoma : presentation of a case with prolonged course

Paramee Thongsuksai\*

Sanguansin Ratanalert\*\*

**Thongsuksai P, Ratanalert S. Primary spinal melanoma: presentation of a case with prolonged course. Chula Med J 1998 Nov;42(11): 1027-33**

*A primary malignant melanoma of the spinal cord in a 26-year-old man is reported. The patient presented eight months prior to surgery with insidious but progressive neurodeficits. A black intramedullary exophytic growth at T6 was partially removed. The tumor recurred four and a half years later. The patient expired ten months after the second removal. The diagnosis of primary melanoma of the spinal cord was made after a pigmented tumor outside the CNS had been ruled out. This case is unusual in that the course of disease was strikingly long. Literature about primary melanotic tumors of the spinal cord, the relatively benign "melanocytoma" and the malignant melanoma, was reviewed. Long term survival was reported in few cases of primary spinal melanoma. On the other hand, in exceptional cases of melanocytoma, signs of aggressive behavior were seen. Questions are cited regarding these conflicting findings.*

**Key words :** Primary spinal melanoma, Melanocytoma, Central nervous system melanoma.

Reprint request : Thongsuksai P, Department of Pathology, Prince of Songkla University,  
Hat-Yai, Songkhla, Songkla 90112, Thailand.

Received for publication. August 15, 1998.

\* Department of Pathology, Prince of Songkla University

\*\*Department of Surgery, Prince of Songkla University

ปารมี ทองสุกใส, สวงวนสิน รัตนเลิศ, มะเร็งปฐมภูมิ melanoma ที่ไขสันหลัง : รายงานผู้ป่วย 1 ราย ซึ่งมีการดำเนินโรคราย. จุฬาลงกรณ์เวชสาร 2541 พ.ย;42(11): 1027-33

ผู้เขียนและคณะ ได้รายงานมะเร็งปฐมภูมิชนิด melanoma ที่ไขสันหลัง ในชายไทยอายุ 26 ปี ผู้ป่วยมีอาการความผิดปกติทางระบบประสาทอย่างค่อยเป็นค่อยไปเป็นเวลา 8 เดือนก่อนเข้ารับการผ่าตัด ผลการผ่าตัดพบก้อนเนื้อสีดำในตำแหน่ง intramedullary ที่ระดับ T6 และสามารถเอาก้อนเนื้อออกได้บางส่วน หลังจากนั้น 4 ปีครึ่ง ผู้ป่วยกลับมีอาการอีกและต้องเข้ารับการผ่าตัดเป็นครั้งที่สอง ผู้ป่วยเสียชีวิตหลังจากนั้นต่อมาอีก 10 เดือน การวินิจฉัยทางพยาธิวิทยาว่าเป็น มะเร็งปฐมภูมิ melanoma ทำหลังจากได้ค้นหาโรคที่ส่วนอื่นของร่างกายแล้ว ผู้ป่วยรายนี้เป็นรายที่แปลกไปในข้อที่ว่ามีชีวิตอยู่ได้ค่อนข้างยาวนานเกือบ 5 ปี การทบทวนวรรณกรรมเกี่ยวกับ melanotic tumor ที่ไขสันหลัง ทั้งที่เป็นเนื้องอกธรรมดาคือ melanocytoma และ เนื้องอกร้าย melanoma พบว่าในบางรายของ melanoma ที่ไขสันหลังมีชีวิตยืนยาว เช่นเดียวกับในผู้ป่วยรายนี้ และในทางกลับกัน melanocytoma บางราย ก็มีพฤติกรรมที่ค่อนข้างร้ายแรงทำให้เกิดคำถามบางประการเกี่ยวกับการดำเนินโรคที่ซ้ำซ้อนกันนี้

Melanocytes are known to normally exist in the human meninges. In the spinal cord, pigmentation is greatest in the anterior median fissure and between the anterior and posterior nerve roots.<sup>(1, 2)</sup> Melanotic neoplasms in the central nervous system can be primary or metastatic. Metastatic melanoma is far more common while primary melanotic tumors in this site are rare.

Primary melanotic neoplasms derived from meningeal melanocytes are present in two extremes, as benign melanocytoma and malignant melanoma. There were, however cases with overlapping features. Some cases of primary spinal melanoma, survived for a few years.<sup>(2, 3)</sup> On the other hand, there were a few cases in which pathological features were compatible with melanocytoma, but recurrent tumors appeared malignant or even metastasized.<sup>(4-6)</sup> Several questions and hypotheses have arisen from these findings for example: are these two extremes the same entity with a range of severity?

We report a case of primary melanotic tumor in the spinal cord. It was histologically compatible with melanoma. The case was unusual in that the course of the disease was quite long. Literature about melanocytoma and melanoma of the spinal cord is reviewed.

### Case report

A 26-year-old man was in good health until he experienced an insidious onset of back pain at the thoracic level about approximately 8 months before admission. Two months after the onset the pain increased in severity. The patient reported a "pins-and-needles" sensation in his back followed by numbness and progressive weakness in both legs. In the month prior to admission, he experienced difficulty in urination

as well as some dribbling.

General physical examination on admission showed nothing abnormal. Neurological examination revealed spastic paraparesis grade II/V. Hypalgesia was found up to the T7 level. Sphincter tone was lost when the bladder was full. Complete blood count and blood chemistry were normal. Plain thoracic vertebral spine films were normal. A myelogram showed a complete block at T6 level.

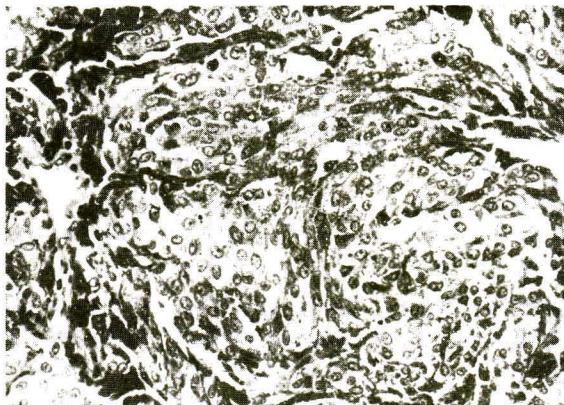
During the total laminectomy of T5 to T7, an oval shaped exophytic growth of intramedullary mass was found in the left ventrolateral section. It was black and friable. Also found were multiple black spots on the arachnoid and spinal cord. The intramedullary border of the tumor was ill defined. Subtotal removal of the tumor was performed and malignant melanoma was histologically diagnosed. The patient was seen by a dermatologist, ophthalmologist and general surgeon who failed to detect the pigmented lesions elsewhere. The postoperative course of treatment was uneventful with improvement of neurological signs. The patient was able to walk one month after surgery but was then lost to follow up.

Fifty-three months later, the same symptoms and signs recurred and progressed to severe paraparesis. After a myelogram showing complete block at the T7 level, a second operation was performed. There were diffuse black stains on the arachnoidal layer with multiple black spots of the spinal cord. An exophytic growth at T6-7 was partially removed. The patient then received radiation therapy. He recovered sufficiently to walk with crutches three months after the treatment but hypalgesia below the T7 persisted. The patient was again lost to follow up. A letter was sent to ask the patient's status and the reply stated that he had died at

home about ten months after the second operation. Therefore, the total course was 5 years after diagnosis or 6 years after the onset of symptoms.

### Pathologic results

Sections were routinely processed and stained with hematoxylin and eosin, Fontana-Masson for melanin and Perl's Prussian blue reaction for iron. Histologic features of the tumors from both the first and second operation were similar. The tumor had an irregular border without capsules. The tumor cells infiltrated the connective tissue surrounding nerves. The cells were heavily pigmented, had a uniform plump spindle to epithelioid shape, and were arranged irregularly in groups, fascicles and large sheets (Fig. 1). The nuclei, varying slightly in size, were ovoid with small to moderately large nucleoli. Pleomorphism, mitosis and necrosis were not apparent. There were no well-formed whorles. Psammoma bodies were not seen.



**Figure 1.** Photomicrograph demonstrates groups of relatively uniform plump spindle shaped cells with cytoplasmic fine pigmentation. Hematoxylin and eosin, original magnification X 600.

The special stain for melanin was positive, whereas that for iron was negative. The overall histologic finding was that of melanoma. However, immunohistochemical study was done to confirm and differentiate from other spinal tumors that may contain melanin pigments namely pigmented schwannoma and meningioma. The tumor showed strong positivity with S-100 protein but negative for epithelial membrane antigen. However, HMB-45, a specific marker for melanoma was not available in our laboratory.

### Discussion

The central nervous system is known to be among the most common metastatic sites of cutaneous melanoma. Malignant melanoma comprise about 12-16% of all tumors metastasized to the CNS.<sup>(7)</sup> In contrast, primary melanocytic tumors, especially in the spinal cord are rare. To date, primary melanocytic tumors of the spinal cord are found to occur in two forms; the relatively benign tumor called "melanocytoma" and the malignant melanoma. Though accepted as separate entities, some cases in each group have overlapping clinico-pathologic features.

The relatively benign melanocytic tumor was first described by Ray & Foot in 1940.<sup>(8)</sup> The authors reported two cases, one spinal and one cranial, in which gross and microscopic features were strikingly similar to a meningioma except they had pigmentation. Hence, the term "melanotic meningioma" was used. In 1972, the melanocytic origin of this tumor was ultrastructurally demonstrated by Limas and Tio.<sup>(9)</sup> Melanocytoma is the terminology that has been used since their report.

About 17 cases of spinal melanocytoma have been reported in the literature.<sup>(10-14)</sup> The age of the patients ranged from 15 to 71 years with a median age

of 43 years. The patients usually presented with a few years history of progressive neurological deficits indicating a slow growing mass. The duration of symptoms before diagnosis ranged from 4 months to 6 years. The spinal tumors were evenly distributed along spinal segments, usually attached to the dural sheath of the spinal nerve roots and presented in both intradural and extradural compartments. Nearly all of the tumors reported were solitary, well circumscribed or encapsulated. One exceptional case had a cervical tumor with several dorsal nodules.<sup>(12)</sup> The histology showed bland cellular features in contrast with malignant melanoma. The cells were usually spindle or fusiform with oval nuclei and small nucleoli. Mitoses and necrosis were absent or minimal. The presence of some mitoses and local infiltration of dura and adjacent nerve fascicles were seen in some cases.<sup>(4-6)</sup> Most patients with spinal melanocytoma survived longer than 3 years. The survival period of the case who had multiple tumor lesions was not stated. The tumors recurred in 3 cases and the recurrent lesions showed aggressive features.

On the other hand, the clinicopathologic features of primary melanoma of the CNS are well known. Of over 300 cases reported worldwide, there were fewer than 70 cases of primary spinal melanomas.<sup>(15)</sup> Most of these cases had the clinical and pathologic features of malignant disease regarding histologic features and short survival. The tumor was often located at the mid-thoracic, intramedullary, extramedullary or leptomeningeal region. A few cases were extradural tumors. The tumor mass was sometimes solitary but was usually multiple or diffuse. Microscopically, cytological signs of malignancy, mitosis and invasion to adjacent nerve tissue confirmed the diagnosis of

malignant melanoma. To confirm the primary nature of the disease, searching for pigmented tumors elsewhere is required prior to final diagnosis.

The majority of primary spinal melanoma cases had survival times of less than one year. In many cases, strikingly prolonged survival was found when compared with metastatic melanoma. The survival time of most cases with metastatic melanoma to the brain and spinal cord, regardless of treatment, was usually only a few months.<sup>(2,16-18)</sup> Of 25 cases of primary spinal melanoma reviewed by Hirano, et al, the survival times ranged from 1 day to 15 months.<sup>(19)</sup> Four cases reviewed by Hayward had survival time ranged from 6 months to 5.5 year.<sup>(2)</sup> Five cases reviewed by Larson et al had a survival time ranging from 2.5-13 years.<sup>(20)</sup> Skarli, et al, who reported a patient who survived 8 years, linked some characteristics, namely solitary lesion and low mitotic activity of the tumor, to the favorable prognosis.<sup>(3)</sup> Our case seemed to support this observation for the tumor cells were quite uniform with low mitotic activity.

Evidence indicates that these two tumors have overlapping clinical and pathological signs. In our case, the architectural infiltrative pattern supports the diagnosis of melanoma. However, the tumor cells had quite bland nuclei with small nucleoli without mitoses or necrosis. These features may be responsible for the prolonged course of disease. These findings raise some questions. Are these distinctive tumors or just one entity with a continuum of clinicopathologic features and prognoses? What are clinicopathologic features that can help distinguishing the subgroup of patients who will benefit the treatment? Does melanocytoma really exist or should it be abandoned? Analysis from larger series with complete follow-up

information would shed some light on these questions.

The differential diagnosis of leptomeningeal pigmented tumor other than melanocytoma and melanoma include pigmented schwannoma and pigmented meningioma.<sup>(21)</sup> Pigmented meningioma has long been confused with melanocytoma and in several reported cases were later proved to be melanocytoma. Grossly, the pial and subpial localization of the tumor and evidence of focal infiltration distinguishes a melanoma from the two other types. Usually the architectural pattern and cellular morphology are quite distinctive, but in contentious cases, electron microscopy may be essential. Immunohistochemistry is only of limited assistance. Melanoma and schwannoma are S-100 positive with negative staining for epithelial membrane antigen, whereas meningioma are opposite.<sup>(22)</sup> Though not melanoma specific, the HMB-stain is usually positive.

Recognizing the existence of melanocytoma or the less aggressive malignant melanoma is important for disease management. Usually, the diagnosis of meningeal melanocytoma is not made before histologic examination. This might be due to its rarity and recent recognition. Even with a histologic diagnosis, especially in frozen tissue, melanoma may be initially diagnosed.<sup>(7, 11, 12)</sup> Therefore, it is recommended that when a circumscribed, pigmented spinal tumor is encountered in the operative field, it should be excised as completely as possible. A recurrent tumor after incomplete removal should be treated. Studies of prognostic features of malignant melanoma of the spinal cord are needed for better prognostic prediction and for appropriate management.

## Conclusions

Primary melanocytic neoplasms in the spinal

cord include the relatively benign tumor called melanocytoma and the malignant melanoma. Cases of primary malignant melanoma of the spinal cord generally have a survival time of less than one year compared to a few years for cases of melanocytoma. Lengthy duration of symptoms and solitary circumscribed tumors and bland histologic features were found in most reported cases of melanocytoma and the opposite for melanoma. However, there were cases of overlapping features. Some cases of melanocytoma showed signs of aggressive behavior whereas many cases of spinal melanoma had a post-operative course of more than 5 years. Recognizing these favorable cases are important for disease management. Analysis of a large series with complete follow-up data will give more information on prognostic prediction of the disease.

## References

1. Gibson JB, Burrows D, Weirs WP. Primary melanoma of the meninges. *J Pathol Bacteriol* 1957 Oct; 74(2): 419-38
2. Hayward RD. Malignant melanoma and the central nervous system. A guide for classification base on clinical finding. *J Neurol Neurosurg Psychiatry* 1976 Jun; 39(6): 526-30
3. Skarli SO, Wolf AL, Kristt DA, Numaguchi Y. Melanoma arising in a cervical spinal nerve root: report of a case with a benign course and malignant features. *Neurosurgery* 1994 Mar; 34(3): 533-7
4. Barth A, Pizzolato GP, Berney J. Intramedullary meningeal melanocytoma. *Neurochirurgie* 1993; 39(3): 188-94
5. Cordoba A, Tunon T, Vazquez JJ. Meningeal melanocytoma. Presentation of a case and review

- of the literature. Arch Neurobiol Madr 1989 Mar-Apr; 52(2):93-9
6. Steinberg JM, Gillespie JJ, Mackay B, Benjamin RS, Leavens LE. Meningeal melanocytoma with invasion of the thoracic spinal cord. Case report. JNeurosurg 1978 May; 48(5): 818-24
7. Bakody JT, Hazard JB, Gardner WJ. Pigmented tumor of the central nervous system. Cleve Clin Q 1950 Apr; 17: 89-101
8. Ray BS, Foot NC. Primary melanotic tumors of meninges: resemblance to meningiomas, report of two cases in which operation was performed. ArchNeurol Psychiatry 1940 Jul; 44: 104-17
9. Limas C, Tio FO. Meningeal melanocytoma ("melanotic meningioma"). Its melanocytic origin as revealed by electron microscopy. Cancer 1972 Nov; 30(5): 1286-94
10. Crouzet J, Richard S, Pillet G, Muckensturm B, Srou A, Pradat P. Meningeal melanocytoma or multiple pigmented meningioma of the spinal canal. Report of a case. Review of the literature. Rev Rhum Mal Osteoartic 1992 Nov; 59(11): 738-43
11. Litofsky NS, Zee CS, Breeze RE, Chandrasoma PT. Meningeal melanocytoma : diagnostic criteria for a rare lesion. Neurosurgery 1992 Nov; 31(5): 945-8
12. Park SH, Park HR, Ko Y. Spinal meningeal Melanocytoma. J Korean Med Sci 1992 Dec; 7(4): 364-8
13. Ruelle A, Tunesi G, Andrioli G. Spinal meningeal melanocytoma. Case report and analysis of diagnostic criteria, Neurosurg Rev 1996; 19(1): 39-42
14. Tatagiba M, Boker DK, Brandis A, Samii M, Ostertag H, Babu R. Meningeal melanocytoma of the C8 nerve root: case report. Neurosurgery 1992 Nov; 31(5): 958-61
15. Savitz MH, Anderson PJ. Primary melanoma of the leptomeninges : a review. Mt Sinai J Med 1974 Nov-Dec; 41(6): 774-91.
16. Connolly ES Jr, Winfree CJ, McCormick PC, Cruz M, Stein BM. Intramedullary spinal cord metastasis : report of three cases and review of the literature. Surg Neurol 1996 Oct; 46(4): 329-38
17. Donaldson WF 3d, Peppelman WC Jr, Yaw KM. Symptomatic metastatic malignant melanoma to the spine. J Spinal Disord 1993 Aug; 6(4): 360-3
18. Retsas S, Gershuny AR. Central nervous system involvement in malignant melanoma. Cancer 1988 May 1; 61(9): 1926-34
19. Hirano A, Carton CA. Primary malignant melanoma of the spinal cord. JNeurosurg 1960 Nov; 17: 935-44
20. Larson TC 3d, Houser OW, Onofrio BM, Piepgras DG. Primary spinal melanoma. J Neurosurg 1987 Jan; 66(1): 47-9
21. Russel DS, Rubinstein LJ. Pathology of tumors of the nervous system 5<sup>th</sup> ed. London : Butler & Tanner Ltd, 1989: 797
22. Burger PC and Scheithauer BW. Atlas of tumor pathology. Tumor of the central nervous system. Washington, D.C. Armed Forces Institute of Pathology, 1994 : 345-8