

## Wilson's disease with hepatitis C virus infection, a case report

Viroj Wiwanitkit\*

**Wiwanitkit V. Wilson's disease with hepatitis C virus infection. Chula Med J 2002 Sep; 46(9): 747 - 51**

*This article reports the case of a 35-year old female patient referred to the hospital with liver failure. This patient was diagnosed to have Wilson's disease due to the criteria: 1) serum ceruloplasmin < 20 mg %, and 2) KF rings present upon ocular examination. Upon further investigation, this patient was revealed to have transfusion – causes hepatitis C virus infection, apparently a cause of her liver disease. Screening of the patient's family was also performed and is presented as a pedigree. This case is a good example of familial Wilson's disease.*

**Key words:** *Wilson's disease, Hepatitis C.*

Reprint request: Wiwanitkit V. Department of Laboratory Medicine, Faculty of Medicine,  
Chulalongkorn University, Bangkok 10330, Thailand.

Received for publication. May 20, 2002.

วารสาร วชิรเวช. โรคของวิลสันร่วมกับการติดเชื้อตับอักเสบชนิดซี. จุฬาลงกรณ์เวชสาร 2545  
ก.ย; 46(9): 747 - 51

ได้รายงานกรณีศึกษาผู้ป่วยหญิงอายุ 35 ปี ได้รับการส่งตัวมารักษาด้วยปัญหาตับวาย ผู้ป่วยได้รับการวินิจฉัยว่าเป็นโรควิลสันด้วยเกณฑ์ดังต่อไปนี้ 1. ระดับซีรูโรพลาสมีนในเลือดน้อยกว่า 20 mg % และ 2. ตรวจพบ KF จากการตรวจตา จากการตรวจเพิ่มเติมพบผู้ป่วยติดเชื้อไวรัสตับอักเสบนชนิดซี เนื่องจากการได้รับเลือดและเชื่อว่าเป็นสาเหตุร่วมของอาการโรคตับในผู้ป่วยรายนี้ นอกจากนี้ยังได้ทำการตรวจคัดกรองโรคของวิลสันในสมาชิกในครอบครัวของผู้ป่วยและได้แสดงในรูปแบบพงศาวลี รายงานนี้เป็นกรณีศึกษาที่ดีสำหรับครอบครัวที่มีพันธุกรรมของโรควิลสันครอบครัวหนึ่ง

คำสำคัญ: โรคของวิลสัน, ไวรัสตับอักเสบนชนิดซี

Wilson's disease (or hepatolenticular degeneration) is an autosomal recessive disorder with an incidence about 1:30,000 – 1:1,000,000.<sup>(1)</sup> Wilson's disease is a rare autosomal recessive inherited disorder of copper metabolism. Hepatic excretion of copper is impaired due to mutation of the gene for a copper-transporting adenosine triphosphatase, ATP7B.

The abnormal of copper metabolism in this disorder results in accumulation of copper in the brain, liver and other organs. Copper accumulation in liver, brain, and other tissues may cause a wide spectrum of hepatic, neuropsychiatric, and other clinical manifestations. The diagnosis may be supported by measurement of serum ceruloplasmin, urinary copper excretion, and hepatic copper content as well as by detection of Kayser-Fleischer rings. Several treatments are available to increase urinary excretion and decrease intestinal absorption of copper.<sup>(1-4)</sup>

In this article, a case of Wilson's disease that presented with liver failure concomitant with hepatitis C virus infection is reported. The presence of disorder in the patients family is also described.

### Case Report

A 35 year old female patient was referred to the hospital from Samutsongkram province hospital with the problems of liver failure and cirrhosis. Upon physical examination; the patient showed with severe jaundice. Signs of chronic liver disease such as spider nevi and palmar erythema were detected, and ascites could also be observed. During ocular examination, the Kayser Fleischer (KF) rings was demonstrated.

At the referred hospital, a complete blood count revealed hemolytic anemia with Coomb's test

negative (Reticulocyte count raised to 4 % NRBC raised to 2 %). Serum bilirubin was raised to 50 mg %. Serum ceruloplasmin was 1.3 mg %. Other chemistry tests were within normal limits. Serum Anti hepatitis C was positive. From paracentesis, the ascites fluid was negative for organisms. The patient refused a liver biopsy for copper study. This patient died 1 week after admission. No autopsy was performed.

This patient was diagnosed to have Wilson's disease due to the criteria: 1) serum ceruloplasmin < 20 mg %, and 2) KF rings from ocular examination. An additional diagnosis of hepatitis C infection was made.

This patient reported a history of chronic anemia treated by blood transfusion at provincial hospital about 10 times. The last transfusion had been one month previously. The family history of this patient was also reviewed. The pedigree of this family is presented in Figure 1. One of the patients elder sisters had died of Wilson's disease at the age of 21 years

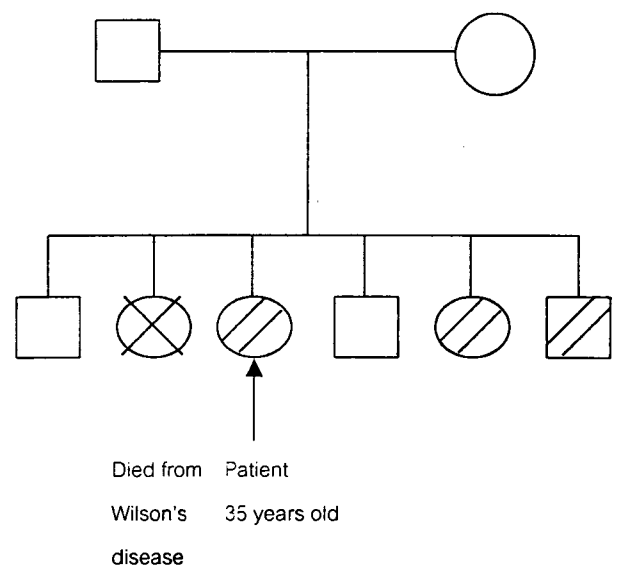


Figure 1. Pedigree of patient's family.

old, 15 year ago. All living cousins in the family were evaluated for serum ceruloplasmin level and received eye examinations. The patient's parents were normal by these examinations. One of the patient's brothers and one sister were also diagnosed with Wilson's disease at a pre-symptomatic stage. The patient's family was suggested to obtain a definite genetic diagnosis.

### Discussion

Wilson's disease is a rare disease in Thailand. This article reports a familial case. In the present day, this disease has been proved to be the autosomal recessive disease and the mutation of chromosome 13 (band q 14.3) can be detected.<sup>(2)</sup>

Wilson's disease is an inherited disorder of copper metabolism resulting in pathological accumulation of copper in many organs and tissues. The Wilson disease gene is localized on human chromosome 13 and codes for a copper transporting P-type ATPase, -ATP7B. About one hundred mutations occurring throughout the whole gene have been documented so far. The most common is the His 1069Gln point mutation.

In the patient with Wilson's disease, absorption of copper from the proximal small intestine is normal, but excretion of copper into the bile decreases due to the lack of ceruloplasmin. Therefore, excess copper accumulates in the organs, especially the liver and brain. With this process, degeneration of the liver (liver cirrhosis) and brain (shown by tremor) can be detected. Eye signs such as a KF rings and a sunflower cataract are also pathognomonic manifestations of this disease and are suggestive of comcurrent brain abnormalities.<sup>(3)</sup> This disorder has

a long-term course; the symptoms will become over at the age of 15 to 40 years.<sup>(4)</sup>

Wilson's disease may present under a variety of clinical conditions, the most common being liver disease (ranging from acute hepatitis, fulminant hepatic failure, chronic hepatitis, and cirrhosis), haemolytic anaemia, and neuropsychiatric disturbances. The diagnosis of Wilson's disease is usually made on the basis of clinical findings (Kayser-Fleischer rings, typical neurologic symptoms) and laboratory abnormalities (low serum caeruloplasmin, increased hepatic copper content). Diagnosis of Wilson's disease can be made using the criteria: 1) serum ceruloplasmin < 20 mg %, and 2) KF rings from eye examination or 2) hepatic copper > 250 microgram/gram dry weight of liver.<sup>(3)</sup> Molecular genetic testing is now the standard for testing asymptomatic siblings. Diagnosis in patients presenting with liver diseases is difficult and requires a combination of various laboratory parameters. Lifelong treatment with chelating agents (d-penicillamine, trientine) or with zinc is usually sufficient to stabilize the patient and to achieve clinical remission in most. Patients with advanced liver disease benefit from orthotopic liver transplantation.

In this case, the patient presented with acute fulminant hepatitis and Coomb's negative hemolytic anemia. With this presentation, Wilson's disease must be one of the differential diagnoses. Among various hepatic manifestations of Wilson's disease, fulminant hepatic failure is the most uncommon entity and requires a detailed clinicopathological analysis for correct diagnosis. Establishing a diagnosis of fulminant Wilson's disease can be difficult because Kayser-Fleischer rings may not be present and

parameters of copper metabolism, including serum and urinary copper, and serum ceruloplasmin levels are neither specific nor diagnostic. The ALP – bilirubin ratio of less than 2.0 provided good in identifying fulminant hepatic failure caused by Wilson's disease from other types of fulminant hepatic failure. <sup>(5)</sup>

In this case the ALP-bilirubin ration exceed 2.0. Furthermore , liver failure in Wilson's disease is most common in patient's at an age below age 20 year, <sup>(3,5)</sup> this case is not common presentation of this disease. The fulminant hepatitis in this case is believed to due to aggravation by concomitant hepatitis C virus infection. <sup>(5)</sup>

Interestingly, this patient had a history of frequent blood transfusion due to symptoms of anemia. The hepatitis C infection in this patient is believed to have been an unwanted complication of blood transfusion and may have been an aggravating factor for the liver failure. Safety of blood products for the health service is an important topic in the present day.

In this case, the strongly familial nature of this disorders can be demonstrated and this concords with previous reports that the incidence in the family of the proband is high, about 30 to 300 times that of the general population. <sup>(1)</sup> This report is a good example of familial Wilson's disease.

Concerning this family, members with a pre-symptom stage of Wilson's disease should receive prophylactic therapy; a Zinc sulfate regimen is recommended. Considering the nutritional aspect, control of high copper food intake is necessary. This family is at Samutsongkram province, a seashore province in Thailand, therefore, avoidance of seafood, especially crab and oyster, is recommended.

### References

1. Brewer GJ, Yuzbasiyan – Gurkan V. Wilson disease. *Medicine* 1992 May; 71(3):139 - 64
2. Kulmar A, Reily CA. Inherited liver disease in adults. *West J Med* 1995 Oct;163(4):382 - 6
3. Landschulz W. Inherited metabolic diseases. In: Isselbacher KJ, Braunwald E, Wilson ? JD, Matin JB, Fauci AS, Kasper DL, eds. *Harrison's Principle of Internal Medicine*. 13<sup>th</sup> ed. Singapore: Mc Graw-Hill, 1994.
4. Yarze JC, Martinb P, Munoz SJH, Friedman LS. Wilson's disease: current status. *Am J Med* 1992 Jun; 92(6): 643 - 54
5. Berman DH, Leventhal RI, Gravalier JS, Cadoff EM, Van Thiel DH. Clinical differentiation of fulminant Wilsonian hepatitis from other causes of hepatic failure. *Gastroenterology* 1991 Apr; 100(4): 1129 - 34