

Penile Prosthesis : Option for treatment of ED in Thailand

Apichat Kongkanand*

Kavirach Tantiwongse*

Kongkanand A, Tantiwongse K. Penile Prosthesis : Option for treatment of ED in Thailand.
Chula Med J 2002 Sep; 46(9): 739 - 46

- Objective** : *To review the current status of the penile prosthesis implantation in Thai men who were treated for erectile dysfunction (ED) long before other treatments were available. Penile prosthesis is one of the option for the treatment of ED.*
- Setting** : *King Chulalongkorn Memorial Hospital, Department of Surgery, Division of Urology*
- Subjects** : *108 cases in the past 10 year.*
- Material and Method** : *96 cases of the total 108 are Thai and review the result of mechanical failure, infected cases, redo and leakage of Cylinder, how patients choose the prosthesis type.*
- Results** : *Patients show satisfaction to penile prosthesis, average size of penile length for Thai men is 16.5 cm.*
- *Prosthesis length from 12 to 21 cm*
 - *3 wounded infection, 5 cylinder leaks*
 - *Pain at tolerable degree*
 - *Decision to choose types depend on financial resource. (However, many seemed to be more satisfied with inflatable type.)*
 - *Equal number of patients with malleable and inflatable ED patients were reviewed.*

Conclusion : *Penile prosthesis is excellence, durable and still remains one of the options for ED treatment, The operation is relatively safe and short, suitable for patients of all ages.*

Key words : *Thai, Penile prosthesis.*

Reprint request : Kongkanand A, Department of Surgery, Faculty of Medicine, Chulalongkorn University, Bangkok 10330, Thailand.

Received for publication. June 15, 2002.

**อภิชาติ กงกะนันท์, กวีรัช ตันติวงศ์. แกนอวัยวะเพศเทียมอีกทางเลือกในการรักษาโรคอีดี้.
จุฬาลงกรณ์เวชสาร 2545 ก.ย;46(9): 739 - 46**

วัตถุประสงค์ : การทำผ่าตัด Penile Prosthesis หรือผ่าตัดฝังแกนอวัยวะเพศเทียมในการแก้ไขโรคหย่อนสมรรถภาพทางเพศนั้นมีมานาน บทความนี้เพื่อดูการรักษาแกนอวัยวะเพศเทียมในคนไทยซึ่งทำในระยะเวลาที่ผ่านมาว่ามีผลดี ผลเสียประการใด

สถานที่ : โรงพยาบาลจุฬาลงกรณ์ ภาควิชาศัลยศาสตร์

จำนวนผู้ป่วย : 108 รายใน 10 ปี

วิธีการ : ผู้ป่วยที่ได้รับการผ่าตัดจำนวน 108 ราย เป็นคนไทย 96 ราย และตรวจพบว่ามี การติดเชื้อในบางราย ซึ่งต้องทำการผ่าตัดใหม่ และการล้มเหลว มักจะมาจากแกน Cylinder รั่ว นำผลลัพท์ออกมาพิจารณาดูเพื่อนำมาวิเคราะห์

ผลลัพธ์ : มีชายไทย 96 ราย และชาวต่างประเทศ 12 ราย มีแผลติดเชื้อ 3 ราย แกนอวัยวะเพศ ส่วนที่เป็น Cylinder รั่ว 5 ราย หลังจากใช้มาหลายปี มีอาการปวดบ้าง พอทนได้ ไม่มากนัก อวัยวะเพศชายไทยมีความยาว 16.5 เซนติเมตร วัดตามจริง ขณะที่อยู่ในยาสลบหรือให้ยาชาเข้าไขสันหลัง มีจำนวนผู้ป่วยเลือกชนิดที่มีปั๊ม (inflatable) และ ดัดได้ (malleable) พอ ๆ กัน ปัจจัยที่เลือกตัดสินใจชนิดของแกน นับว่ามาจากฐานะ การเงินด้วย

สรุป : นับว่าแกนอวัยวะเพศชายเป็นอีกหนึ่งทางเลือกของการรักษาโรคอีดี้ หรือหย่อนสมรรถภาพทางเพศ

คำสำคัญ : Thai, Penile Prosthesis.

Treatment of Erectile Dysfunction began many years ago. Since then, there has been a more liberal attitude towards sexuality with a better understanding about sex through availability of sex education. The term impotency has been changed to Erectile Dysfunction. A layman has also changed his attitude, accepting the fact and seeks for ways to cure the disease.

The history of penile prosthesis dated back even longer,⁽¹⁾ to 1936 Bagaras⁽²⁾ and in 1943 Frunkin⁽³⁾ created penis by implanting resected ribs into the dorsal part of the penis. Later there were many developments in creating rigidity for penis through mechanical technology.

One of the pilot projects in penile prosthesis was started in 1975, a small rigid carrion prosthesis⁽⁴⁾ without flexibility and in 1977 Finney⁽⁵⁾ introduced the semi-rigid model, Flexirod. Then AMS 600 was available. It was made of a silicone rod of semirigidity and malleability. At the same time it was inflatable a prosthesis,^(6,7) neat, concealed and comfortable, Its design was to satisfy ED patient who could squeeze a pump, hidden underneath the skin of the scrotal sac, ready to erect the penis at will, and it could also be deflated instantly by the pump. The development of penile prosthesis was between 1973 – 1983, then it was a breakthrough: AMS CX, a new controlled expansion cylinder. It operated with little complications and it is currently in use.

A self-contained device,⁽¹⁾ Hydroflex system, is also popular among Thai patients. However, since the company changed to a new module, dynaflex, the prosthesis seemed to be too large to fit in with the proximal portion of the CRUS. Currently, there are only 2 models available for Thai patients at present.

Material and Method

A review of penile implantation at King Chulalongkorn Memorial Hospital and two other private hospitals revealed interesting data.

96 Thai males and 12 foreigners underwent surgical penile implantations during the past 10 years. The first penile prosthesis was done in July 5, 1989, with AMS 600 malleable prosthesis. It was used in patients with bladder cancer who had undergone cystectomy and become ED. Until now the prosthesis is still in use. All the cases were done under general anesthesia or spinal block, except for one which was done under local anesthesia by nerve-blocking at the penile base.

Age of Patients

The youngest one was diabetic at 27 years old and the oldest was 78. Two were elderly with good physical and mental faculties. The average age was 56.6 years.

Table 1. Underlining or risk factors in ED cases.

Diabetic	31 cases
Radical Surgery	11 cases
Atherosclerotic, Hypertension	44 cases
Peyronie's Disease	7 cases
Trauma	3 cases

Result

Corpora Length

The length of corpora was measured by standard Furlow⁽⁸⁾ (see picture 1-3) device which was originally designed to measure the corpora at the proximal and distal end and the combination of the

results is the total length of an individual corpora. In the malleable case we subtracted one cm in each person before putting the prosthesis inside the corpora

for technical purposes.

The shortest penis was 12 cm, and the longest, 21 cm.

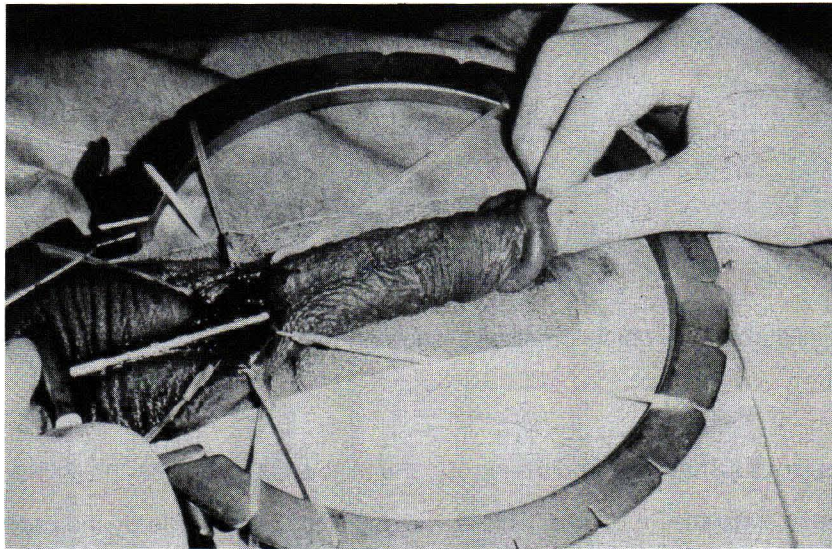


Figure 1. Measurement of penile length from tip of the penis to the mid portion at the corporotomy incision + proximal part to the CRUS done by furrow device.

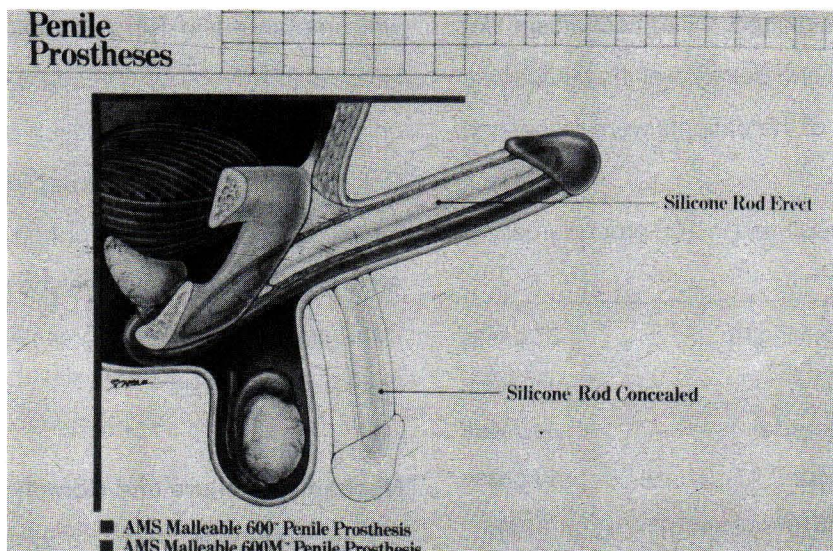


Figure 2. Malleable type of penile prosthesis locates in the corpora cavernosum showing the positioning.

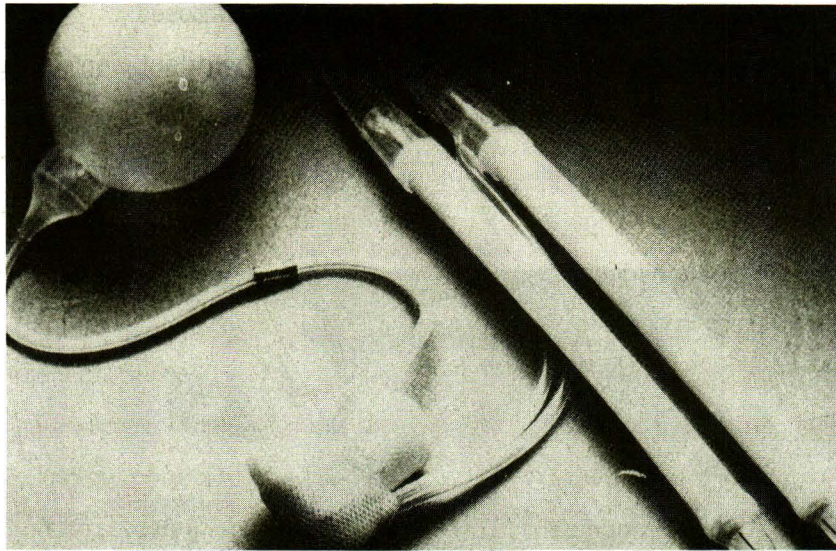


Figure 3. Picture of inflatable type penile prosthesis, showing reservoir, inflate – deflate pump and cylinders.

The average size of a Thai male penis is 16.8 cm., in length; this was never known before. This is the actual average size of the corpora length in Thai males because previous measurements were only the length from the base of the penis to the glands.

It should be noted that sessions were held with patients, wherein doctors explained to them in details about how the prosthesis worked and where the device should be placed. The mechanism that controlled the inflation and deflation of the device was also explained. Most of the patients were fascinated

Table 2. The prosthesis used in 106 procedures.

AMS 600 (malleable, semirigid)	37 cases
CX 700 inflatable (P.P)	9 cases
CXM inflatable (for Asian size)	36 cases
Hydroflex (self-contained)	10 cases
Dynaflex (self-contained, newer version)	5 cases
Alfa 1 narrow base (small size for Asian male)- (from Mentor Company) since 1996	9 cases

with the CXM 700 or the 3-piece equipment, but decisions were made by the patients, mostly based on their financial means.

The AMX 600 malleable prosthesis is so far the most popular and cheapest among the Thais. It is suitable to the patient and his pocket.

The CXM inflatable prosthesis is popular next to AMS 600, as it is affordable. The first CXM 700 was implanted in King Chulalongkorn Memorial Hospital in November 1989, and was demonstrated on a live surgery presentation at the International College of Surgeons Meeting in November 1989, 5 cases of Dynaflex were put on Caucasian males. Alfa 1 Narrow-base is the prosthesis made by Mentor Company for Asian males or small people since they have a narrow base.

Mechanical Failure and Complications

There were 2 cases of joint disruptions (Quick Connect) in early cases of inflatable prosthesis and the flex or curve joint has never been used since then.

Table 3. Failure and complications.

Erosion to the urethra	1 case
Wound infection	3 cases
Cylinder failure	5 cases
Penile Pain	(tolerable degree, not severe pain)

Cylinder leakage was found after 5 years in each of the individuals; the incidence had to be revised.

Discussion

The treatment of ED by penile implantation is one of the options available for ED diabetic patients who do not respond to oral medication, but who are also not keen on self-injection. Young male diabetics with ED are therefore good candidates for penile implant.⁽⁹⁾

With its short surgical time, limited in one hour, and short period of hospitalization, last only 2-3 days, the operation cost should decrease in the next few years. Patients could use the prosthesis for sexual intercourse in 4-6 weeks,⁽¹⁰⁻¹²⁾ and return for reexamination and advice, if necessary, in a few weeks. The penile prosthesis is also one of the best options in treating Peyronie's Disease as Steven Wilson^(13,14) using the molding technique with a vein or synthetic graft.

Once patients develop ED or become less rigidity prosthesis should be considered at the same time as surgery and young⁽⁷⁾ diabetic patients are good candidates. They are about one-third of the series who are recommended for penile implant. The goal is direct therapy or whatever patients like and they could choose the treatment which was open for

them and it was not necessary to go from one step to the other. In our series, however, there were 102 procedures for 94 patients, because some patients needed to have revisions and repairs. The incidences was small in number as described, and the results were excellent.

Conclusion

These reviews represent Penile Implants in Thailand which were done mostly in King Chulalongkorn Memorial Hospital and two other nearby private hospitals. The results showed alternative treatments of ED by penile prosthesis. The cost of management was high for Thai standards which showed that malleable cases were mostly chosen. However, the treatment was justified for those who could afford it, since they were not reimbursable under any health insurance program. The prosthesis was durable and had a life-long service. The original CXM, which was implanted in November 1989, is still working. There have been 3 wound infection reports from inflatable prosthesis cases, which concurred with statistics compared with other kinds of surgery. The longer the surgical time,⁽¹²⁾ the higher is the infection rate; the malleable type requires a shorter operation time. The wound infection cases were from *Staphylococcus aureus* which was probably contaminated from the skin.

References

1. Prosthesis in the treatment of impotency. In: Advance in Urology. Year Book medical publisher, 1988 (1)145 - 71
2. Bogoras N. Uber Die volle plastische Wiederherstellung eines zum Koitus fahigen Penis

- (Penioplastica totalis). Zentralbl Chir 1936; 63(1):1271 - 6
3. Frumkin AP. Reconstruction of the male genitalia. Am Rev Sov Med 1994;2(1):14-21
 4. Small MP, Carrion HM, Gordon JA. Small-Carrion penile prosthesis: New implant for management of impotence. Urology 1975 Apr;5(4): 479 - 86
 5. Finney RR. Prosthesis surgery for impotence, Flexirod. In: Barrette D, Wein A , eds. Controversy in neuro-uro. Churchill Livingstone 1983:509 - 20
 6. Scott FB, Bradley WE, Timm GW. Management of erectile impotence. Use of implantable inflatable prosthesis. Urology 1973 Jul; 2(1): 80 - 2
 7. Furlow WL. Inflatable penile prosthesis: new device for cylinder insertion. Urology 1978 Oct;12(4): 447 - 9
 8. Furlow WL. Surgery for male impotence. In : Glenn JF, ed. Urologic Surgery. 3rd ed. Philadelphia: Lippincott, 1983: 837 - 51
 9. Furlow WL. Diagnosis and treatment of male erectile failure. Diabetes Care 1979 Jan-Feb; 2(1):18 - 25
 10. Wilson SK. Management of penile implant complications. In: Mulcahy JJ, ed. Diagnosis and Management of Male Sexual Dysfunction in Topics in Clinical Urology. 1997 Chapter 14, 231
 11. Mulcahy JJ. Penile Prostheses. In: Lue T, ed. Atlas of Clinical Urology. Current Medicine U.S.A., 1999; 5.1 - 5.13
 12. John J. Mulcahy : Overview of Penile Implants. Diagnosis and Management of Male Sexual Dysfunction in Topics in Clinical Urology (1997), Chapter 13 page 218
 13. Wilson SK, Delk JR 2nd. A new treatment for peyronie's disease modeling the penis over an inflatable penile prosthesis. J Urol 1994 Oct; 152(4):1121 - 3
 14. Carson CC. Penile prosthesis implantation in the treatment of Peyronie's disease. Int J Impot Res 1998 Jun;10(2):125 - 8