

Retained common bile duct stone in mild to moderate gallstone pancreatitis*

Chadin Tharavej**

Teinchai Kongkasem**

Patpong Navicharern**

Suthep Udomsawaengsup**

Suppa-art Pungpapong**

Tharavej C, Kongkasem T, Navicharern P, Udomsawaengsup S, Pungpapong S.
Retained common bile duct stone in mild to moderate gallstone pancreatitis. Chula Med J
2006 Jan; 50(1): 7 - 16

- Background** : *Role of preoperative ERCP in mild to moderate gallstone pancreatitis is poorly defined. Unnecessary ERCP investigations increase procedure related complications and costs.*
- Objective** : *To identify a subgroup of patients with mild to moderate gallstone pancreatitis who are less likely to have retained common bile duct stones.*
- Setting** : *Department of Surgery, Faculty of Medicine, Chulalongkorn University, Bangkok, Thailand*
- Design** : *Retrospective study*
- Patients and Methods** : *Medical records of patients with suspected acute gallstone pancreatitis admitted to King Chulalongkorn Memorial Hospital from 1992-2001 were retrospectively reviewed. The diagnosis of acute gallstone pancreatitis was based on the following criteria: 1) upper abdominal pain and tenderness; 2) serum amylase elevation greater than three times of the normal value; 3) documentation of gallstones by admission ultrasonography or CT scan; and 4) exclusion of other known causes of pancreatitis.*

* Presented in poster format at 15th World Congress of International Association of Surgeons and Gastroenterologists (IASG) in Prague, Czech Republic 7-10 September, 2005

** Department of Surgery, Faculty of Medicine, Chulalongkorn University

Routine laboratory parameters and bile duct imaging studies were reviewed. Patients with Ranson criteria > 2, previous biliary or pancreatic surgery, lack of a success cholangiogram and lack of complete admission laboratory values were excluded from the study. Serum total bilirubin and alkaline phosphatase level greater than normal at admission were considered abnormal. Abnormal imaging studies including common bile duct (CBD) size > 7mm, dilatation of intrahepatic bile duct and identification of CBD stones were noted. Documentation of CBD stones were obtained either by mean of ERCP or intraoperative cholangiogram (IOC).

Results : *Thirty-six patients with mild to moderate gallstone pancreatitis met the criteria. Of the 36 patients, 9 (25 %) had retained CBD stones. There was no serious complication or mortality in these patients during perioperative period. On univariate analysis, male gender, elevated total bilirubin level and abnormal imaging findings were predominant in retained CBD stone group. Patients with abnormal serum total bilirubin and bile duct imaging studies were more likely to have CBD stones than those with normal tests ($p < 0.05$). Using the combination of total bilirubin level and biliary tract imaging studies for prediction of CBD stones, the likelihood of retained CBD stones was 0 %, if these two parameters were normal; whereas, the prevalence of retained CBD stones was 41%, if any of these two parameters was abnormal ($p = 0.005$).*

Conclusion : *Patients with mild to moderate gallstone pancreatitis who have normal levels of serum total bilirubin and normal sonographic findings of CBD on admission are less likely to have retained CBD stone. Preoperative ERCP could be avoided in these cases.*

Keywords : *Gallstone pancreatitis, endoscopic retrograde cholangio-pancreatography, common bile duct stone.*

Reprint request : Tharavej C. Department of Surgery, Faculty of Medicine, Chulalongkorn University, Bangkok 10330, Thailand.

Received for publication. November 9, 2005.

ชฎิล ธาระเวช, เทียนชัย คงเกษม, พัฒน์พงศ์ นาวิเจริญ, สุเทพ อุดมแสวงทรัพย์, ศุภอัฐ ฝั่งพาพงษ์. ภาวะนิ้วตกค้างในท่อน้ำดีร่วมในตับอ่อนอักเสบจากนิ่วในถุงน้ำดีชนิดไม่รุนแรง. จุฬาลงกรณ์เวชสาร 2549 ม.ค; 50(1): 7 - 16

- วัตถุประสงค์** : ต้องการศึกษาค้นคว้าเกี่ยวกับการทำนายภาวะนิ้วตกค้างในท่อน้ำดีร่วมในผู้ป่วยตับอ่อนอักเสบจากนิ่วในถุงน้ำดีชนิดไม่รุนแรง
- สถานที่ทำการศึกษา** : ภาควิชาศัลยศาสตร์ คณะแพทยศาสตร์ จุฬาลงกรณ์มหาวิทยาลัย
- รูปแบบการศึกษา** : การศึกษาแบบย้อนหลัง
- ผู้ป่วยและวิธีการศึกษา** : ศึกษาทบทวนบันทึกทางการแพทย์ของผู้ป่วยที่มีอาการชวนสงสัยว่าเป็นตับอ่อนอักเสบจากนิ่วในถุงน้ำดีระหว่างปี พ.ศ. 2535 - 2544 การวินิจฉัยว่าเป็นตับอ่อนอักเสบจากนิ่วในถุงน้ำดีต้องมีข้อบ่งชี้ดังต่อไปนี้ 1) ปวดท้องและมีการกดเจ็บบริเวณท้องด้านบน 2) มีระดับซีรัมไมเลสสูงกว่าระดับปกติอย่างน้อยสามเท่า 3) ตรวจพบนิ่วในถุงน้ำดีจากการเอกซเรย์โดยใช้คลื่นความถี่สูงหรือคอมพิวเตอร์ 4) ต้องไม่มีภาวะอื่นที่สามารถทำให้เกิดภาวะตับอ่อนอักเสบได้ เช่น ภาวะไขมันในเลือดสูงหรือดื่มสุรา ผู้ป่วยที่มีข้อบ่งชี้ของแรนสันมากกว่า 2 ข้อ หรือเคยมีประวัติผ่าตัดถุงน้ำดีหรือตับอ่อน หรือไม่มีผลการตรวจเอกซเรย์ด้วยสารทึบแสงของทางเดินน้ำดีด้วยวิธีส่องกล้องหรือวิธีผ่าตัด หรือการเอกซเรย์ด้วยสารทึบแสงไม่ประสบผลสำเร็จ หรือผลการตรวจทางห้องปฏิบัติการไม่สมบูรณ์ครบถ้วน ไม่นับรวมเข้าอยู่ในการศึกษา ภาพถ่ายรังสีคอมพิวเตอร์ หรืออัลตราซาวด์นี้ถือว่าผิดปกติ เมื่อขนาดของท่อน้ำดีร่วมมากกว่า 7 มิลลิเมตร หรือมีการถ่างขยายของท่อน้ำดีในตับ หรือพบนิ่วในทางเดินน้ำดี การวินิจฉัยว่ามีนิ่วค้างในทางเดินน้ำดีได้จากการตรวจพบนิ่วในท่อน้ำดีจากการส่องกล้องหรือการผ่าตัด
- ผลการศึกษา** : ผู้ป่วย 36 ราย ได้รับการวินิจฉัยว่าเป็นตับอ่อนอักเสบจากนิ่วในถุงน้ำดีชนิดไม่รุนแรงและเข้าได้กับเกณฑ์ของการศึกษา ผู้ป่วย 9 ใน 36 (25 %) รายตรวจพบมีนิ่วค้างในทางเดินน้ำดี และไม่พบมีปัญหาทะรกซ้อนรุนแรง หรือทำให้ผู้ป่วยเสียชีวิตจากการรักษา จากการวิเคราะห์ทางสถิติพบว่าความชุกของผู้ป่วยเพศชาย ผู้ป่วยที่มีระดับซีรัมบิลิรูบินรวมสูงเกินกว่าค่าปกติ และผู้ป่วยที่ถูกตรวจพบมีความ

สรุป	:	<p>ผิดปกติของทางเดินน้ำดีโดยวิธีทางรังสีมีมากในกลุ่มผู้ป่วยที่มีนิ่วคั่งในท่อน้ำดี นอกจากนี้ยังพบว่าผู้ป่วยที่ถูกตรวจพบว่ามี ความผิดปกติอย่างใดอย่างหนึ่ง หรือทั้งสองอย่างดังต่อไปนี้ 1)ระดับซีรั่มบิลิรูบินรวม 2) ตรวจพบมีความผิดปกติทางรังสีของทางเดินน้ำดี จะมีโอกาสพบนิ่วคั่งในท่อน้ำดีร่วม (41 %) สูงกว่าในผู้ป่วยที่ไม่ถูกตรวจพบว่ามี ความผิดปกติทั้งสองอย่าง (0 %) อย่างมีนัยสำคัญ</p> <p>ผู้ป่วยระดับอ่อนอักเสบที่เกิดจากนิ่วในถุงน้ำดีชนิดไม่รุนแรง ที่ตรวจพบ ว่าไม่มีความผิดปกติทั้งของระดับซีรั่มบิลิรูบินรวม และรังสีวินิจฉัยของทางเดินน้ำดีมีโอกาสน้อยที่จะตรวจพบมีนิ่วคั่งในท่อน้ำดีร่วม ดังนั้นการส่องกล้องร่วมกับการฉีดสารทึบแสงของทางเดินน้ำดีก่อน ผ่าตัดไม่มีความจำเป็นในผู้ป่วยกลุ่มนี้</p>
คำสำคัญ	:	<p>ภาวะระดับอ่อนอักเสบจากนิ่วในถุงน้ำดี, การส่องกล้องตรวจท่อน้ำเดินน้ำดีและท่อตับอ่อน, นิ่วในท่อน้ำเดินน้ำดีร่วม</p>

The advantages of early endoscopic retrograde cholangiopancreatography (ERCP) in patients with severe gallstone pancreatitis have been documented.⁽¹⁾ Nevertheless, the role of ERCP in the management of mild to moderate gallstone pancreatitis is still poorly defined. Fan et al. recommended that preoperative ERCP should be mandatory in these patients.⁽²⁾ In recent years, however, there has been a tendency toward selective, rather than routine performance of ERCP in mild to moderate gallstone pancreatitis.^(3, 4) This selective policy saves costs and lowers the risks of unnecessary ERCP procedures. A recent prospective randomized study reported that up to 76 % of ERCP in this entity were unnecessary.⁽⁵⁾ To minimize the costs and ERCP related complications, a subgroup of patients who would not require preoperative ERCP investigation should be identified. To date, less was known regarding the identification of this subgroup of patients. This study was aimed to identify clinical predictors of patients with mild to moderate gallstone pancreatitis who were less likely to have retained CBD stones.

Patients and Methods

Medical records of patients with suspected acute gallstone pancreatitis admitted to King Chulalongkorn Memorial Hospital from 1992-2001 were retrospectively reviewed. The diagnosis of acute gallstone pancreatitis was based on the following criteria: 1) upper abdominal pain and tenderness; 2) serum amylase elevation three times higher than normal; 3) documentation of gallstones by admission ultrasonography or CT scan; and, 4) absence of recent alcohol abuse and other known causes of pancreatitis such as hyperlipidemia, hypercalcemia, abdominal

injury. Laboratory values on admission including complete blood count, serum amylase, total bilirubin, alkaline phosphatase, aspartate aminotransferase (AST), alanine aminotransferase (ALT), calcium, BUN, creatinine, LDH, and glucose were reviewed. Ranson scores were calculated. Patients with scores > 2 were classified as severe cases and were excluded from the study. Elevation of serum total bilirubin, alkaline phosphatase and serum amylase were considered if their value were higher than normal (1 mg/dl, 117 mg/dl and 220 mg/dl respectively). All patients underwent abdominal ultrasonography or CT scan within 48hr of admission. Abnormalities of biliary tract imagings were considered if CBD stones, dilatation of intrahepatic bile duct or common bile duct (CBD diameter > 7 mm) were demonstrated. Patients were excluded from analysis if any of the following criteria were identified: previous biliary or pancreatic surgery, lack of a success cholangiogram and lack of complete admission laboratory values.

All patients underwent either preoperative ERCP or cholecystectomy with intraoperative cholangiography (IOC) during the same hospitalization. CBD stone removal was done either by means of ERCP or CBD exploration. Cholecystectomies were performed either by laparoscopic or open technique depending on operative surgeons. Elevation of serum total bilirubin, alkaline phosphatase and abnormal biliary tract imagings on admission were tested as potential indicators for prediction of retained CBD stones. Patients were divided into two groups based on whether CBD stones were identified. Clinical criteria, including admission laboratory data and biliary tract imagings were compared using univariate analysis. A P-value of <0.05 was considered statistically significant.

Results

Thirty-six patients with mild to moderate acute gallstone pancreatitis met the criteria. The median age was 46.5 years (IQR= 39 - 58). There were 11 males (31%) and 25 females (69 %). Of the 36 patients, 9 (25%) had retained CBD stones and were successfully removed either by ERCP or surgery. There was no serious complication or mortality in these patients during the perioperative period.

Demographic and biochemical characteristics of patients with and without retained CBD stones are listed in table1. On univariate analysis, male gender, elevated total bilirubin level and abnormal imaging findings were predominant in patients with retained

CBD stones. Prevalence of retained CBD stones in patients with normal and abnormal serum total bilirubin (TB), alkaline phosphatase (ALK) level and bile duct imaging tests on admission is shown in figure 1- 3. Patients with abnormal serum total bilirubin and bile duct imaging studies were more likely to have retained CBD stones. Using the combination of total bilirubin level and biliary tract imaging finding for prediction of CBD calculi, the likelihood of retained CBD stones was 0 %, given that these two parameters were normal; whereas, the prevalence of retained CBD stones was 41 %, if any of these parameters was abnormal ($p=0.005$) [Figure 4].

Table 1. Demographic and biochemical characteristics of patients with and without retained CBD stones.

Parameters	CBD stone(+) (n=9)	CBD stone(-) (n=27)	p value
Male/Female	7/2	4/23	0.001
Age (years)*	54 (38-78)	45 (19-78)	ns
No. patients, total bilirubin >1mg/dl	7/9	10/27	0.034
No. patients, alkaline phosphatase >117mg/dl	7/9	18/27	ns
No. patients, imaging abnormalities	5/8	5/27	0.015

CBD stone(+): CBD stones were identified

CBD stone(-): CBD stone was not identified

* expressed as median and range

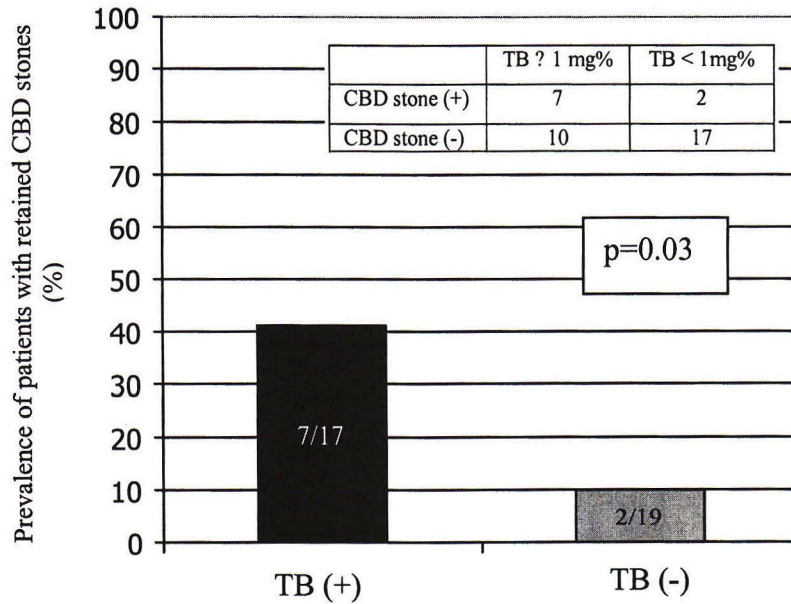


Figure 1. Prevalence of retained CBD stones in patients with elevated [TB (+)] and normal [TB (-)] serum total bilirubin level on admission. Seven out of 17 patients (41 %) with elevated TB level and 2 out of 19 patients (10 %) with normal serum TB level on admission had retained CBD stones (p=0.03).

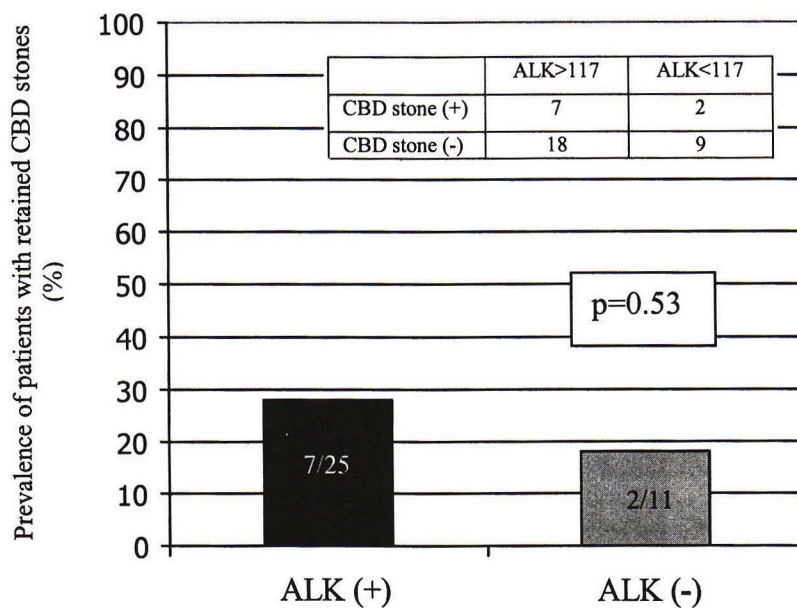


Figure 2. Prevalence of retained CBD stones in patients with elevated [ALK (+)] and normal [ALK (-)] serum alkaline phosphatase level on admission. Seven out of 25 patients (28%) with elevated ALK level and 2 out of 11 patients (18%) with normal serum ALK level on admission had retained CBD stones (p=0.53).

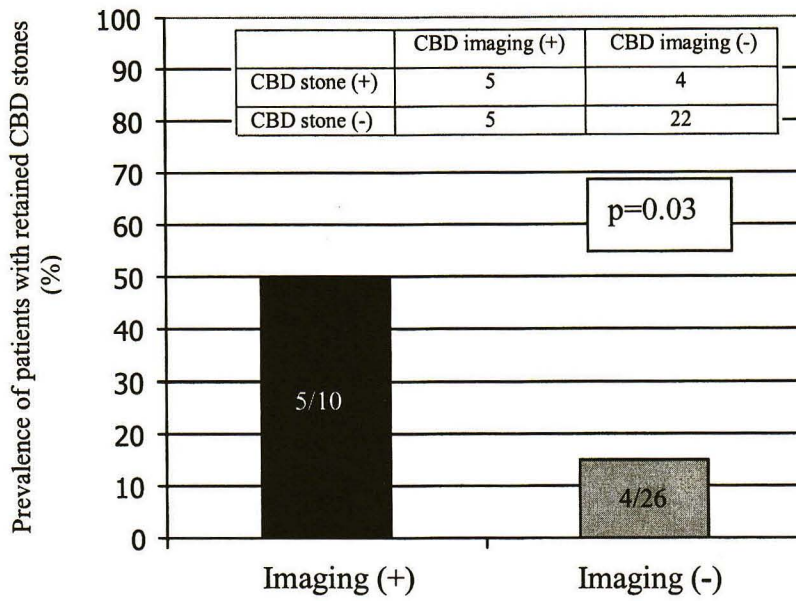


Figure 3. Prevalence of retained CBD stones in patients with abnormal [Imaging (+)] and normal [Imaging (-)] bile duct imaging studies on admission. Five out of 10 patients (50%) with abnormal and 4 out of 26 patients (15%) with abnormal bile duct imaging tests on admission had retained CBD stones (p=0.03).

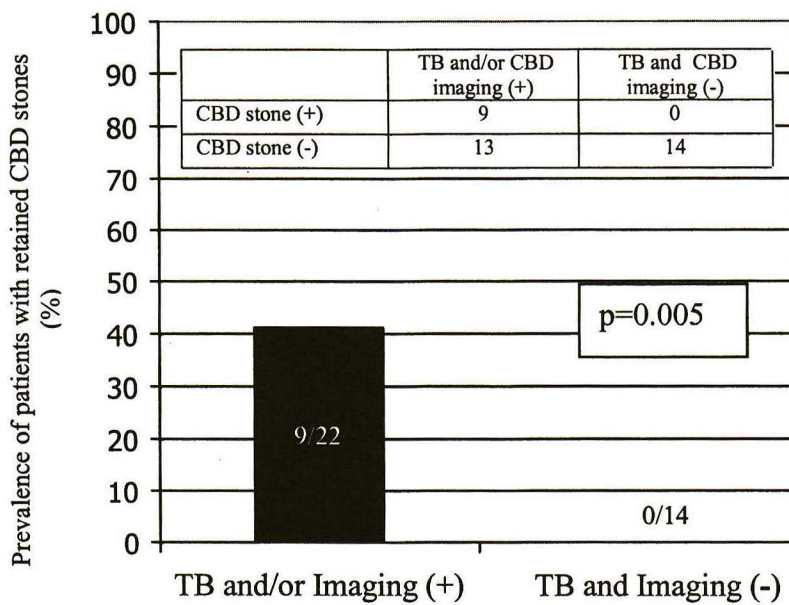


Figure 4. Comparison of the prevalence of retained CBD stones in patients with elevated serum TB level and/or abnormal imaging studies [TB and/or Imaging (+)] to that of patients with normality of both parameters [TB and Imaging (-)]. Nine out of 22 patients (41%) with abnormality at least one study and 0 out of 14 patients (0%) with normal tests had retained CBD stones (p=0.005).

Discussion

Gallstone is one of the common causes of acute pancreatitis worldwide. Most gallstones responsible for pancreatitis have already passed.⁽⁶⁾ Controversy still exists regarding the role of preoperative ERCP in mild to moderate gallstone pancreatitis. The prevalence of retained CBD stones in this entity has been reported in the range of 0-58%.^(1, 7, 8) This is similar to our finding; 25% of the patients had choledocholithiasis. This raises a question whether routine preoperative ERCP in mild to moderate gallstone pancreatitis is needed. Because of the perceived risk of retained CBD stone, traditional teaching has been that cholangiography must be performed in all patients with gallstone pancreatitis. This practice was not only unnecessary in 42-100% but it also increased the risk of procedure-related complications. Up to 19% post ERCP pancreatitis has been reported.^(3, 9)

During the past decade, one of the areas of significant change in the management of gallstone pancreatitis has been the method of CBD visualization. In the era of open cholecystectomy, performance of IOC was mandatory. As the era of minimally invasive surgery has progressed, preoperative bile duct visualization with stone removal is needed. Preoperative ERCP was introduced as the optimal method to ensure that the CBD was free of stones. If CBD stones were found, extractions could be performed prior to laparoscopic cholecystectomy. This policy has been rapidly gained in popularity because avoidance of open cholecystectomy with CBD exploration could be obtained. However, the frequency with which CBD stones are found on mandatory ERCP is low. Recent studies have

suggested a more selective approach to the use of preoperative ERCP. Even employing a selective approach, one study showed that only 55% of the patients were noted to have CBD stones.⁽¹⁰⁾

Over the past several years, various indications for performing preoperative ERCP were proposed. Chang et al.⁽⁵⁾ used total bilirubin level > 1.35 mg/dl on day 2 and Cohen et al.⁽¹¹⁾ used any rising of laboratory result including total bilirubin, alkaline phosphatase, SGOT, SGPT, amylase level on day 2 as predictors for persistent CBD stones. However, some patients with normal findings of the tests can still have CBD stones. Negative predictive value (NPV) was 96% and 92% in the study of Chang et al. and Cohen et al., respectively. In our study, we identified two parameters including elevated total bilirubin level and abnormal bile duct imaging test as the useful indicators for prediction of CBD calculi. Using either one of these parameters as a predictor of retained CBD stones results in poor sensitivity and specificity. As a result, a combination of both parameters was retrospectively tested as a potential predictor for choledocholithiasis in our studies. Abnormality of either one of both parameters is defined as positive test and normality of both parameters is defined as negative test. Nine out of 22 patients (41%) with positive tests (abnormal bilirubin and/or imaging) had retained CBD stones. In contrast, none of 14 patients (0%) with negative tests (normal level of both parameters) had CBD stone (Figure 4). Negative predictive value was 100%. This implies that cholangiography may have no role in patients with mild to moderate gallstone pancreatitis who has normal serum total bilirubin and normal biliary sonographic finding on admission. Given this result, preoperative

ERCP could be avoided in 14 out of 36 (39 %) patients in our series who had normalization of both parameters. As a result, risk of ERCP related complications and costs could be reduced by using this selective approach.

Conclusion

Patients with mild to moderate gallstone pancreatitis who have normal level of serum total bilirubin and normal sonographic findings of CBD on admission have low risk of retained CBD stone. As a result, preoperative ERCP could be avoided in this subgroup of patients. Validation of our indicators is needed in prospective trials.

References

1. Neoptolemos JP, Carr-Locke DL, London NJ, Bailey IA, James D, Fossard DP. Controlled trial of urgent endoscopic retrograde cholangiopancreatography and endoscopic sphincterotomy versus conservative treatment for acute pancreatitis due to gallstones. *Lancet* Oct 29;2(8618):979-83
2. Fan ST, Lai EC, Mok FP, Lo CM, Wong J. Early treatment of acute biliary pancreatitis by endoscopic papillotomy. *N Engl J Med* 1993 Jan 28; 328(4):228-32
3. de Virgilio C, Verbin C, Chang L, Linder S, Stabile BE, Klein S. Gallstone pancreatitis: The role of preoperative retrograde cholangiopancreatography. *Arch Surg* 1994 Sep;129(9):909-12
4. Chang L, Lo SK, Stabile BE, Lewis RJ, de Virgilio C. Gallstone pancreatitis: a prospective study on the incidence of cholangitis and clinical predictors of retained common bile duct stones. *Am J Gastroenterol* 1998 Apr;93(4): 493-6
5. Chang L, Lo S, Stabile BE, Lewis RJ, Toosie K, de Virgilio C. Preoperative versus postoperative endoscopic retrograde cholangiopancreatography in mild to moderate gallstone pancreatitis: a prospective randomized trial. *Ann Surg* 2000 Jan;231(1):82-7
6. Acosta JM, Ledesma CL. Gallstone migration as a cause of acute pancreatitis. *N Engl J Med* 1974 Feb 28;290(9):484-7
7. Schwesinger WH, Page CP, Gross GW, Miller JE, Strodel WE, Srinek KR. Biliary pancreatitis: the era of laparoscopic cholecystectomy. *Arch Surg* 1998 Oct;133(10):1103-6
8. Geron N, Reshef R, Shiller M, Kniaz D, Eitan A. The role of endoscopic retrograde cholangiopancreatography in the laparoscopic era. *Surg Endosc* 1999 May;13(5):452-6
9. Sees DW, Martin RR. Comparison of preoperative endoscopic retrograde cholangiopancreatography and laparoscopic cholecystectomy with operative management of gallstone pancreatitis. *Am J Surg* 1997 Dec;174(6): 719-22
10. Bennion RS, Wyatt LE, Thompson JE Jr. Effect of intraoperative cholangiography during cholecystectomy on outcome after gallstone pancreatitis. *J Gastrointest Surg* 2002 Jul-Aug;6(4):575-81
11. Cohen ME, Slezak L, Wells CK, Andersen DK, Topazian M. Prediction of bile duct stones and complications in gallstone pancreatitis using early laboratory trends. *Am J Gastroenterol* 2001 Dec;96 (12):3305-11