

Nephrotic syndrome with neck edema secondary to communication between pleural space and neck : a case report.

Kumtorn Lelamali* Sophon Napathorn*

Tawatchai Chaiwatanarat** Kriang Tungsanga*

Lelamali K, Napathorn S, Chaiwatanarat T, Tungsanga K. Nephrotic syndrome with neck edema secondary to communication between pleural space and neck : a case report. Chula Med J 1995 Sep;39(9): 687-692

Neck edema is rarely observed in nephrotic syndrome. We report herein a 28 year - old Thai male patient who had primary nephrotic syndrome for 2 weeks and progressive dyspnea for 1 week. He had diminution of breath sound and percussion dullness of the lower lung fields, shifting dullness of the abdomen, and pitting edema of the neck and both legs. Edema of the neck without facial edema was markedly increased in the prone position. A radiograph of the chest showed bilateral pleural effusion. The serum albumin was 1.5 mg/dl , and liver function tests were normal. The pathogenesis of neck edema aggravated by recumbent position was investigated by the injection of Technetium 99 (Tc-99m) into the pleural space of both lungs. The radioactivity of the Tc-99m was detected in the neck region by scanning method at 30 minutes after injection. This indicated that the fluid shifted from the pleural space to the subcutaneous area of the neck. The kidney biopsy revealed mesangial IgM glomerulonephritis. The patient was treated with prednisolone 60 mg/day and a small dose of loop diuretic. Five days later the neck edema was improved due to the diuretic effect and he was discharged from the hospital. In conclusion, neck edema in nephrotic patients could be caused by a shift of fluid from the pleural space to the subcutaneous tissue of the neck if the swelling of the neck was aggravated by the recumbent position.

Key words : Neck edema, Pleural effusion, Nephrotic syndrome.

Reprint request: Lelamali K, Department of Medicine, Faculty of Medicine, Chulalongkorn University, Bangkok 10330, Thailand.

Received for publication. August 10, 1995.

*Department of Medicine, Faculty of Medicine, Chulalongkorn University.

**Department of Radiology, Faculty of Medicine, Chulalongkorn University.

กำธร ลีลามะลิ, โศภณ นภาธร, ธวัชชัย ชัยวัฒนรัตน์, เกரியง ตั้งสง่า. อาการบวมที่คอที่เกิดจากการติดต่อระหว่างน้ำในช่องเยื่อหุ้มปอดและเนื้อเยื่อไตฝิวหนังบริเวณคอในผู้ป่วยโรคไตเนโฟรติก: รายงานผู้ป่วย. จุฬาลงกรณ์เวชสาร 2538 กันยายน; 39(9): 687-692

ได้รายงานผู้ป่วย ชายไทยอายุ 28 ปี 1 ราย มาโรงพยาบาลด้วยอาการบวมที่คอ และขาเป็นเวลา 2 สัปดาห์ และมีหอบเหนื่อยมากขึ้น 1 สัปดาห์ ก่อนมาโรงพยาบาล จากการตรวจร่างกายพบว่าบริเวณปอดส่วนล่างทั้งสองข้างทึบ คอและขาบวม และพบมีน้ำในช่องท้อง อาการบวมที่คอเป็นมากขึ้นถ้าคนไข้นอนราบลง ผลจากการตรวจทางรังสีทรวงอก พบว่ามีน้ำในช่องปอดทั้งสองข้าง ระดับอัลบูมินในเลือดมีค่า 15 กรัม/ลิตร การตรวจการทำงานของไตอยู่ในเกณฑ์ปกติ กลไกการเกิดการบวมที่คอ ซึ่งมากขึ้นเมื่ออยู่ในท่านอน ได้รับการศึกษาโดยการฉีดสารกัมมาภาพ-ตรังสีชนิด Tc-99m เข้าไปยังช่องปอดทั้งสองข้าง และพบว่าสารดังกล่าวไปปรากฏอยู่บริเวณคอที่บวมในเวลา 30 นาทีต่อมาซึ่งบ่งว่าน้ำในช่องปอดไหลไปยังเนื้อเยื่อไตฝิวหนังบริเวณคอ ผลการตรวจทางห้องปฏิบัติการเข้าได้กับโรคไตเนโฟรติกชนิดไม่ทราบสาเหตุ การตรวจเนื้อไตพบพยาธิสภาพแบบ mesangial IgM glomerulonephritis ได้รับการรักษาด้วยยา prednisolone 60 มิลลิกรัม/วัน และยาขับปัสสาวะ อาการบวมดีขึ้นในเวลา 5 วันหลังการรักษา

สรุปว่า อาการบวมที่คอในโรคไตเนโฟรติก นอกจากจะเกิดจากภาวะอัลบูมินในเลือดต่ำแล้วยังอาจเกิดจากการไหลของน้ำในช่องปอดมายังเนื้อเยื่อไตฝิวหนังบริเวณคอ ในกรณีที่อาการบวมเป็นมากขึ้นในท่านอน

Generalized edema is a common extra-renal complication in the nephrotic syndrome. Generalized edema includes soft tissue edema, pleural effusion or ascites. Hypoalbuminemia is commonly found in nephrotic syndrome and plays a major role in the pathogenesis of edema.⁽¹⁾ Our case of nephrotic syndrome with severe hypoalbuminemia and pleural effusion involves a patient who developed neck edema secondary to the shift of fluid from the pleural space. To the best of our knowledge, this is a first report of neck edema as a complication of pleural effusion in primary nephrotic syndrome with severe hypoalbuminemia.

Case presentation

History

The twenty-eight year-old Thai male patient was admitted to the hospital because of progressive dyspnea which he had experienced for one week. His symptoms had begun two weeks earlier with swelling of neck, dyspnea and

chest discomfort. His symptoms were aggravated by the recumbent position but improved in the sitting or standing position. He had no cough or febrile illness. Dyspnea was progressive for one week before admission.

Physical examination

(Figures 1.1, 1.2) revealed a thin male who was slightly distressed. The blood pressure was 110/70 mmHg, the pulse rate 80/min, the respiratory rate 20/min and the body temperature 36.8°C. He was fully conscious and co-operative. He had no pallor, no jaundice and no superficial vein dilatation. The cervical lymph nodes and thyroid glands were not enlarged. Decreased breath sound and dullness on percussion were demonstrated in both lower lung fields but more on the right side. The heart was normal and the liver and spleen were not enlarged. The abdomen was distended and shifting dullness was positive. A mild pitting edema of both legs was observed.

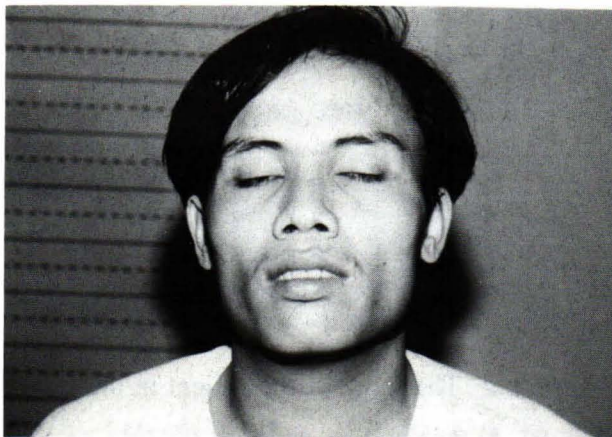

Figure 1.1 The neck and face of the patient in the upright position.

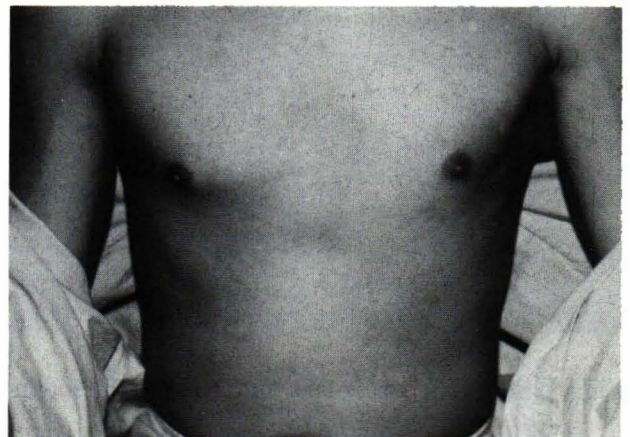


Figure 1.2 The trunk of the patient in the upright position.

Laboratory investigation

The complete blood count showed hemoglobin of 15.9 gm/dl, leucocyte count at 16,100 cell/mm³ with 81% neutrophil, 19% lymphocyte and platelets at 531,000 cell/mm³. Urinalysis showed a specific gravity of 1,028 and protein 3+. Blood chemistries revealed plasma glucose of 91 mg/dl; blood urea nitrogen 17 mg/dl; creatinine 0.9 mg/dl. The liver function tests were normal except for albumin at 1.5 gm/dl, globulin at 2.1 gm/dl. ANA CH50, and B1C were normal. VDRL was nonreactive. HBsAg and antiHIV were negative. Urine protein was 5.78 gm/day. Chest roentgenography revealed bilateral pleural effusion.

Clinical course

A kidney biopsy was performed in the prone position two days after admission. In this position the patient was in slight discomfort but

the procedure was completed without difficulty. After biopsy he was subjected to bed rest in the supine position. In half an hour, he complained of more dyspnea and chest discomfort. Physical examination found marked neck edema and mild chest edema but without facial edema (Figures 2.1, 2.2). He was treated by changing to the sitting position and the neck edema disappeared in 24 hours. The dyspnea and chest discomfort improved. The pathogenesis of neck edema was investigated by radionucleotide scan. The Tc-99 (MAA) was injected in both pleural spaces (Figure 3.1). A scan of chest and neck 30 min later demonstrated that the Tc-99m was present in the neck region (Figure 3.2). The kidney biopsy revealed mesangial IgM glomerulonephritis. He was treated with prednisolone 60 mg/day and small dose of furosemide. Five days after treatment the dyspnea was improved and he was discharged from the hospital.




Figure 2.1 The neck and face of the patient in the prone position.

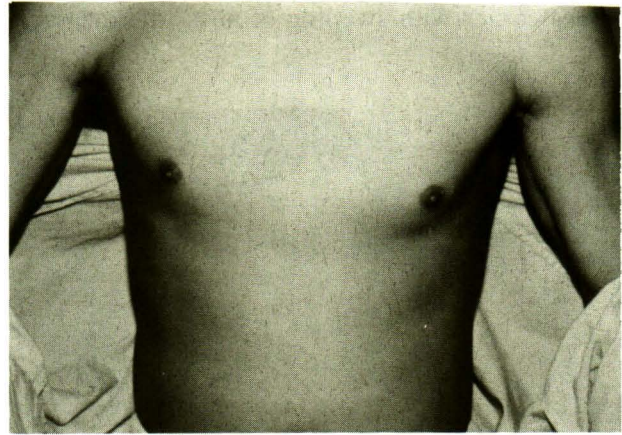


Figure 2.2 The trunk of the patient in the prone position.

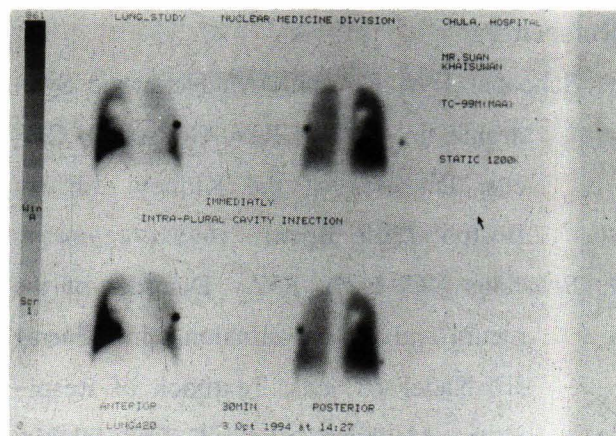


Figure 3.1 The Tc-99m was introduced into both pleural spaces.

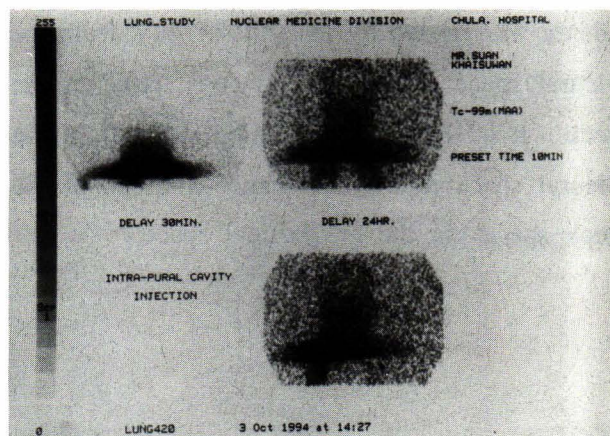


Figure 3.2 Thereafter the Tc-99m was found in the neck region.

Discussion

Among the complications of nephrotic syndrome, edema is one of the most common extrarenal complications.⁽¹⁾ Edema is commonly seen on the face and dependent parts of the body and is associated with hypoalbuminemia. Reduced intravascular oncotic pressure is believed to be one of the pathogenesis of edema formation in nephrotic syndrome. When hypoalbuminemia is severe, generalized edema which includes pleural effusion and ascites develops. Neck edema in this patient was aggravated by the recumbent position. Neck edema was accompanied by chest edema but no facial edema was observed. The pathogenesis of increased neck edema in the recumbent position is not likely, due to the leakage of fluid from the vascular space secondary to severe hypoalbuminemia because there was no facial edema and the radionuclide scan of the chest and neck after injection of the Tc-99m(MAA) into both pleural spaces was positive for Tc-99m. Because Tc-99m diffuses poorly to the blood, a positive scan of the chest and neck indicates that the fluid must

shift from the pleural space to the subcutaneous tissue of the chest and neck. Since the pleural space is not connected with the subcutaneous tissue of the neck, it is likely that the fluid shifts from the pleural space through the mediastinal space to the subcutaneous tissue of the neck. The pleural space is completely separated from the mediastinal space.⁽²⁾ Therefore, a tract which connects the two spaces together should be present in this patient. Unfortunately, we could not identify this tract by the scan. Neck edema in this patient could cause respiratory distress. This complication should be aware of in the primary nephrotic syndrome with severe hypoalbuminemia and pleural effusion.

Summary

We report a patient with mesangial IgM glomerulonephritis with nephrotic syndrome who was presented with dyspnea, neck edema and bilateral pleural effusion. The neck edema without facial edema was increased in the supine position and was accompanied by chest edema. A radionuclear study indicated that the neck

edema was caused by the shift of fluid from the pleural space to the subcutaneous tissue of the neck. It is likely that the fluid shifts from the pleural space to the subcutaneous tissue of the neck space via the mediastinal space.

References

1. Schnaper HW, Robson AM. Nephrotic Syndrome. In: Schrier RW, Gottschalk CW, eds. Diseases of the Kidney. 5th ed. Boston; Little Brown, 1993:1731-84
2. Broaddus VC, Light RW. Disorder of the pleura and pleural effusion. In: Murray JF, Nadel JA, eds. Textbook of Respiratory Medicine. 2nd ed. Philadelphia: WB, Saunders, 1994:2145-93