

Hepatocellular carcinoma with severe hypoglycemia in twins pregnancy-case report and review literature

Prasert Trivijitsilp* Nivatchai Sucharitjun*
Daoroek Sinthuanitch** Varaporn Techasena**

Trivijitsilp P, Sucharitjun N, Sinthuanitch D, Techasena V. Hepatocellular carcinoma with severe hypoglycemia in twins pregnancy-case report and review literature. Chula Med J 1994 Nov; 38(11): 699-704

A case of hepatocellular carcinoma diagnosed in a 24-year-old pregnant woman during her 25th week of pregnancy is presented. The clinical evolution was complicated by severe hypoglycemia and twins pregnancy. Good control of the plasma glucose and close supervision of the pregnancy resulted in spontaneous delivery of two live infants at the 33rd week of gestation. However, the mother died 6-7 months after delivery. Only 8 cases of hepatocellular carcinoma in pregnancy have been reported to date, with 100% maternal mortality and only 3 live infant births before this report.

Key words : *Hepatocellular carcinoma, Hypoglycemia, Pregnancy.*

Reprint request : Trivijitsilp P, Department of Obstetrics and Gynecology, Faculty of Medicine, Chulalongkorn University, Bangkok 10330, Thailand.

Received for publication. October 1, 1994.

ประเสริฐ ตริวิจิตรศิลป์, นิวัตชัย สุจริตจันทร์, ดาวฤกษ์ สินธุวณิชย์, วราภรณ์ เตชะเสนา. มะเร็งเซลล์ตับร่วมกับภาวะน้ำตาลในเลือดต่ำในการตั้งครรภ์แฝด. จุฬาลงกรณ์เวชสาร 2537 พฤศจิกายน; 38(11): 699-704

รายงานผู้ป่วยหญิงชาวเขาอายุ 24 ปี ตั้งครรภ์ที่ 2 ไม่ทราบอายุครรภ์ มาด้วยอาการไม่รู้สึกตัว ตรวจพบน้ำตาลในเลือดต่ำกว่าร้อยละ 45 มิลลิกรัม ตรวจคลื่นเสียงความถี่สูงพบว่ามีก้อนแทรกอยู่ในตับ และเป็นการตั้งครรภ์แฝดอายุครรภ์ 25 สัปดาห์ ได้ให้การรักษาโดยควบคุมน้ำตาลในเลือดให้มากกว่าร้อยละ 45 มิลลิกรัม และตรวจติดตามเฝ้าระวังทารกในครรภ์อย่างใกล้ชิดในโรงพยาบาลจนอายุครรภ์ 33 สัปดาห์ ก็คลอดทารกแฝดมีชีพ หลังคลอดทำการผ่าตัดเปิดช่องท้องและตัดชิ้นเนื้อที่ตับ ผลทางพยาธิวิทยาพบว่าเป็นมะเร็งเซลล์ตับ ผู้ป่วยถึงแก่กรรม 6-7 เดือนหลังคลอด ปัจจุบันมีรายงานมะเร็งเซลล์ตับในหญิงตั้งครรภ์ 8 ราย โดยผู้ป่วยถึงแก่กรรมทุกรายและมีทารกเกิดมีชีพเพียง 3 ราย

Hepatocellular carcinoma associated with pregnancy is a rare disease. So far, only eight cases of hepatocellular carcinoma (HCC) and two cases of cholangiocarcinoma associated with pregnancy have been reported.^(1,2,4,6,8-10) However, there was only one reported case of HCC in pregnancy that had HBsAg positive and severe hypoglycemic symptoms.⁽⁴⁾ By review literature, the authors believe this case to be the first report of hepatocellular carcinoma in a pregnant Thai woman.

Case report

A 24-year-old hill-tribe Thai woman was referred from a district hospital to Nan Provincial Hospital because of unconsciousness resulting from severe hypoglycemia. She was pregnant with an unrecalled last menstrual period after having discontinued injectable contraception 2 years earlier. Her husband and first child were HBsAg negative. Physical examination revealed an unconscious patient with no localizing signs. The liver was palpable two fingers breadth beneath the right coital margin. The fundus of the uterus was compatible with 26 weeks of pregnancy and the fetal heart rate was 156 beats/min.

Numerous hematologic studies revealed the following data: hemoglobin 12 Gm/dl; leucocyte count 10,700 cells/mm³ with a normal differential count; alkaline phosphatase 4.17 IU (normal value 0.8-3 IU); plasma sugar 13.1 mg/dl. electrolyte, urea nitrogen, creatinine and other liver hematochemistry tests were within normal ranges. A diagnosis of severe hypoglycemia, 26-week-duration gestation, and hepatocellular carcinoma was suspected. The treatments consisted of continuous intravenous infusion of hypertonic glucose and this resulted in recovery of consciousness. A positive test for HBsAg was reported later.

Ultrasonography of the whole abdomen disclosed multinodular hypoechoic-density masses in both lobes of the liver, and twins pregnancy with 25 weeks gestational age. Clinical fetal monitoring assessment, serial ultrasonography and non-stress tests exhibited normal ranges, except for three millimeters of biparietal diameter difference between the two fetuses. The patient was encouraged to take hypertonic glucose and sugarcane orally every 2 hours and occasional intravenous infusion of hypertonic glucose to control the hypoglycemic symptoms. She refused to go to the university hospital for further investigation and treatment.

After seven weeks hospitalization, she went into spontaneous labor pains and twins were born vaginally with the first and second weighing 1,850 gm and 1,350 gm, respectively. Exploratory laparotomy was done two weeks postpartum and disclosed multinodular masses in both lobes of the liver. A tubal resection and biopsy were performed. The pathological report was hepatocellular carcinoma (as figure 1 and 2). The patient denied further treatment and returned home. She continued treatment at a health center in her village and at a nearby district hospital for the hypoglycemic symptoms. Eventually, though, she died six months after delivery of the twins.

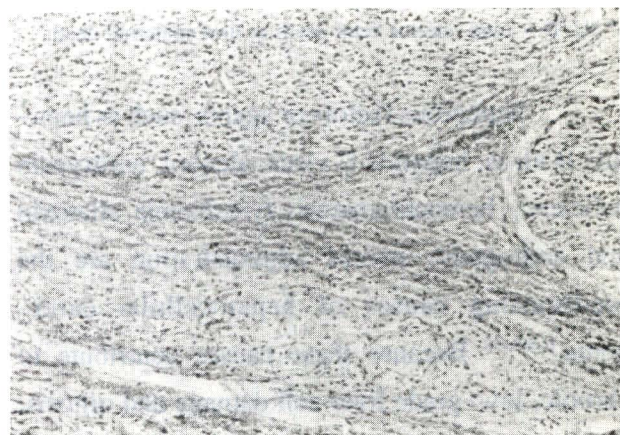


Figure 1. Shows tumor nodules in liver.

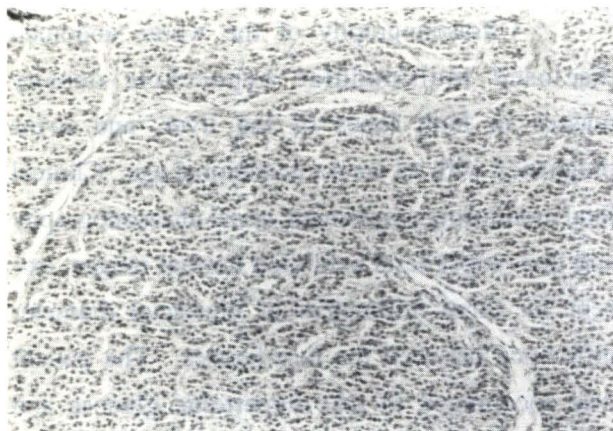


Figure 2. Shows tumor arrangement.

Discussion

Hepatocellular carcinoma is four times more common among men than in women and it associates with liver cirrhosis which is unfavorable for pregnancy.^(4,5,8,10) Hepatocellular carcinoma during pregnancy is a very rare condition which has been reported in only 8 cases (Table 1)

Table 1. Published report on clinical features of 8 cases of hepatocellular carcinoma (HCC) in pregnancy.

Author (s)	Patient Age	Alpha fetoprotein	HBsAg	Associate factors	Fetal outcom	Causes of maternal death
Roddie	43	-	-	Cirrhosis	32 wk live infant (C/S)*	tumor hemorrhage
Purtilo et al	28	-	-	HCC before pregnancy Previous left hepatectomy	32 wk IUFD**	liver failure pneumonia
Purtilo et al	37	normal	-	Cirrhosis	27 wk IUFD**	tumor hemorrhage
Christensen et al	45	normal	negative	Oral contraceptive pills	36 wk live infant (C/S)*	liver failure
Egwuatu et al	29	normal	-	Family history of HCC	22 wk macerated fetus	liver failure
Seaward et al	17	high	neagtive	No	33 wk live infant normal delivery	Unknown
Goncalves et al	33	high	positive	Hepatitis B carrier	28 wk IUFD**	severe hypoglycemia
Nganwuchu et al	30	-	-	Cirrhosis	8 month IUFD**	tumor hemorrhag

* C/S = cesarean section

** IUFD = Intra-uterine fetal death at time maternal death

Numerous factors or agents, such as hepatitis B virus, hepatitis C virus, alcohol, antitrypsin deficiency, hemochromatosis, tyrosinemia, aflatoxin and androgenic steroid administration are the predisposing causes of hepatocellular carcinoma.^(4,5,8,10) Because these causes contribute to chronic, low-grade liver cell damage and mitosis, the hepatocyte DNA will be more susceptible to

genetic alteration and may transform to liver cell carcinoma.^(5,6) Hepatitis B surface antigen was positive in our case but we did not prove the tissue specimen by immunochemistry stain.

The most common clinical features of hepatocellular carcinoma are abdominal pain with the detection of an abdominal mass at the right upper quadrant.⁽⁵⁾ However, metabolic distur-

bances such as hypoglycemia, polycythemia, polyuria etc, may also be the manifestations of these patients, as in our case.^(4,5)

The pathogenesis of hypoglycemia resulting from hepatocellular carcinoma has not been clearly established, but two possible causes may contribute to profound hypoglycemia.^(3,7) One is the increased glucose utilization by gigantic tumor masses. Second is the decreased glucose production and defective glycogen synthesis and release caused by nonsuppressible insulin-like activity of insulin-like growth factor (IGF) which is produced by tumor cells.

The usual effects of hepatocellular carcinoma on pregnancy are 100% maternal mortality, greatly increased intrauterine fetal death, and preterm labor (table 1). This case is the first for twins and the fourth for live neonates in hepatocellular carcinoma with pregnancy. However, the effect of pregnancy on hepatocellular carcinoma has been suspected to be enhancement of tumor growth due to the high steroid levels during pregnancy.^(6,10)

Ultrasonography, together with laboratory estimation of alfa fetoprotein levels will suggest the diagnosis of hepatocellular carcinoma. A definite tissue diagnosis should be obtainable from percutaneous liver biopsy or minilaparotomy biopsy.

Because of the rarity of hepatocellular carcinoma during pregnancy, there have been no reports of hepatic surgery being performed in this condition. Consequently, the best treatment for this malignancy during pregnancy is not yet known. Generally, surgical resection or live transplantation is the treatment of choice for hepatocellular carcinoma.⁽⁵⁾ Laparotomy with termination of the pregnancy should be done to assess the operability

of the tumor, reduce the steroid levels, and permit the subsequent use of chemotherapy.⁽¹⁰⁾ However, we treated only for the symptoms by oral sugarcane or glucose every two hours to prevent hypoglycemia and we performed a laparotomy biopsy during puerperium. Patients can survive more than eight months after diagnosis of hepatocellular carcinoma.

Summary

The authors report a case of hepatocellular carcinoma in a patient during twins pregnancy who was presented with severe hypoglycemia. Close fetal monitoring and the taking of sugarcane and glucose orally resulted in successful delivery; however death ensued after 8 months after diagnosis of the hepatocellular carcinoma.

Reference

1. Christensen SE, Andersen VR, Vilstrup H. A case of hepatoma in pregnancy associated with earlier oral contraception. *Acta Obstet Gynecol Scand* 1981; 60(5):519
2. Egwuatu VE. Primary hepatocarcinoma in pregnancy. *Trans R Soc Trop Med Hyg* 1980; 74(6):793-4
3. Ensmick JW, Williams RH. Disorders causing hypoglycemia. In : Williams RH, ed. *Textbook of Endocrinology*. 6th ed. Philadelphia : W B Saunders, 1981:865-6
4. Goncalves CS, Pereira FEL, de Vargas PRM, Ferreira LSE. Hepatocellular carcinoma HBsAg positive in pregnancy. *Arq Gastroent S Paulo* 1984; 21(2):75-7
5. Isselbacher KJ, Dienstag JL. Disorders of the gastrointestinal system. In : Isselbacher KJ, Braunwald E, Wilson JD, Martin JB, Fanci AS, Kasper DL, eds. *Harrison's*

- Principles of Internal Medicine. 13th ed. New York:Mc Graw-Hill, 1994:1496-8
6. Nganwuchu AM, Ojo OS. Rupture of a nodule of hepatocellular carcinoma simulating uterine rupture in late pregnancy. Trop Doct 1991 Jan; 21(1):45-6
 7. Porte D Jr, Halter JB. The endocrine pancreas and diabetes mellitus. In : Williams RH, ed. Textbook of Endocrinology. 6th ed. Philadelphia : W B Saunders, 1981:723-4
 8. Purtilo DT, Clark JV, Williams R. Primary hepatic malignancy in pregnant women. Am J Obstet Gynecol 1975 Jan 1; 121(1): 41-4
 9. Roddie TW. Haemorrhage from primary carcinoma of the liver complicating pregnancy. Br Med J Jan 5 1957; 1(5009):31
 10. Seaward PGR, Koch MAT, Mitchell RW, Merrell DA. Primary hepatocellular carcinoma in pregnancy : a case report. S Afr Med J 1986 May 24; 69(11):700-1