

Imaging of renal abscesses.

Laddawan Vajragupta* Ruengchai Vajarapongse**
Sriprapa Pipatchaisiri* Daranee Bunjunwetwat*

Vajragupta L, Vajarapongse R, Pipatchaisiri S, Bunjunwetwat D. Imaging of renal abscesses. Chula Med J 1990 Aug ; 34(8) : 587-599

We retrospectively reviewed sonographic, excretory urographic and computed tomographic appearances of renal abscesses in 17 patients during January 1984 to June 1989. Each patient had sonography; 11 had excretory urography and 8 computed tomography. The most common sonographic findings were an inhomogeneous hypoechoic well-defined mass with through transmission (12/17). The remaining sonographic patterns were thick-walled cysts with internal echo in 4, diffuse enlarged kidney with inhomogeneous parenchymal echo in 1, perinephric collection in 2, subcapsular collection in 1 and splenic extension in 1. The excretory urography showed mass effect upon the pelvicalyceal system in 9 patients and faint excretion with enlarged kidney in 2 patients. The computed tomography revealed low-density mass with rim enhancement in 5 and without rim enhancement in 2 patients, thick-walled cyst with septation in 1, thickening of the Gerota's fascia in 5, edematous perirenal fat in 3, subcapsular collection in 2, perinephric collection in 2 and splenic extension in 1.

Excretory urography is not a sensitive and specific method for visualizing small abscesses of the kidney. The number of positive excretory urogram increases as the mass becomes larger and more defined. Sonography is the fastest, least expensive and accurate method that can be used to identify and follow up renal abscess. The examination is not affected by poor renal function or allergy to contrast material. Percutaneous diagnostic needle aspiration and drainage by sonographic guidance can provide specific cytologic or bacteriologic proof of infection. Computed tomography is an expensive modality but it provides the most precise anatomic localization of the lesion. Computed tomography is helpful in acutely or critically ill patients with high suspicions of renal abscess and uncertain sonographic findings.

Reprint request : Vajragupta L, Department of Radiology, Faculty of Medicine, Chulalongkorn University, Bangkok 10330, Thailand.

Received for publication. March 29, 1990.

* Department of Radiology, Faculty of Medicine, Chulalongkorn University.

** Department of Surgery, Faculty of Medicine, Chulalongkorn University.

ลัดดาวัลย์ วัชรกุลป์, เรืองชัย วัชรพงศ์, ศรีประภา พิพัฒน์ชัยศิริ, ดร.ณิ บุญยอินเวทวัฒน์, อิมเมจจิงของฟีในไต. จุฬาลงกรณ์เวชสาร 2533 สิงหาคม; 34 (8): 587-599

คณะผู้ศึกษาได้ศึกษาลักษณะภาพทางอัลตราซาวด์ เอกซเรย์ระบบทางเดินปัสสาวะ (excretory urography) และเอกซเรย์คอมพิวเตอร์ของฟีในไต 17 ราย ในระหว่างเดือนมกราคม พ.ศ. 2527 ถึงเดือนมิถุนายน พ.ศ. 2532 โดยการตรวจด้วยอัลตราซาวด์ 17 ราย เอกซเรย์ระบบทางเดินปัสสาวะ 11 ราย และเอกซเรย์คอมพิวเตอร์ 8 ราย พบว่าลักษณะภาพทางอัลตราซาวด์ที่พบมากที่สุดคือก้อนที่มีขอบเขตชัดเจน มีการสะท้อนของคลื่นเสียงที่มีลักษณะ hypoecho เมื่อเทียบกับเนื้อไตปกติ และมีคลื่นเสียงผ่านไปได้ดี (through transmission) พบได้ใน 17 ราย นอกจากนี้ยังพบว่าเป็นก้อนที่มีลักษณะเป็นถุงน้ำผนังหนาและมี echo ภายในก้อน 4 ราย และเป็นลักษณะไตที่มีขนาดใหญ่อันเนื่องมาจากการสะท้อนของคลื่นเสียงไม่สม่ำเสมอในส่วนของเนื้อไต 1 ราย การถูกลามนอกไตพบว่าถูกลามไปรอบ ๆ ไต (perinephric collection) 2 ราย ไปใต้ต่อ capsule ของไต (subcapsular collection) 1 ราย และถูกลามไปที่มี้าม 1 ราย ส่วนลักษณะเอกซเรย์ระบบทางเดินปัสสาวะพบว่า เป็นลักษณะของการมีก้อนทำให้มีการกีดขวางไต 9 ราย และเป็นลักษณะของการทึบแสงบริเวณกรวยไตไม่ชัดเจนร่วมกับขนาดไตใหญ่อันเนื่องมาจากการทึบแสงที่ขอบเขตชัดเจนและมี enhancement ที่ขอบของก้อนหลังฉีดสารทึบแสง 5 ราย ไม่มี enhancement ที่ขอบของก้อน 2 ราย นอกจากนี้ยังพบว่า เป็นก้อนที่มีผนังหนาและมีน้ำอยู่ภายใน 1 ราย การถูกลามนอกไตจากการตรวจด้วยเอกซเรย์คอมพิวเตอร์พบว่า gerota's fascia หนาขึ้น 5 ราย บวมของเนื้อเยื่อไขมันรอบไต 3 ราย ถูกลามใต้ต่อ capsule ของไต 2 ราย รอบ ๆ ไต 2 ราย และถูกลามไปที่มี้าม 1 ราย

การตรวจด้วยเอกซเรย์ระบบทางเดินปัสสาวะเป็นการตรวจที่ไม่ไวในการวินิจฉัยฟีในไตและก้อนฟีในไตต้องมีขนาดใหญ่มากพอควรถึงจะวินิจฉัยได้ อัลตราซาวด์เป็นการตรวจที่รวดเร็ว ราคาไม่แพงและสามารถวินิจฉัยรวมทั้งติดตามผลการรักษาได้อย่างแม่นยำโดยไม่ต้องคำนึงถึงการแพ้สารทึบแสงหรือการทำงานของไตที่ผิดปกติ นอกจากนี้ อัลตราซาวด์ยังช่วยชี้บอกตำแหน่งในการเจาะดูดหนองของฟีในไต เอกซเรย์คอมพิวเตอร์เป็นการตรวจที่มีราคาแพงเมื่อเทียบกับอัลตราซาวด์ แต่สามารถบอกรายละเอียดทางกายวิภาคของฟีในไตและการถูกลามได้แม่นยำถูกต้องกว่า เอกซเรย์คอมพิวเตอร์ จะมีประโยชน์ในผู้ป่วยที่มีอาการขั้นวิกฤต สงสัยว่าเป็นฟีในไต แต่มีผลการตรวจด้วยอัลตราซาวด์ที่ไม่แน่นอน

Renal cortical abscess is part of the broad spectrum of inflammatory renal lesions which range from acute pyelonephritis to perinephric abscess. Renal abscess is the localized suppurative process of the renal parenchyma which arises from a confluence of many smaller infectious foci or microabscesses. This larger suppurative collection may remain in the cortex as an acute or chronic process. The diagnosis of renal abscess is still a challenging problem. Early manifestations are usually non specific and non localizing. Although, renal abscess is a less common disease but important consideration in the differential diagnosis of renal mass lesions. Excretory urography and angiography have been the primary methods used in evaluating patients with suspected renal abscess. In the patient with abnormal urograms, such as a renal mass, sonography and computed tomography have largely supplanted angiography as the next imaging method of choice. We report a retrospective review of 17 patients of suspected renal abscesses that were studied by excretory urography, sonography and computed tomography at the Chulalongkorn Hospital.

MATERIALS AND METHODS

During the period between January 1984 to June 1989, 17 patients were retrospectively evaluated with excretory urography, sonography and computed tomography for suspected renal abscesses. Each had sonography, 11 had excretory urography and 8 had computed tomography. The diagnosis of a renal abscesses were confirmed by surgery in 5 patients, 4 of them by open and drainage and 1 by nephrectomy. One patient was dead from septicemia, one proven by autopsy. One of our series had percutaneous aspiration by sonographic guidance. The other 10 patients, they did not require surgery or intervention therapy and there was gradual clinical improvement after prolonged antibiotic therapy.

The age incidence was between 16-78 years with 16 female and 1 male. All of them had a clinical presentation with an initial diagnosis of acute pyelonephritis (fever, flank pain and documented urinary tract infection) 4 of the 17 patients had bimanual palpable mass. Ten patients had an underlying disease ; 8 with diabetes mellitus, 1 in post partum period and 1 with renal stone that made them susceptible to infection

The sonography was performed on commercially available units using 3.5 MHz. transducer. The standard examination of the kidney included multiple coronal, longitudinal sections and sagittal and transverse scans in the prone position. Computed tomography was performed using a General Electric CT 8800 Scanner before and after intravenous contrast material injection. Contiguous scans were performed at 1 cm. interval through the kidney region. The appearances of the renal abscess were analysed for size, shape, location, extension of the disease, excretory urographic change, sonographic pattern and computed tomographic features with measured attenuation values in pre- and post contrast study.

RESULTS

Of the 17 patients, 11 had solitary lesion and 6 had multiple lesions. Eleven patients had abscesses located in the right kidney, 4 had abscesses of the left kidney and 2 patients had bilateral renal abscesses. The size of the renal abscesses ranged from 0.5 to 6.0 cm. in diameter. The most common organism in the patients with renal abscesses was E.coli (5 patients). The bacterial culture in the other patients were 1 with Staphylococcus aureus and 1 with Beta Streptococcus group B. There was no growth in both hemoculture and urine culture in 10 patients.

An excretory urography with and without nephrotomogram was obtained in 11 patients. An intrarenal mass effect causing amputation or stretching of the pelvicalyceal system could be detected in 9 patients (Figure 1). Faint excretion with enlarged kidney and inhomogeneous nephrogram were found in 2 patients (Figure 2). In all 17 patients who had sonography, the abscesses appeared as well defined inhomogeneous hypoechoic round masses with through transmission in 12 patients (Figure 3) and thick wall cystic masses containing internal echo in 4 patients (Figure 4). One of these 4 had fluid-fluid level in the abscess. Enlargement of kidney with inhomogeneous parenchymal echo was found in 1 patient (Figure 5). Extension of the renal abscess beyond the kidney was demonstrated by sonography in 4 patients. There were perinephric collection in 2 patients (Figure 6), 1 with subcapsular collection (Figure 7) and another with extension to spleen with abscess formation in the spleen (Figure 8). Sonographic appearances are summarized in Table I.

TABLE I. Sonographic appearances of renal abscesses in 17 patients.

Inhomogeneous hypoechoic mass	12 patients
Thick-wall cystic mass with internal echo	4 patients
Enlarged kidney with inhomogeneous parenchymal echo	1 patient
Perinephric collection	2 patients
Subcapsular collection	1 patient
Splenic extension with abscess formation	1 patient

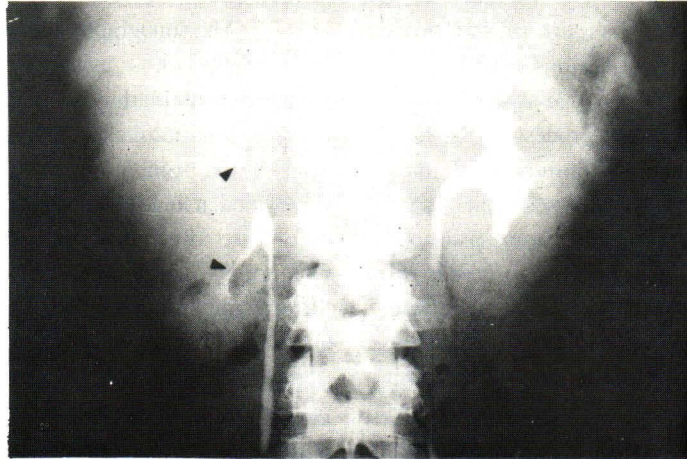


Figure 1. Excretory urogram showed an intrarenal mass in the middle pole of the right kidney causing stretching of the pelvicalyceal system (arrow head).

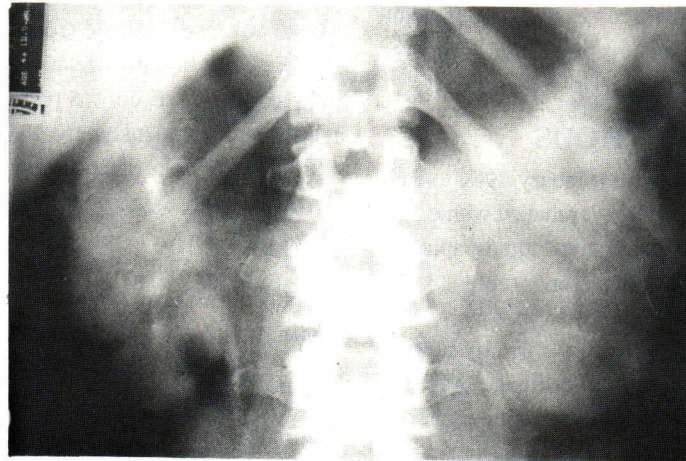


Figure 2. Excretory urogram with tomogram of multiple small renal abscesses revealed slight enlarged left kidney with faint excretion and inhomogeneous nephrogram.

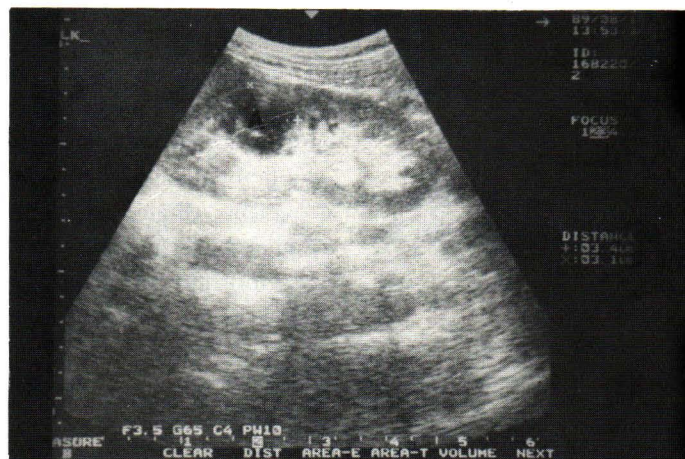


Figure 3. Coronal sonogram of the left kidney showed a well defined round inhomogeneous hypoechoic mass with through transmission (A) in the upper pole of the left kidney. There was pressure effect upon the adjacent pelvicalyceal system.

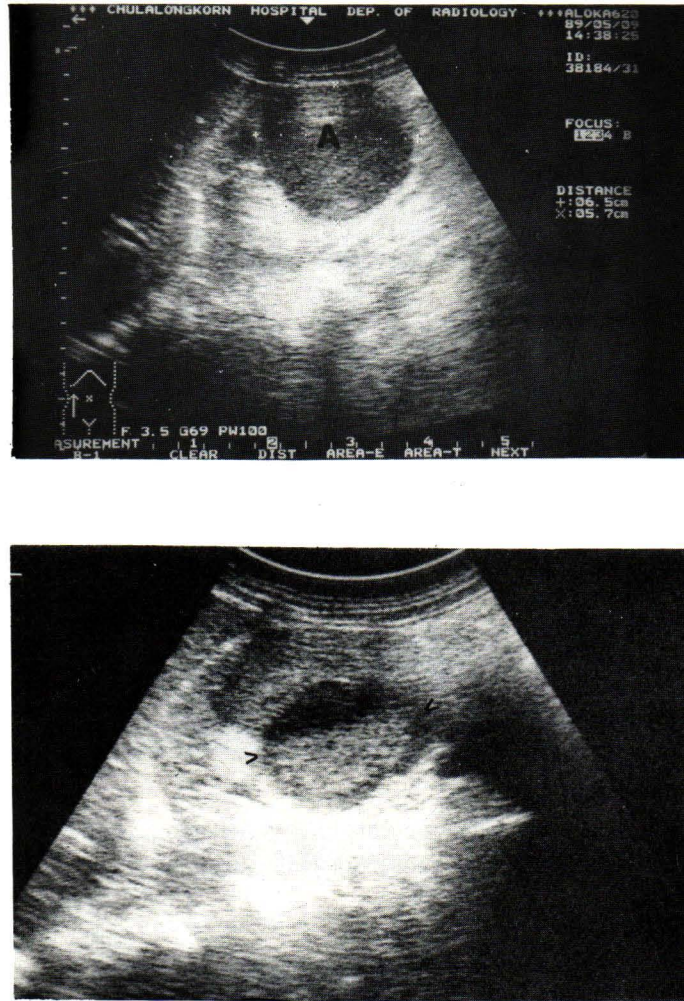


Figure 4. A. Coronal sonogram of the right kidney demonstrated a well defined round thick-wall cystic mass containing internal echo (A) in lower pole of the right kidney.
B. when changing the position, there was fluid-fluid level in this thick wall cystic mass. (arrow head).

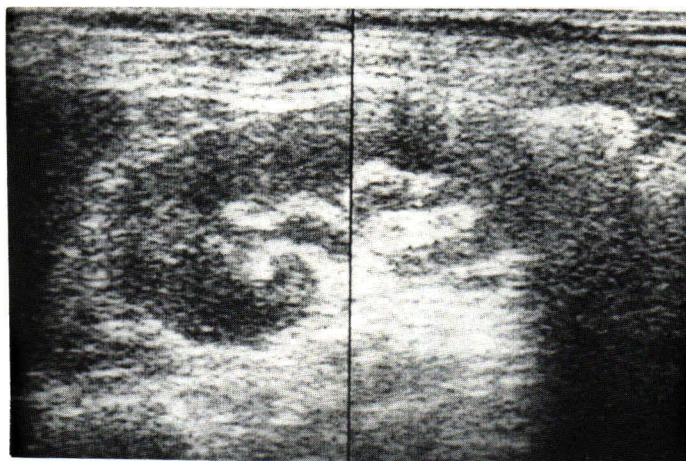


Figure 5. Coronal sonogram of the left kidney showed a slightly enlarged kidney with inhomogeneous parenchymal echo and mild stasis of the pelvicalyceal system.

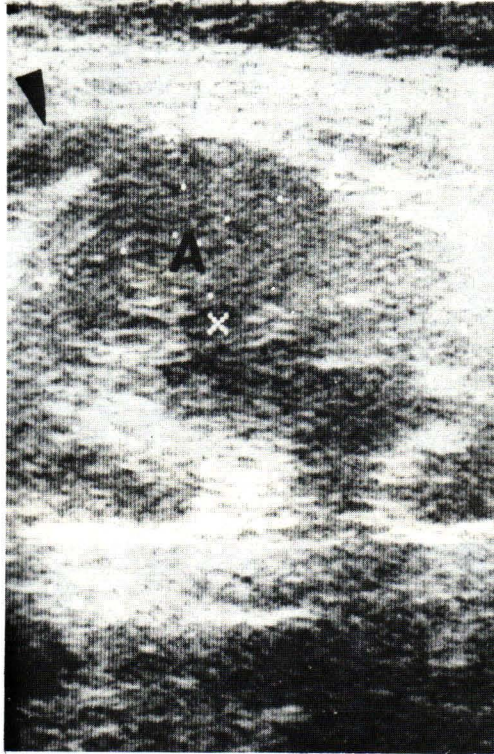

Figure 6. Coronal sonogram of the left kidney revealed a hypoechoic mass of abscess in the middle pole of the kidney (A). There was perinephric collection in the superolateral aspect of the kidney (arrow head).

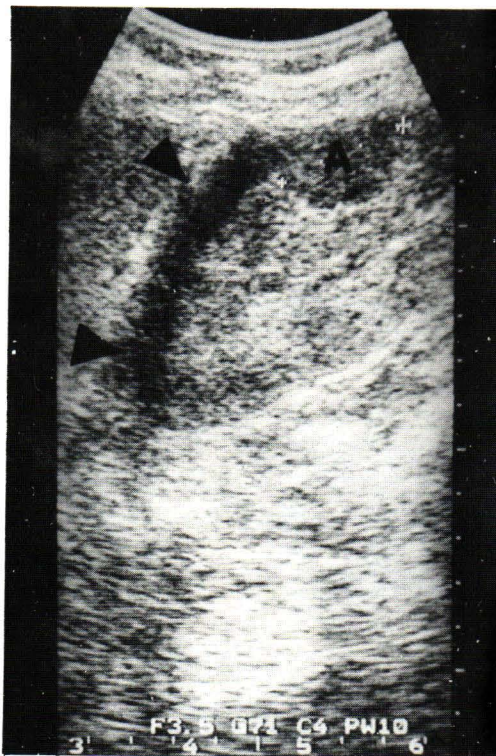

Figure 7. Coronal sonogram of the left kidney showed a well defined hypoechoic mass in the middle part of the kidney (A) with evidence of subcapsular collection (arrow head).

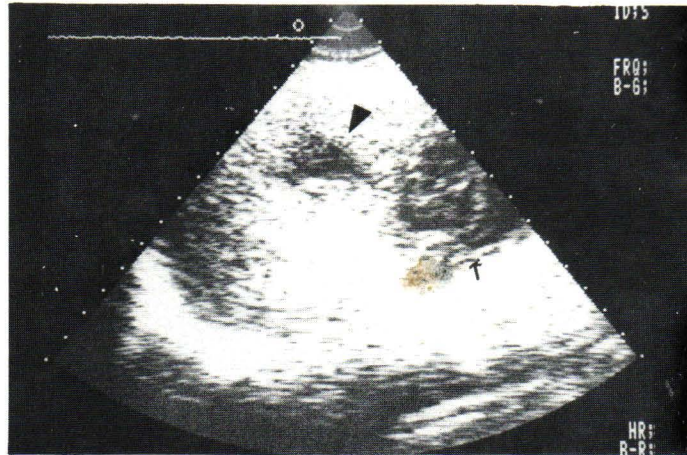


Figure 8. Coronal sonogram of the splenic region revealed a hypoechoic mass in the spleen (arrow head). Partially visualized upper pole of the left kidney showed an inhomogeneous hypoechoic mass (arrow) which represents the renal abscess, with extension beyond the kidney to the spleen and formation of the splenic abscess.

With computed tomography, the renal abscesses characteristically appeared as a well defined low density parenchymal lesion that was not enhanced after intravenous injection of contrast material in 7 patients (Figure 9A). In 5 of these, an enhancing rim around the mass was detected on the contrast-enhanced scan (Figure 9B). We found 1 patient with thick wall cyst with septation (Figure 10).

Computed tomography revealed extension of the renal abscesses as thickening of the Gerota's fascia in 5 patients, edematous perirenal fat in 3, subcapsular collection in 2 (Figure 11) perinephric collection in 2 (Figure 12) and extension to spleen with formation of splenic abscess in 1 (Figure 13). Computed tomographic findings are summarized in Table II.

TABLE II. Computed tomographic findings in 8 patients.

Low density mass with rim enhancement	5 patients
without rim enhancement	2 patients
Thick-wall cyst with septation	1 patient
Thickening of Gerota's fascia	5 patients
Perinephric collection	2 patients
Subcapsular collection	2 patients
Edematous perirenal fat	3 patients
Extension to spleen with splenic abscess	1 patient

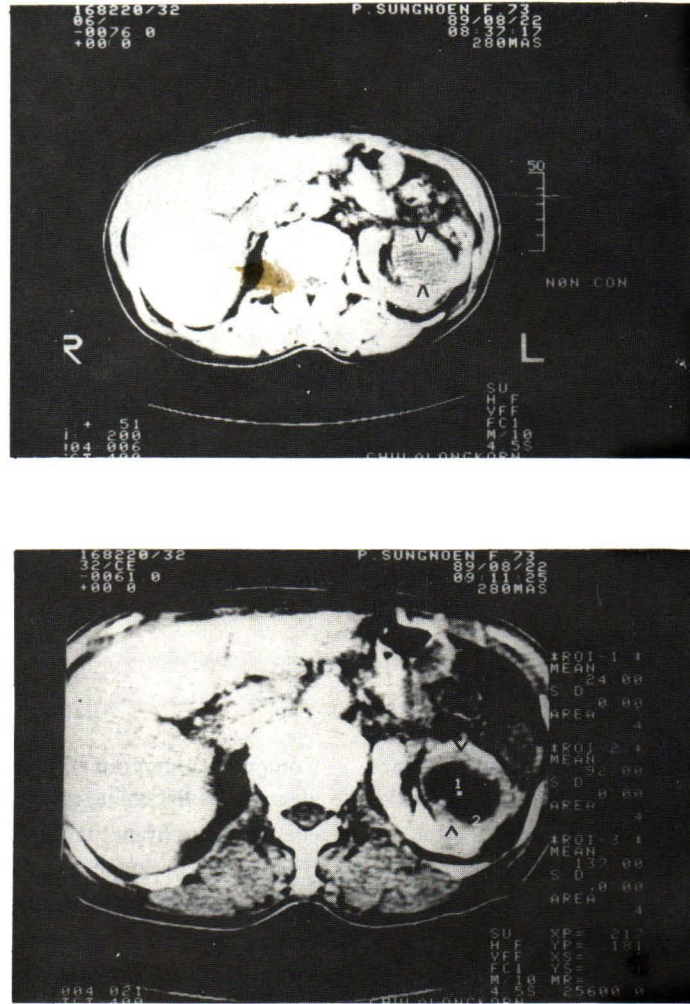


Figure 9. A. The pre-contrast CT scan showed hypodensity mass in the left kidney (arrow head).
 B. The post contrast study revealed non enhancement of the center of the renal abscess with peripheral enhancement (arrow head).

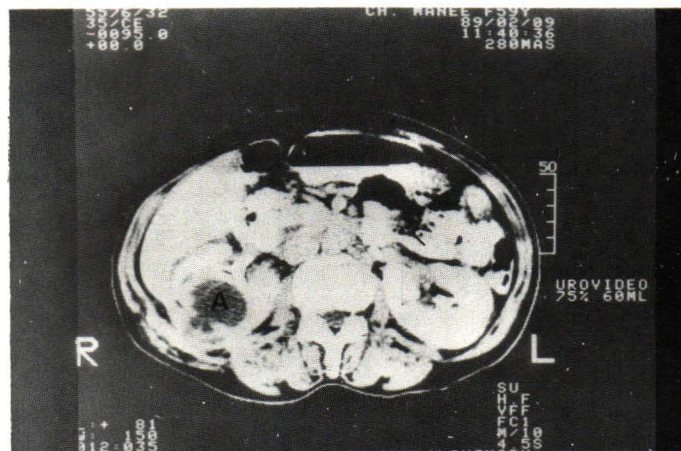


Figure 10. CT scan of the kidney with post contrast injection demonstrated thick-wall cyst with septation (A) in the right kidney with enlarged right kidney.

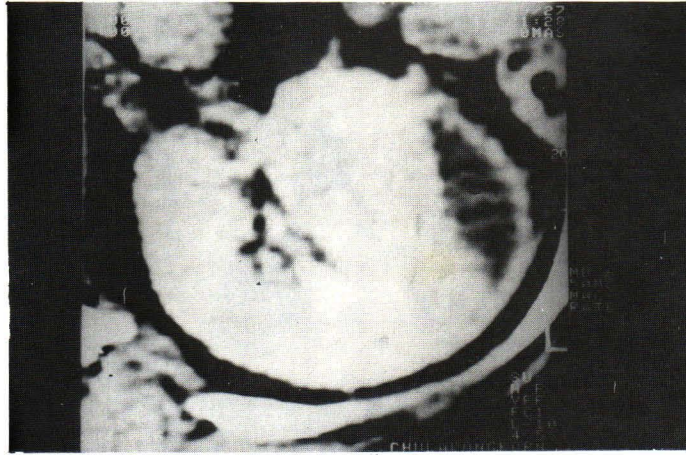


Figure 11. CT scan focused of the left kidney demonstrated subcapsular collection.

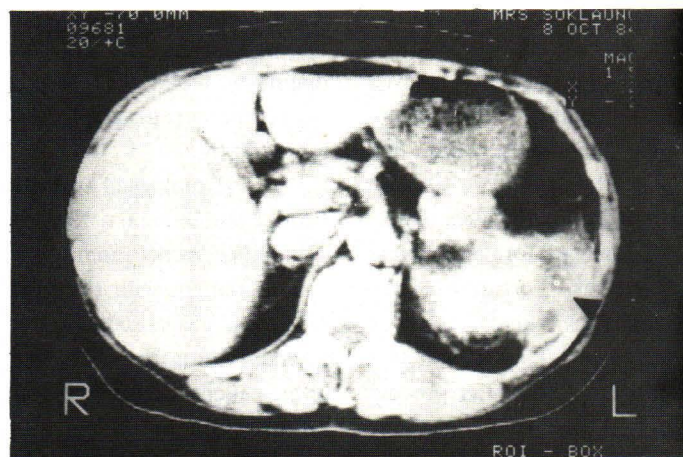
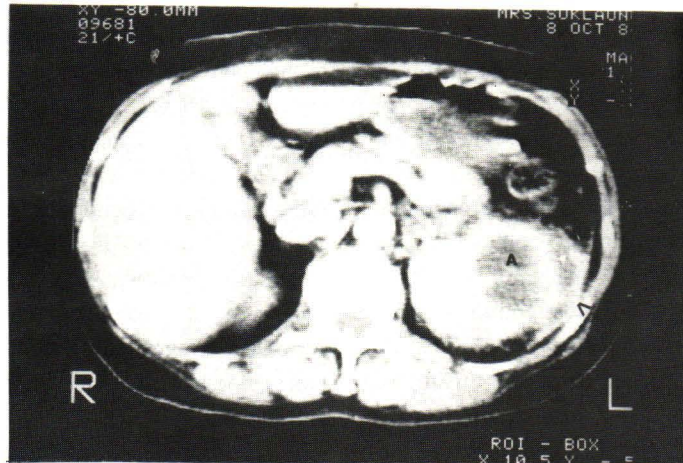


Figure 12. A. CT scans of the upper pole of the left kidney showed enlarged left kidney with two hypoechoic masses in the upper pole of the left kidney (A), with perinephric collection (square block), thickening of the Gerota's fascia (arrow head) and edematous perirenal fat.
B. CT scan of the plane 1 cm. above the figure 12A. revealed evidence of perinephric collection extension to the superior aspect of the left kidney (square block).

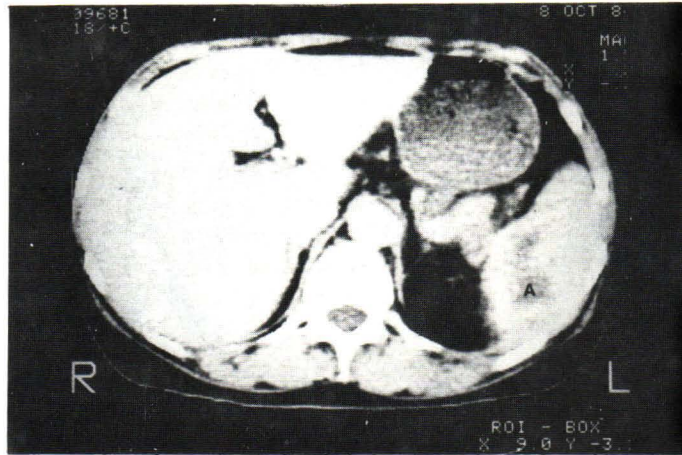


Figure 13. CT scan of the same patient in figure 12. showed ill-defined border of hypodensity mass in the spleen (A) which proved to be a splenic abscess from renal extension.

DISCUSSION

Renal abscess in an infrequent encountered condition. The diagnostic strategy for evaluation of renal abscess should be carefully planned to achieve the correct diagnosis with the fewest tests. Renal abscess is the localized suppurative process of the renal parenchyma which arise from a confluence of many small infections foci. There are 2 major pathogenic mechanisms for the development of renal abscess, the most common being ascending infection from the lower to the upper urinary tract, then into the renal parenchyma. In this case, offending organisms are those which are commonly found in urinary tract infections (i.e., *Escherichia Coli*, *Proteus* and *Pseudomonas*). Uncommonly, there may be hematogenous seeding extrarenal sources, such as cutaneous, dental or pulmonary infections. The organism responsible is almost always *Staphylococcus aureus*. Lymphogenous spread, although probable, has not yet been proven experimentally.⁽¹⁻³⁾ The infecting organism localizes to the renal cortex more commonly than to the medulla because of the richer blood supply, lower interstitial pressure and more confluent lymphatics. Once an intrarenal abscess is present, it may perforate the renal capsule to form a perinephric abscess, perforate to the renal collecting system and manifest as pyuria or remain as chronic intraparenchymal abscess⁽⁴⁾. Of our patients, 1 had focal renal abscess secondary to the latter process but of unknown primary source. There were 5 patients with positive culture for *E.Coli* and 1 for beta streptococcus group B. Development of renal abscess in these groups of patients were from ascending infection from urinary tract. Upto 20% of patients with renal abscess have negative bacterial culture⁽⁵⁾. We found sterile bacterial culture in 10 of 17 patients.

Renal abscess may occur in a patient of any age group and usually unilaterally. There were unilateral renal abscess in 15 patients and bilateral in 2 patients in our series ; 16 of 17 patients of our series were female. Diabetes mellitus was the most common predisposing factor which we found in 8 of 17 patients. We had only 1 patient with predisposing factor from post partum period. The predisposing factor of the male patient was renal stone. The most common clinical presentation of our series were fever with chill, flank pain, leukocytosis and white blood cell in urine analysis. Four of 17 had renal enlargement.

In the past, renal abscess was associated with a heavy mortality rate of up to 20%⁽⁶⁾, but in recent years this rate has decreased significantly to 0 to 2%⁽⁷⁾. This event has been possible mainly because of the development of broadspectrum antibiotics, and more rapid and accurate diagnostic techniques including plain film of abdomen, excretory urography, sonography and computed tomography.

Radiological evaluation should begin with a plain film of the abdomen. Radiopaque stone or collection of air bubbles in the renal region can be detected. We had 1 male patient with right renal stone. We did not find intrarenal gas abscess as reported by Sharma et al⁽⁸⁾. Excretory urography is the next modality in the evaluation of the patient with renal abscess except in the case of renal failure but it is a non specific procedure. Excretory urographic findings of the renal abscess has been reported elsewhere⁽⁹⁻¹⁴⁾. Radiologic findings depend on stage of the abscess and the type of extension that has occurred. The most common urographic findings in our series are bulge in outline of the kidney and stretching or distortion of the pelvicalyceal system due to localized single large abscess

(9 in 11 patients). These urographic findings were also detected by other authors.^(10,12,15,16) However, these features were indistinguishable from other renal mass such as renal cyst or renal tumor. If there were multiple small renal abscesses the kidney might appear enlarged and swollen with faint or no opacification similar to severe acute pyelonephritis⁽⁹⁻¹¹⁾. We found 2 patients with these radiological patterns, 1 of whom had small abscesses of size about 0.5-1 cm. which could be detected by computed tomography. Sonography also missed these small abscesses. The other had renal abscesses of about 2 cm. in size which was demonstrated by sonography. Rabinowitz et al. reported 6 patients with acute renal carbuncle. They found faint visualization of the collection system in 5 of 6 patients and 1 with mass effect by excretory urography⁽¹⁰⁾. We also confirmed the prior impression of other authors that excretory urography is not a sensitive and specific method for visualizing early small renal abscesses⁽⁹⁻¹¹⁾. The number of positive urogram increases as the mass becomes large and more defined.

Renal sonography can be used to identify the different phases of renal infection. The examination is not affected by poor renal function or allergy of contrast material. Sonographic appearances of renal abscess have been well described.^(12,15,17-20) The most common sonographic features of renal abscess in our series were well defined round inhomogeneous hypoechoic mass with increased through-transmission (12 of 17 patients). We found irregular thick walled cystic mass containing internal echo in 4 patients. These were consistent with the sonographic findings of renal abscess as described by other authors.^(12,15,17,19,20) We missed the multiple small renal abscesses in 1 patient by sonography in whom the abscesses were smaller than 1 cm. Hoddick et al reported that the abscesses missed by sonography in their series were all 2 cm, or smaller. The presence of internal echoes presumably was related to the degree of loculation of the pus¹⁶ and amount of the debris²⁰. Masses greater than 2 cm. in diameter are usually demonstrated by sonography.^(12,19) This is keeping with our experience, as the small abscesses missed by sonography in our series were all smaller than 1 cm. We found enlarged kidneys with inhomogeneous parenchymal echo in these patients. Differentiating renal abscess from the other renal mass remains a problem. Usually renal cell carcinoma appears as an echogenic mass.⁽²¹⁾ Sonography will not differentiate between renal abscess and hypernephroma when important central necrosis has occurred.⁽²²⁾ However, clinical signs and symptoms of inflammatory process such as fever, flank pain, increased white blood cell count and urinary tract infection may be

helpful in diagnosis of abscess. Rapid sequential changes of sonographic features are the hallmark of an infection and will usually exclude neoplasm from the differential diagnosis. For the acute focal nephritis (lobar nephronia), the typical sonographic feature is a sonolucent poorly marginated mass containing low-level echoes that disrupt the corticomedullary junction with poor transmission.^(16,18,20)

Computed tomography is the other non-invasive method of determining the presence, nature and extent of renal mass. The computed tomographic findings of renal abscess have been reported,^(1,3,15,18,19,23) The most common computed tomographic finding of renal abscess in our series was a well defined, rounded low density mass within the renal parenchyma with a variable amount of contrast enhancement of the border around the lucent area (5 of 8 patients) which was similar to other previous reports. ^(1,3,14,15,18,23) The lucent area itself would not enhance to any significant degree. This usually indicated necrosis within the renal abscess. The peripheral enhancement of the renal abscess resulted from the luxuriant perfusion of the contrast medium through the dilated, inflamed vessels in the abscess wall. We found 2 patients with a well defined low density mass of abscess and without wall enhancement. Morehouse et al also reported that the wall of the renal abscess demonstrated enhancement in 1/3 to 1/2 of the cases.⁽¹⁴⁾ One patient with thick-walled cyst, with septation was observed in our series but has not been described in other series. This pattern of may have been due to an infected renal cyst turning into a renal abscess. The presence of gas within the mass helped to confirm the renal abscess.^(8,15) However, we did not find any abscess containing gas. Computed tomography also aided in the distinction between acute focal bacterial nephritis, tumor and renal abscess. Computed tomography also depicts the poorly marginated wedge area of same or less density than normal parenchyma, with patchy or inhomogeneous enhancements in acute focal bacterial nephritis, and without liquefaction and no extension beyond the kidney in acute bacterial nephritis in contrast to the frank renal abscess.^(18,23) Typical computed tomographic features of renal cell carcinoma include isodensity with the normal renal parenchyma on the plain scan, strong and anarchic enhancement after bolus intravenous injection of the contrast material, and relative hydodensity on the delayed scan. In central necrosis, the center of the lesion becomes hypodense, without enhancement. Enhancement of the tumor tissue, surrounding the central necrotic area with liquid density can mimic renal abscess.⁽²²⁾ However, thickening of the Gerota's fascia can be noted in the renal abscess.

Computed tomography and sonography demonstrated extension of the renal abscess beyond the kidney, such as perinephric collection, subcapsular collection and extension to spleen with formation of splenic abscess. Computed tomography depicted thickening of Gerota's fascia and edematous perirenal fat while sonography failed to demonstrate such extension. Thickening of the Gerota's fascia is sensitive but non-specific that also may be seen in trauma, pancreatitis and adjacent malignancies.⁽³⁾ The perinephric extension of the renal abscess is the common extension beyond the kidney. Splenic extension and subcapsular abscess as complications of the renal abscess are rare. Reiber et al reported a case of splenic abscess resulting from perinephric abscess in a patient with staghorn calculus.⁽²⁴⁾ Zatuchni et al reported the renal subcapsular abscess in a diabetic female patient.⁽²⁵⁾ Sonography was accurate in defining a renal abscess but the extent of disease and anatomical detail were better with computed tomography.⁽³⁾

The successful management of renal abscess is based on early diagnosis and early treatment. Ten of 17 patients in our series were clinically improved after aggressive antibiotic therapy. Hantman et al have demonstrated successful nonsurgical treatment of a cortical renal abscess with aggressive antibiotic therapy. If the patient has acceptable response to intravenous antibiotics, the lesion may be followed by serial sonography. However, if there is any evidence of extension of the abscess beyond the renal capsule or if the patient's condition deteriorates, drainage should be accomplished with open surgery or a percutaneous techniques⁽¹³⁾. The other authors accepted that the basis for effective therapy of the renal abscess is early diagnosis and drainage.^(14,16,19,26,27) Since 1973 sonographic guided percutaneous drainage and more recently computed tomographic guided aspiration have become popular and attractive procedures for the definitive treatment of renal abscess.^(13,14,16,19,26,27) These procedure avoid the risk of open surgery and decrease significantly the cost and hospitalization. Percutaneous diagnostic needle aspiration can provide specific cytologic or bacteriologic proof of infection. Sonography can be used as the guidance procedure if the lesion is located superficially (within 5 cm. from the skin), or if it is located in a noncritical

anatomic area.⁽¹⁶⁾ Bernardino et al. use computed tomography for guidance for all small deep seated renal abscess (less than 5 cm.), and lesions in critical anatomic areas.⁽²⁷⁾ We had only 1 patient treated by sonographic guided aspiration. However, we agreed with the other authors that early diagnosis and early treatment with aggressive appropriate antibiotics and percutaneous aspiration for specific bacteriologic proof are the main goals of management of the renal abscess.

CONCLUSIONS

Although renal abscess is uncommon, 17 cases presented have been seen within a period of five and a half years. Renal abscess must be considered in any patient presenting with flank pain and fever, especially in female patient with diabetes mellitus. Assessment of renal abscess can be a difficult diagnostic problem. Excretory urography, sonography and computed tomography are important diagnosis and management of these patients. Excretory urography is usually the initial examination and reveal a mass in the kidney. With the advent of sonography and computed tomography, diagnosis of renal abscess may become less difficult. Sonography is a non-invasive and nonexpensive method which is helpful in the evaluation of renal mass. Sonographically, abscesses are hypoechoic masses with increased through-transmission and thick irregular walls or capsules. If sonographic findings indicate a typical abscess, treatment should be instituted ; if not the lesion can be double-checked with computed tomography. Computed tomographic findings of renal abscesses are a round soft tissue of low attenuation with a surrounding inflammatory wall of slightly higher attenuation and enhancement of the wall. When a patient is acutely or critically ill with suspicion of renal abscess, the preferred initial examination is computed tomography which can provide the most precise anatomic location of the lesion. A trial of conservative treatment with aggressive intravenous antibiotic therapy should be done first. If the patient has an acceptable response to intravenous antibiotics, the lesion may be followed by serial sonography. A percutaneous aspiration and drainage should be done in a patient with questionable nature of renal mass, with extension of the renal abscess beyond kidney or no improvement after intensive antibiotic treatment.

References

1. Godec DJ, Tsai SH, Smith SJ, Cass AS. Diagnostic strategy in evaluation of renal abscess. *Urology* 1981 Dec ; 18 (6) : 535-41
2. Morgan WR, Nyberg LM. Perinephric and intrarenal abscesses. *Urology* 1985 Dec ; 26 (6) : 529-36
3. Bova JG, Arevalos PE, Hopens T, Goldstein HM, Radwin HM. Renal and perirenal infection : The role of computerized tomography. *J Urol* 1985 Mar ; 133 (3) : 375-8
4. Gelman ML, Stone LB. Renal carbuncle : early

- diagnosis by retroperitoneal ultrasound. *Urology* 1976 Jan ; 7 (1) : 103-7
5. Elkin M. Renal cyst and renal abscess. *Curr Probl Diagn Radiol* 1975 ; 5 (1) : 1-56
 6. Graves RC, Parkins LE. Carbuncle of the kidney. *J Urol* 1936 Jan ; 35 (1) : 1
 7. Timmons JW, Perlmutter AD. Renal abscess : a changing concept. *J Urol* 1976 ; 115 : 299
 8. Sharma SK, Kumar A, Sharma BK, Malik N, Fadnis P. Intrarenal gas abscess. *J Urol* 1986 Nov ; 136 (5) : 1059-60
 9. Evans JA, Meyers MA, Bosnlak MA. Acute renal and perirenal infections. *Semin Roentgen* 1971 Jul ; 6 (3) : 274-91
 10. Rabinowitz JG, Kinkhabwala MN, Robinson T, Spyropoulos E, Becker JA. Acute Renal Carbuncle. 1972 Dec ; 116 (4) : 740-8
 11. Simpkins KC, Barraclough NC. Renal cortical abscess, perinephritis and perinephric abscess in diabetes. *Br J Radiol* 1973 Jun ; 46 (546) : 433-6
 12. Klein DL, Filpi Rg. Acute renal carbuncle. *J Urol* 1977 Dec ; 118 (6) : 912-5
 13. Hantman IE, Berger BW. Non surgical treatment of renal cortical abscesses. *Urology* May 1981 ; 17 (5) : 415-9
 14. Morehouse HT, Weiner SN, Hoffman-Tretin JC. Inflammatory disease of the kidney. *Semin Ultras, CT and MR* 1986 Sep ; 7 (3) : 246-58
 15. Morehouse HT, Weiner SN, Hoffman JC. Imaging in inflammatory disease of the kidney. *AJR* 1984 Jul ; 143 (1) : 135-4
 16. Kuligowska E, Newman B, White SJ, Caldacone A. Interventional ultrasound in detection and treatment of renal inflammatory disease. *Radiology* 1983 May ; 147 (2) : 521-
 17. Goldman SM, Minkin SD, Naraval DC, Diamond AB, Pion SJ, Meringoff BN, Sidh SM, Sanders RC, Cohen SP. Renal carbuncle. The use of ultrasound in its diagnosis and treatment. *J Urol* 1977 Oct ; 118 (4) : 525-8
 18. Mcdonough WD, Sandler CM, Benson GS. Acute focal Bacterial nephritis : Focal pyelonephritis that may simulate renal abscess. *J Urol* 1981 Nov ; 126 (5) : 670-73
 19. Hoddick W, Jeffrey RB, Goldberg HI, Federle MP, Laing FC. CT and sonography of renal and perirenal infections. *AJR* 1983 Mar ; 140 (3) : 517-20
 20. Funston MR, Fisher KS, Blerk PJPV, Bortz JH. Acute focal bacterial nephritis or renal abscess, A sonographic diagnosis. *Br J Urol* 1982 Oct ; 54 (5) : 461-6
 21. Balfe DM, McClennan BL, Stanley RJ, Weyman PJ, Sagel SS. Evaluation of renal masses considered indeterminate on computed tomography. *Radiology* 1982 Feb ; 142 (2) : 421-8
 22. Poppel HV, Vereecken RL, Wilms G. Bilateral renal cell carcinoma diagnosed as renal abscesses. *Urology* 1985 May ; 25 (5) : 548-50
 23. Rauschkolb EN, Sandler GM, Patel S, Childs TL. Computed tomography of renal inflammatory disease. *J Computed Assist Tomogr* 1982 Jun ; 6 (3) : 502-6
 24. Reiber K, Leventhal I. Splenic abscess as complication of perinephric abscesses. *Urology* 1987 Sep ; 30 (3) : 269-71
 25. Zatuchni J, Patel HK, Torres V. Renal subcapsular abscess. *Urology* 1986 Apr ; 27 (4) : 368-70
 26. Kaneti J, Hertzanu Y. Renal abscess owing to salmonella septicemia : Percutaneous drainage. *J Urol* 1987 Aug ; 138 (2) : 395-6
 27. Bernardino ME, Baumgartner BR. Abscess drainage in the genitourinary tract. *Radiol Clin North Am* 1986 Dec ; 24 (4) : 539-49