

First report on a natural infection of an adult snake-headed fish (*Ophicephalus striatus*) with a presumably *Gnathostoma vietnamicum* advance third - stage larva (Le-Van-Hoa, 1965) in southern Thailand.

Paisal Yingyourd*

Boonsong Chiamratana**

Svasti Daengsvang**

Yingyourd P, Chiamratana B, Daengsvang S. First report on a natural infection of an adult snake-headed fish (*Ophicephalus striatus*) with a presumably *Gnathostoma vietnamicum* advance third - stage larva (Le-Van-Hoa, 1965) in southern Thailand. *Chula Med J* 1990 Jul; 33 (7) : 543-548

*An encysted gnathostome larva was discovered in the abdominal flesh of an adult snake-headed fish caught from a fresh-water canal at Nakornsri thamarat province. The larva was identified as presumably a *G.vietnamicum* advance third-stage. This is the first report on a natural infection of this fish in Thailand. The authors now believe that to complete the life cycle of *G.vietnamicum*, two intermediate hosts may be needed before the adult can develop in an otter's urinary system. In addition, this report describes the external morphological structures of the worm which is worth noting in order to differentiate worms discovered in animals and man from *G. spinigerum* and from other gnathostomes.*

Reprint request : Yingyourd P, Department of Parasitology, Faculty of Medicine, Chulalongkorn University. Bangkok 10330, Thailand.

Received for publication. April 19, 1990.

* Department of Parasitology, Faculty of Medicine, Chulalongkorn University.

** Department of Helminthology, Faculty of Tropical Medicine, Mahidol University.

ไพศาล ยิ่งยวด, บุญส่ง เจียมรัตนะ.สวัสดิ์ แดงสว่าง, รายงานการติดเชื้อมีพยาธิตัวจิ๋วชนิด เวียดนามมีคัม ในปลาช่อนตามธรรมชาติ พบครั้งแรกในภาคใต้ของเมืองไทย. จุฬาลงกรณ์เวชสาร 2533 กรกฎาคม; 34(7): 543-548

รายงานผลการตรวจปลาช่อนจากจังหวัดนครศรีธรรมราช พบว่าที่เนื้อหนังของปลามีพยาธิตัวหนึ่งอยู่ ภายในถุงหุ้ม สันนิฐานได้ว่าเป็นพยาธิตัวอ่อนระยะที่สามของ *Gnathostoma vietnamicum* นับเป็นการพบตามธรรมชาติครั้งแรกของเมืองไทย จากการพบครั้งนี้พอที่จะเชื่อได้ว่าวงจรชีวิตที่สมบูรณ์ของพยาธิชนิดนี้ต้องการโฮสต์ กึ่งกลาง 2 ตัว ก่อนที่จะเจริญเติบโตเป็นพยาธิโตเต็มวัย อยู่ในระบบขับถ่ายของนก อนึ่ง ในรายงานนี้ได้บรรยายเกี่ยวกับรูปร่างลักษณะของพยาธิที่พบ ซึ่งมีคุณค่าสำหรับการวินิจฉัยแยกชนิดของพยาธิตัวจิ๋ว ที่ตรวจพบในคนและสัตว์ต่อไป

Adult males and females including the larval stage of *G.vietnamicum* were first found naturally infecting the renal pelvis of the otters (*Lutra elioti*, Hogson) obtained from the Saigon Zoological Garden in Vietnam Le-Van-Hoa (1965)⁽¹⁾ and Le-Van-Hoa et al. (1965).⁽²⁾ Subsequently Daengsvang (1973)⁽³⁾ reported that adult males and females and presumably larval stage of the worm were also naturally infecting kidneys, ureters and a urinary bladder of the otters, *Aonyx (Amblonyx) cinerea*, Illiger in Thailand. The result of the preliminary study on its life cycle then showed the fresh-water cyclops acting experimentally as the first intermediate host. Additionally one living undeveloped larva was found in the stomach wall of one of the two fighting fish on necropsy 21 days after being experimentally fed with 16 fully developed larvae of the worm in cyclops.

During a survey to determine sources of *G. spinigerum* infection in southern Thailand, an encysted living gnathostome larva was discovered in the abdominal flesh of an adult snake headed fish (*O. striatus*) caught from a fresh-water canal at Nakornsri thamarat province. The larva found in the fish was of the same morphological characteristics as the presumably *G.vietnamicum* larvae from the kidney and urether of the otters.⁽³⁾

This report describes the external morphological structures of a presumably *Gnathostoma vietnamicum* advance third - stage larva microscopically.

Materials and Methods

An adult snake - headed fish identified as

Ophicephalus striatus caught from a fresh - water canal at Nakornsri thamarat province was examined for the presence of gnathostomes by the impression method. An encysted coiled gnathostome larva was discovered in the abdominal flesh of the fish. This cyst was more or less rounded in shape measuring 1.25 mm. in diameter and the wall consisted of thin fibrous-like semitranslucent tissue. The larva was removed from the cyst and placed in normal saline, and then washed.

The gnathostome found was grossly and microscopically studied in living condition and some days after, it was fixed in A.F.A. solution. Measurements were also made after the worm was fixed. Observations for detailed morphology of the worm were done by a light microscope.

Results

Microscopically the larva was identified tentatively as *G.vietnamicum* advance third-stage. Morphological larva was cylindrical and slightly tapered at its posterior end. The size of the larva was 3.2 mm. in length and 0.15 mm. in width and the length-width proportion of this larva was found to be about 21:1 (Fig. 1). The larva showed a cephalic bulb covered with four rows of hooklets of which the first and the fourth rows were obviously smaller and shorter than those of the other two rows. The average sizes of the hooklets in microns were 6.8×2.1 , 6.2×2.2 and 9.2×4.9 , 10.8×4.3 respectively for the above-mentioned rows. The numbers of hooklets were 44, 45, 46 and 43 on rows 1-4 respectively (Fig. 2)

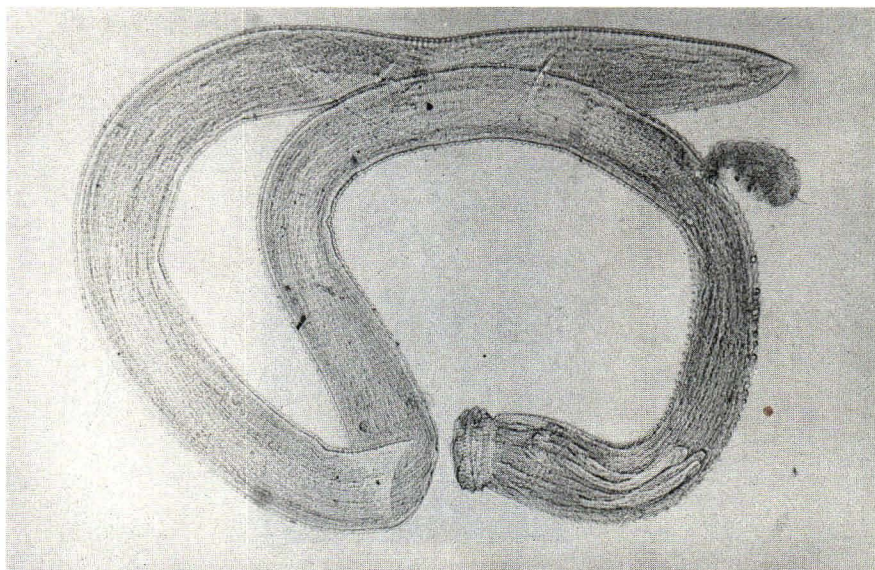


Figure 1. Photomicrograph of a slender larva of the presumed *G.vietnamicum* advance third stage obtained from a snake-headed fish measuring 3.2×0.15 mm. H (head), T (tail), B (body), C (cervical sac).

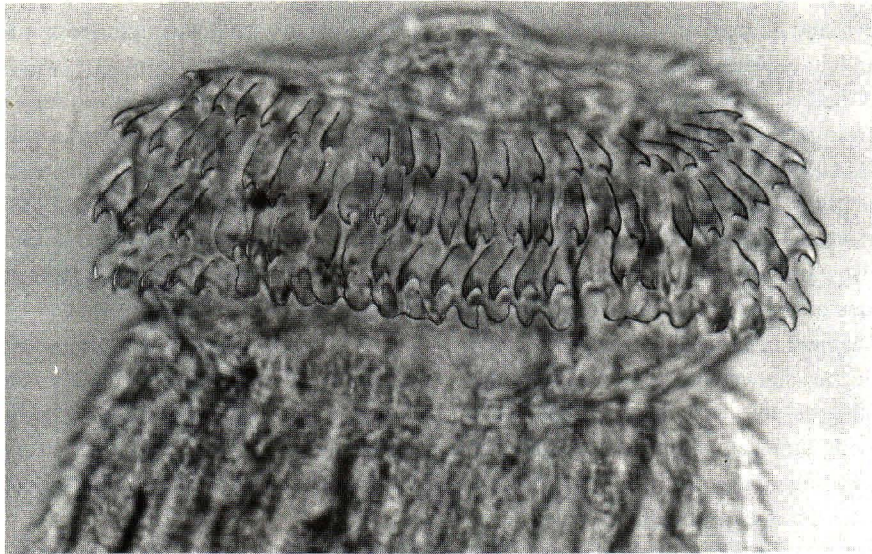


Figure 2. Photomicrograph presumably of the *G.vietnamicum* cephalic bulb being crowned with four rows of different numbers and sizes of hooklets (L,lips; H,hooklets; N,neck; B,body.)

The body cuticle had regularly arranged transverse rows of small numerous single-pointed cuticular spines pointing posteriorly with wide spaces between them. These were similar to those previously described for the larval stages found in the urinary system of the otter by Daengsvang (1973)⁽³⁾ These spines were more frequent at the anterior end of the body and gradually

decreased in number but increasing in size posteriorly. A short distance thereafter they diminished in size and number and were hardly seen beyond the middle part of the body by the light microscope. Each spine in the short distance of the anterior part of the body except at the neck area, showed T-shaped character with a long single posteriorly-pointed end and a wide conspicuous base (Fig. 3).

Anterior

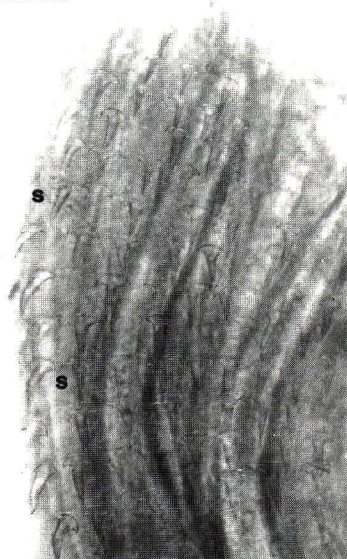

Figure 3. Photomicrograph showing T-shaped character of body cuticular spines, S each with a long single posteriorly-pointed end and a wide conspicuous base at the anterior body cuticular area of the presumably *Gnathostoma vietnamicum* advanced third - stage larva.

Discussion

The authors hope to confirm the identification of this larva of presumably the *G. vietnamicum* advance third-stage pending further experimental proof by developing a fertilized egg obtained from the female worm to the same larval stage and morphology in the snake-headed fish etcetera, or by finding the adult worm in the definitive host after being fed with the same type of larva obtained from the intermediate host. Further study on the life cycle of this worm and the vertebrate hosts carrying the infective larval stage is worth continuing for the differentiation of worms discovered in vertebrates as to whether they are *G. Spinigerum* or from other gnathostomes, and for identifying the source of infection for the definitive host and man.

It is worthwhile to note that the larva is impressively slender in appearance due to its length - width proportion of approximately 21 : 1 thus easily recognisable from the same larval stage of other gnathostomes so far reported in the literature. More-over, it is reasonable to believe that the snake-headed fish and other kinds of fish and vertebrates eaten by otters could act as the second intermediate hosts of this worm. Thus, the problem should be worthy of further investigations to clarify the last unsolved part of the worm's life cycle. In

this respect, the authors wish to quote the findings of Lauhachinda⁽⁴⁾ on life history of the river otter in Alabama U.S.A. with emphasis on food habits as fresh-water fish made up the most important food of the river otter. He also found that river otters were infected with many adult *G. miyazakii* in the kidneys. Similar discoveries by Miller and Harkema.⁽⁵⁾ Fleming et al⁽⁶⁾ and Whelan et al⁽⁷⁾ with *G. miyazakii* in the kidney, suggested that the fish could potentially act as a second intermediate host of the kidney worm.

In conclusion the authors strongly believe that the abovementioned findings have given much support to the assumption on the would be life cycle of *G.vietnamicum* Le-Van-Hoa (1965) and *G.miyazakii* Anderson (1964)⁽⁸⁾ in needing two intermediate hosts before developing into an adult worm in the urinary system of the otter namely; cyclops (*Mesocyclops leuckarti*, Claus ect.) and fish (*O.striatus* ect.) as the first and the second intermediate hosts respectively. In this respect, the following brief diagram is presented herein for better understanding of the hypothetical life cycle of the worm. (Fig. 4). There is little doubt that the kidney worm of the same genus (*G.miyazakii*) occasionally reported infecting kidneys of otters in Canada and U.S.A. would show a similar life cycle.

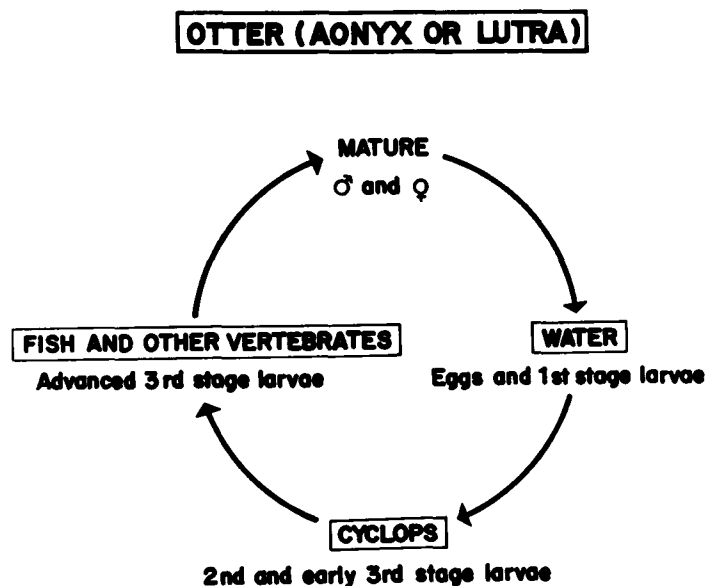


Figure 4. Diagram of the hypothetical life cycle of *G.vietnamicum* Le-Van-Hoa (1965) and *G. miyazakii* Anderson, (1964).

Acknowledgement:

The authors wish to thank Professor S. Vajrasthira and Associate Professor P. Setasuban the former and present Heads Department of Helminthology respectively, Faculty of Tropical Medicine, Mahidol University for their full support and approval of this study as well as for publishing. Also deep appreciations are extended to Dr. V. Lauhachinda, Department of Zoology,

Faculty of Science, Kasetsart University for the loan of his Ph. D. dissertation and many specimens of the worm (*G.miyazakii*) for the comparison with our presumed *G. vietnamicum* and for donation to the museum of the Faculty. Grateful acknowledgement is also extended to Associate Professor P. Kraivichian, Head Department of Parasitology, Faculty of Medicine, chulalongkorn University for his kind hospitality and full consent to this report.

References

1. LE-Van-HOA. Etude d'un nouveau gnathostome *G. vietnamicum* n. sp. chez *Lutra elioti* du Viet-Nam Bull Soc Path Exot(in Franch with English summary) 1965;58:228
2. Le Van Hoa, Nguyen Yan Ai, Ta-Van-Luyen. *Gnathostoma* et gnathostomose humaine au Viet-Nam Bull Soc Exot 1965; 58 : 236 (in France with English summary)
3. Daengsvang S. First report of *Gnathostoma vietnamicum* Le-Van-Hoa 1965 from urinary system of otters (*Aonyx Cinerea*, Illiger) in Thailand. Southeast Asian J Trop Med Public Health 1973 Mar; 4 (1):63-70
4. Lauhachinda V, Life History of the River Otter in Alabama with Emphasis on Food Habits. Ph.D. Dissertation, Auburn University. Auburn, Alabama. 1976.
5. Miller GC, Harkema R. Helminths of some wild mammals in southeastern United States. Proc Helminth Soc Wash 1968;35:118
6. Fleming WJ, Dixon CF, Levett JW. Helminth parasites of river otters (*Lutra canadensis*) from southeastern Alabama. Proc Helminth Soc Wash 1968;35:118
7. Whelan J, Anderson-Bledson KL, Scanlon PF. Prevalance of kidney worm (*Gnathostoma miyazakii*) in river otters (*Lutra canadensis*) in Virginia. Can J Zool 1983;61:1934
8. Anderson RC. *Gnathostoma miyazakii* n. sp. from the otter (*Lutra canadensis*) with comments on *G. sociale* (Leidy 1858) of mink (*Mustela vison*) Can J Zool 1964;49:249