

Ultrasound diagnosis of hepatic mass in infancy and childhood.

Darunee Boonjunwetwat*
Surang Suphanich*

Boonjunwetwat D, Suphanich S. Ultrasound diagnosis of hepatic mass in infancy and childhood. Chula Med J 1989 Oct; 33(10) : 791-799

Hepatic ultrasonography of eight infants and children with hepatomegaly are presented. Ultrasonography plays an important role in the differential diagnosis of hepatic lesion into parenchymal disease or mass. The advantages of ultrasound in infancy and childhood include easy and noninvasive procedure, low cost, lack of ionization and independence of organ function. In case of hepatic mass, ultrasound clarifies the nature of the mass as cystic, solid or complex. Ultrasonographic features of these eight cases were evaluated. The specific diagnosis of the pathology could be established by demonstrating some characteristic echogenic patterns of the masses, feeding vessels and calcification.

Reprint request : Boonjunwetwat D, Department of Radiology, Faculty of Medicine, Chulalongkorn University, Bangkok 10330, Thailand.

Received for publication. April 1, 1989.

ครุณี บุญยืนเวทวัฒน์, สุรางค์ สรรพพานิช. การวินิจฉัยโรคก้อนของตับในทารกและเด็กโดยคลื่นเสียงความถี่สูง. จุฬาลงกรณ์เวชสาร 2532 ตุลาคม; 33(10) : 791-799

รายงานนี้ได้เสนอผู้ป่วยทารกและเด็ก จำนวน 8 ราย ซึ่งมีปัญหาของตับโตอัลตราซาวด์เป็นวิธีการตรวจที่ดีและเหมาะสมที่สุด เพราะเป็นการตรวจที่ทำได้ง่าย ไม่ทำให้เกิดความเจ็บปวด ไม่ต้องคำนึงถึงการทำงานของอวัยวะที่ตรวจและปราศจากการใช้รังสี สามารถวินิจฉัยแยกโรคว่าเป็นโรคของเนื้อตับหรือเป็นก้อนในตับ อัลตราซาวด์สามารถบ่งชี้เฉพาะลงไปถึงพยาธิสภาพของก้อน ได้แก่เป็นถุงน้ำ, ฝี, ก้อนเนื้อ, หรือเป็นก้อนที่มีเนื้อและน้ำ การวิเคราะห์ลักษณะภาพอัลตราซาวด์ของก้อนแต่ละชนิดที่แตกต่างกันไป พบว่าบางครั้งสามารถแยกชนิดของก้อนเนื้อว่าเป็นเนื้องอกธรรมดา หรือเป็นมะเร็ง โดยลักษณะเฉพาะของ *echogenicity* ภายในก้อนเส้นเลือดที่มาเลี้ยงตัวก้อน หรือการตรวจพบหินปูนร่วมด้วย

Ultrasound should be performed first in infants and children presenting with hepatic enlargement. It helps to determine the nature of hepatomegaly whether it is a parenchymal disease or mass. In case of hepatic mass, ultrasound provides a great benefit in clarifying the nature of the mass as solid, cystic or complex.⁽¹⁾ The advantages of using ultrasound in childhood include noninvasiveness of procedure, low cost, lack of ionizing radiation, and independence of organ function.⁽²⁻⁴⁾ In addition, ultrasound can sometimes more specific in the diagnosis of the disease and the differentiation of benign from malignant lesion.⁽⁵⁾ This report presents a variety of ultrasonographic findings from eight cases with hepatic masses in childhood as follows : two cases of hepatoblastoma, one of malignant mesenchymoma , one hemangioendothelioma, two hepatic abscesses caused by amoebic and actinomyces infection, and two of hepatic metastasis from neuroblastoma. All cases were from Chulalongkorn Hospital during 1986-1988. Ultrasound was performed using real time linear array phase transducer 3.5-5 MHz. The technique used was subcostal and intercostal scans at right upper abdomen with the child supine and left oblique position. In the case of a noncooperating child, 50 mg/kg chloral hydrate was given for sedation. The purpose of this report is to evaluate the ultrasonographic features of hepatic mass in infancy and childhood that may help to establish the specific and differential diagnosis.

Case 1 Hepatoblastoma

A one year old boy presented with a palpable abdominal mass by his mother, and abdominal distension for one month. Physical examination revealed hepatomegaly 5 cm below right costal margin.

Liver function test showed mild elevation of TB, SGOT, and alkaline phosphatase levels. Alpha fetoprotein was positive and Hepatitis B antigen was negative.

Ultrasonographic findings : (Fig. 1)

The liver was enlarged with large inhomogeneous low and high echoic mass in lateral segment of left lobe liver. Sonolucent halo was seen surrounding the mass. The bile ducts were not dilated. The ultrasonographic findings suggests hepatoblastoma. The boy was operated and a large solid mass was found in lateral segment of left lobe. The histology was proved to be hepatoblastoma.

Case 2 : Hepatoblastoma

A seven month old boy was admitted with history of respiratory tract infection. Hepatomegaly was suspected from physical examination, and ultrasound of abdomen was performed.

The liver function test showed slight elevation of SGOT and alkaline phosphatase levels. Alphafetoprotein was negative.

Ultrasonographic findings : (Fig. 2) A large lobulated inhomogeneous high echoic mass was seen involving nearly

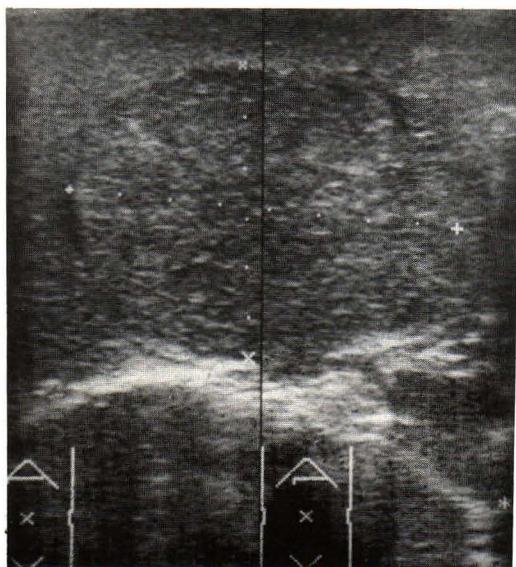


Figure 1. Hepatoblastoma

Transverse scan of liver showing a well defined inhomogeneous low and high echoic mass in lateral segment of left lobe liver with a thin sonolucent halo. (+ +)

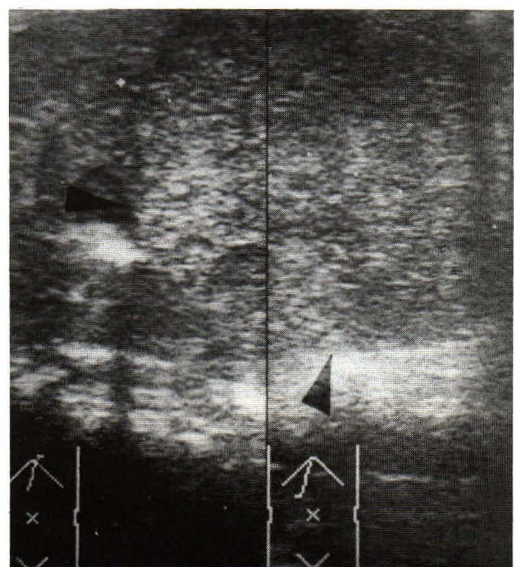


Figure 2. Hepatoblastoma

Oblique scan of liver showing an inhomogeneous high echoic mass in right lobe liver (A) The contour was lobulated with sonolucent halo.

the entire right lobe of the liver with sonolucent halo. No evidence of feeding vessels were demonstrated. The ultrasound diagnosis was most compatible with hepatoblastoma or hepatocellular carcinoma.

The pathology of the mass was after operation, proved to be hepatoblastoma.

Case 3 : Malignant mesenchymoma.

A seven-year old girl presented with jaundice, vague abdominal pain and progressive abdominal distension for two months.

Physical examination revealed mark hepatomegaly 4 cm. below right costal margin.

The liver function test showed marked elevation of TB, DB, and alkalinephosphatase levels. The SGOT and SGPT was relatively less elevated. The alphafetoprotein was negative.

Ultrasonographic findings : (Fig. 3) Marked hepatomegaly with a large inhomogeneous low and high echoic mass was seen in the right lobe of the liver. The mass contained multiple bright echos with posterior shadowing sugges-

tive of calcification. The outline of the mass was lobulated with a thin sonolucent halo. The mass extended into the porta hepatis causing dilatation of the left intrahepatic bile ducts and gall bladder. The ultrasound demonstrated massive calcification in the mass which was suggestive of mesenchymal tumor.

At surgery, a large lobulated solid mass was found in the right and caudate lobes with extension into the porta hepatis. The histologic finding came out to be malignant mesenchymoma.

Case 4 : Hemangioendothelioma.

A two-month old female was admitted with a problem of hepatomegaly from birth.

Laboratory findings were within normal limits.

Untrasonographic findings (Fig. 4) A large mixed inhomogeneous low and high echoic mass was seen in the right lobe of the liver. There were multiple small sonolucent areas in the mass with evidence of dilated vessels passing into the mass. Hemangioma or hemangioendothelioma was diagnosed by ultrasound. The differential

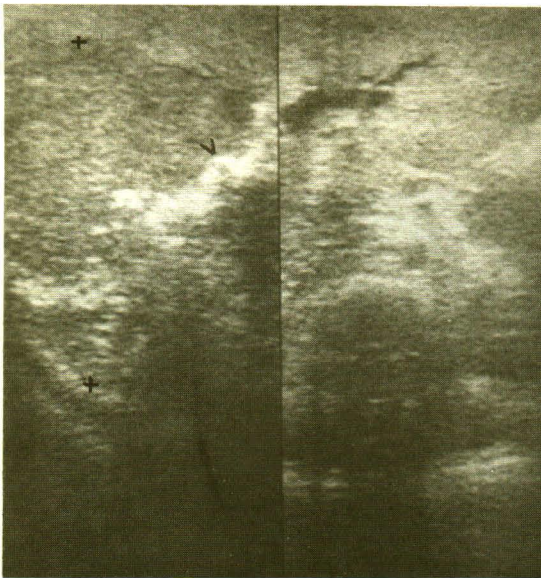


Figure 3. Malignant mesenchymoma

Transverse sonography of liver showing a large lobulated inhomogeneous low and high echoic mass in right lobe liver (+ +) containing massive calcification (arrow head), causing obstruction of left main hepatic bile duct and dilatation of left intrahepatic bile ducts.

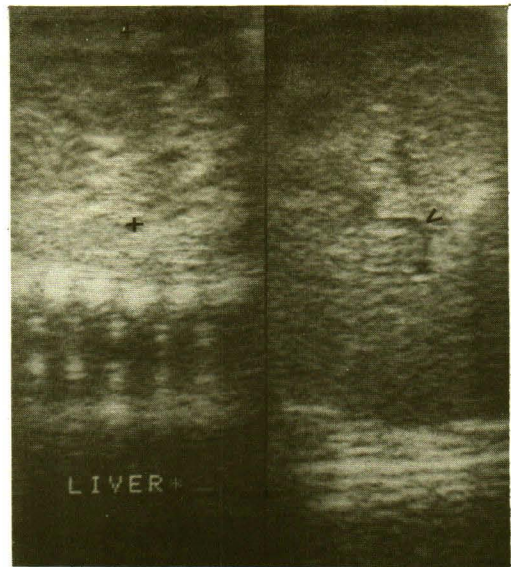


Figure 4. Hemangioendothelioma

Sagittal and transverse scans showing an inhomogeneous low and high echoic mass (+ +) with multiple small somolucent areas (arrows) in right lobe liver. A Dilated vessel was seen passing into the mass (arrow head)

diagnosis included vascular tumor or tumor with necrosis. A large vascular mass with numerous small vascular spaces was found in the right liver lobe at surgery, and histology proved it to be a hemangioendothelioma.

Case 5 : Hepatic amoebic abscess.

A nine-year old girl had a history of fever with right flank pain for one month. The physical examination revealed a fever of 38.8°C. The liver was enlarged 9 cm. below right costal margin with tenderness.

Laboratory findings showed leukocytosis with shift to the left. Only alkaline phosphatase level was mild elevated. Ultrasonographic findings : (Fig 5) A well defined round sonolucent area with some internal echoes and posterior enhancement was seen in the right liver lobe. The ultrasound findings indicated an abscess or infected cyst. The serologic study of E. hist titer was 1:256 (1:128) The girl was treated with metronidazole 800 mg/day for ten days. She responded well to the therapy. Follow up

ultrasound study of the liver showed a decreased size of the abscess.

Case 6 : Hepatic actinomycosis abscess

A five-year old boy was admitted with history of progressive abdominal distension for two months. The physical examination revealed hepatomegaly 5 cm. below right costal margin, with smooth liver surface.

The liver function test showed mild elevation of alkaline phosphatase level. Apphabetoprotein was negative.

Ultrasonographic findings : (Fig 6) The liver was enlarged with a mixed inhomogeneous low and high echoic mass in the right lobe. The margin was well defined with lobulated contour. The bile ducts were not dilated. No feeding vessels were demonstrated. A preferential diagnosis of a solid tumor was made most likely hepatoblastoma. Right hepatectomy was done and a solid mass was found in the right lobe. The diagnosis turned out to be hepatic abscess caused by actinomyces, proven histologically.

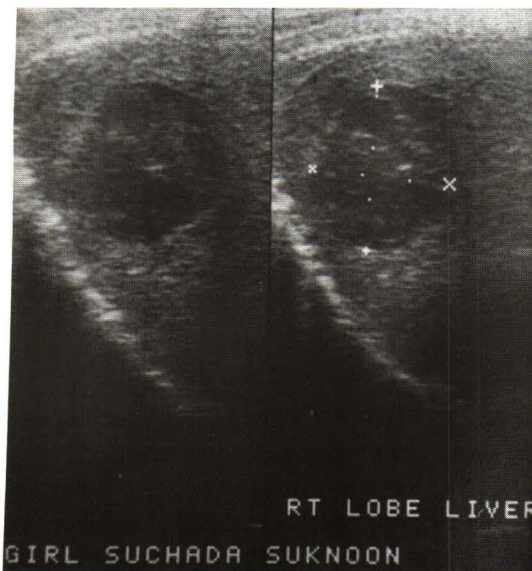


Figure 5. Hepatic amoebic abscess

Transverse scan showing a welldefined round sonolucent area with some internal echo in right lobe liver contiguous to right dome of diaphragm (+ +)

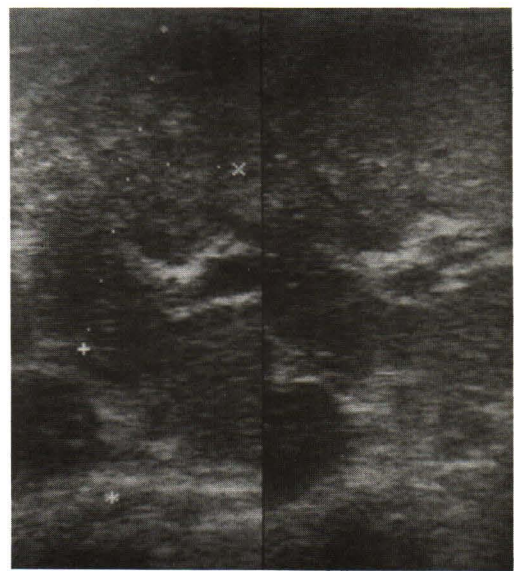


Figure 6. Hepatic actinomycosis abscess

Transverse scan showing an inhomogeneous low and high echoic mass in right lobe liver (+ +)

Case 7 : Hepatic metastases from neuroblastoma

A 5-month old boy presented with abdominal distension. The physical examination revealed large palpable mass in the right upper abdomen.

The alkaline phosphatase level was markedly elevated while SGOT and SGPT values were within normal limits.

Ultrasonographic findings : (Fig 7) The liver was enlarged with a diffuse, increased liver parenchymal echo. The bile ducts were not dilated. The findings were suggestive of a diffuse infiltrative disease.

Liver biopsy was done. The histology came out to be metastatic neuroblastoma.

Case 8 : Hepatic metastases from neuroblastoma

A 10 month-old girl presented with a history of palpable mass at the right upper abdomen for one month. Physical examination revealed hepatomegaly 7 cm. below the right costal margin with firm nodular surface.

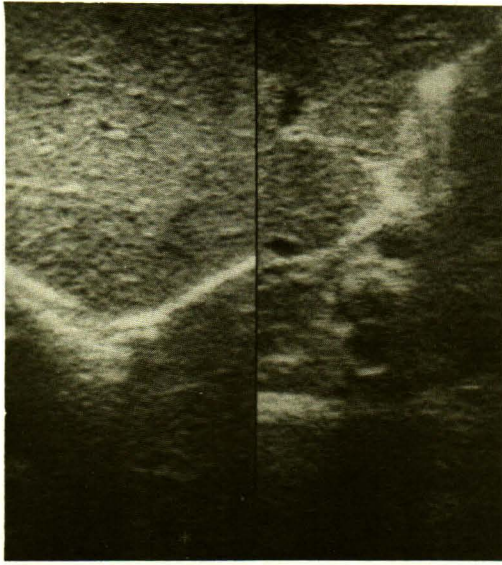


Figure 7. Hepatic metastases from Neuroblastoma
Transverse ultrasonography of liver showing hepatomegaly with diffusely increased echogenicity.

inferiorly. The differential diagnosis by ultrasound included neuroblastoma with liver metastases, hepatoblastoma or hepatocellular carcinoma.

Explore laparotomy was performed. A large solid mass was found at subhepatic area with extension into the right liver lobe and paraaortic lymph node enlargement. Biopsy was done. Neuroblastoma with liver metastases was diagnosed by pathologic report.

DISCUSSION

Eight cases of hepatic masses, four boys and four girls were presented. The age range was two months to nine years, with five cases under one year of age. The most common symptom was progressive abdominal distension, or palpable upper abdominal mass found in six of eight cases. The laboratory studies were of some value. The alkaline phosphatase level was elevated in seven cases, with relatively mild elevated or normal levels of TB, DB, SGOT and SGPT. The alpha fetoprotein was

The liver function test showed only mild elevation of alkaline phosphatase level. Alphafetoprotein was negative. Ultrasonographic findings : (Fig 8) : A large hyperechoic mass was seen in right liver lobe with extensive downward into right suprarenal area, displacing the right kidney

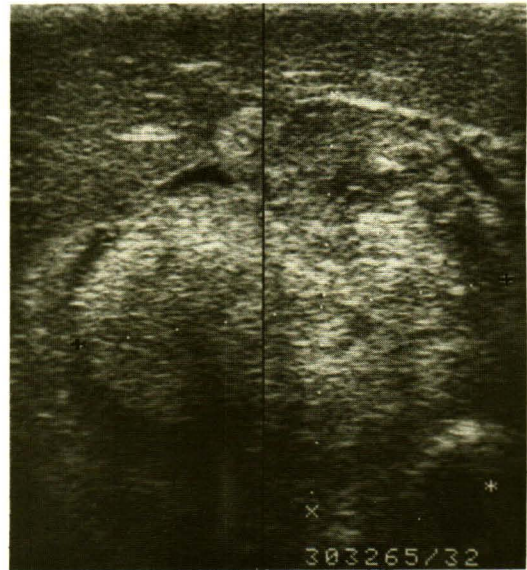

Figure 8. Hepatic metastases from neuroblastoma.
Transverse scan showing a large hyperechoic mass in right lobe liver extending downward to right suprarenal area (+ +)

positive in one case which helped to establish the diagnosis of hepatoblastoma or hepatocellular carcinoma.

A liver mass in infancy and childhood may be a consequence of a congenital anomaly, infection, trauma, or tumor.⁽⁶⁾ Primary tumors of liver are relatively uncommon, perhaps 1.5% of abdominal masses in children. Approximately two thirds are diagnosed in the first five years of life.⁽⁷⁾ Benign tumors comprise about a third of all primary liver tumors in childhood including hemangioma, hemangioendothelioma, hamatoma, focal nodular hyperplasia, and adenoma.^(6,8,9) Primary malignant tumors come third in frequency, exceeded by Wilm's tumor and neuroblastoma. Two major forms of malignant hepatic tumors are hepatoblastoma, and hepatocellular carcinoma.^(10,11) The ultrasonographic findings of hepatic masses are simply classified into five types as anechoic, hypoechoic, isoechoic, hyperechoic, and mixed echoic or complex mass. The anechoic mass is usually caused by cystic lesion. The hypoechoic, isoechoic and hyperechoic

masses suggest solid tumors, while a mixed echoic or complex mass implies a vascular tumor or mass with solid and cystic components.

A well defined anechoic or sonolucent mass with posterior enhancement indicates a cystic lesion. The differential diagnosis of a cystic lesion in the liver with thin or thick wall or septation or internal contents includes simple cyst, choledocal cyst, abscess, hematoma, biloma, cystic tumor or degenerative tumors. Congenital cyst is rare in pediatric age group presenting as a highly sonolucent mass with thin smooth echoic margin.⁽¹²⁾ Multiple cysts scattered throughout the liver, kidneys, pancreas, and lungs are characteristic of polycystic disease.⁽⁶⁾ Choledocal cyst is usually associated with biliary tree dilatation. Hepatic abscess although not commonly found in children, may complicate other diseases such as underlying immune impairment, sepsis, amoebic infection.^(5,6) Two cases of hepatic abscesses presenting in this series, amoebic abscess in one case showed a well defined round cystic lesion with some internal echoes; the other was caused by actinomycetes showing a complex mass, which could not be differentiated from other solid tumors. Ultrasonographic characteristics of amoebic liver abscess often show single well defined round or oval sonolucent area, in peripheral location contiguous to the liver capsule, and without an echogenic wall.⁽¹²⁻¹⁴⁾ While pyogenic abscess has been reported as single or multiple anechoic lesions containing variable amount of low level internal echoes, or septation with irregular thick wall.^(12,15,16) Abscess caused by fungal infection often associate with an underlying debilitating disease. The ultrasound feature of candidiasis involving the liver has been described as diffuse small round anechoic areas throughout the liver representing small abscesses.⁽¹²⁾

Mesenchymal hamartoma is a benign cystic tumor commonly found before two years of age, with male predilection.⁽¹⁷⁾ The ultrasound characteristic is an anechoic mass with internal septation and sometimes calcification, more commonly located in right lobe liver.⁽¹⁷⁻²¹⁾ As correlated with pathology, the tumor is usually composed of multiple cysts of various sizes filled with clear fluid or mucoid material. The cell linings contains proliferating bile ducts, blood vessels, lymphatic channels and lobules of hepatocytes.⁽⁹⁾

Malignant mesenchymoma reported in older children usually is a hypovascular mass, described ultrasonographically as an echogenic mass.⁽²²⁾ We present a case showing inhomogeneous echoic mass with massive calcification. Hepatic teratoma is another differential diagnosis which has been described as a mixed echoic pattern with calcification.⁽²³⁾ Pathologically teratoma is a tumor derived from all three germ layers composing of heterogeneous collection of tissue such as skin, muscle, fat, gut

epithelium, glandular structures, tooth structures and bone.⁽²³⁾

Hepatic hemangioma in children is a rare benign vascular malformation accounting for 10% of all primary hepatic masses.⁽²⁴⁾ The ultrasound feature of hemangioma has been described as an anechoic, hypoechoic, isoechoic, hyperechoic, or complex mass.⁽²⁵⁾ The characteristic pattern is a highly echogenic area with or without peripheral halo or surrounded by vessels.⁽²⁶⁾ Calcification is not so frequent as in mesenchymal hamartoma, or teratoma.⁽²⁷⁾

Hemangioendothelioma often shows a complex or mixed echoic mass with evidences of nutritive and draining vascular channels as presented in this series. Dilated proximal aorta, large draining hepatic veins, indicating A-V shunting or anechoic lakes are characteristic of the disease.⁽²⁸⁻³⁰⁾

Two most common hepatic malignant tumors in childhood are hepatoblastoma and hepatocellular carcinoma. Hepatoblastoma is found in infant and rarely seen after the age of three with male predominance.^(31,32) The elevation of serum alpha fetoprotein is found in two thirds of cases which is one of the most helpful diagnostic tests.⁽³¹⁾ The ultrasound feature often shows echogenic or complex mass without detectable nutritive or draining vessels as in hemangioendothelioma though it is a vascular tumor.^(33,34) The tumor predominantly contains epithelial cells of varying degrees of maturity. The mass is often well circumscribed with nodular or lobulated surface. Compression of normal hepatic parenchyma by the mass produces the peripheral halo in ultrasound.⁽³⁴⁾

Cystic hepatoblastoma is very rare, probably developing from aberrant bile ducts. The ultrasonographic appearance shows a cystic mass with internal septation.⁽³⁵⁾

Hepatocellular carcinoma is rare compared to the adult incidence and only 2% of childhood malignancies was reported.⁽³⁶⁾ The age incidence is found in two peaks, below four years and between 12-15 years with male predominance.⁽³³⁾ Of hepatocellular carcinoma, 40% had elevated alphafetoprotein. The common ultrasonographic feature, were echogenic or complex mass sometimes associated with central sonolucent area resulting from tumor necrosis.^(32,33) The tumor is also hypervascular but the nutritive or draining vessels are not seen.^(33,34) Calcifications are rarely visualised in these tumors.⁽²³⁾ Ultrasound showing peripheral halo is usually caused by presence of encapsulation of the tumor.⁽³⁶⁾ Other subtype of hepatocellular carcinoma occurring in younger patient is fibrolamella carcinoma. The tumor is composed of abundant granular, eosinophilic cytoplasm and broad interlacing bundles of tightly packed collagen which provides hyperechoic feature.⁽³⁶⁾

Metastasis to liver in childhood usually arises from leukemia, lymphoma, Wilms' tumor and neuroblastoma.^(5,6) The ultrasonographic features of liver metastases in adult, have varied echographic patterns such as hyperechoic, bull's eye or sonolucent.⁽³⁷⁾ Primary colonic tumor or mucin producing tumors provide hyperechoic or dense metastases. Sonolucent lesion is explained by tumor necrosis. Bull's eye lesion is caused by dilated, congested sinusoids around the focal metastatic deposit. Both sonolucent and bull's eye metastases are of non specific primary sites.⁽³⁷⁾ Compared to liver metastases in childhood leukemia and lymphoma usually produce hypoechoic metastases. Of the two cases of neuroblastoma with hepatic involvement in this series, one showed hyperechoic mass and the other hepatomegaly with diffuse increase of liver parenchymal echo. Ultrasonography of hepatic involvement from neuroblastoma usually shows focal areas of decreased echogenicity or ill defined diffuse areas of increased echogenicity. Particularly in younger infants, hepatic metastases may demonstrate only hepatomegaly with altered echogenicity

of parenchyma indicating diffuse liver infiltration.⁽³⁸⁾ Evidence of associated retroperitoneal suprarenal mass suggests neuroblastoma.

CONCLUSION

Ultrasound is a valuable investigation especially for hepatomegally presenting in infancy or childhood. It helps to differentiate between hepatic mass, parenchymal disease and biliary obstruction. In case of hepatic mass, ultrasound can easily discriminate between cystic, solid or complex mass. In addition, ultrasound sometimes provides the specific pathological diagnosis from characteristic ultrasonographic features of the mass presented. Hepatoblastoma and hepatocellular carcinoma often show hyperechoic mass with peripheral halo. The mass containing calcification is found frequently in mesenchymal tumor and teratoma. Cystic component in the mass or cyst with septation is also a feature of mesenchymal tumor. The evidence of demonstrated feeding or draining vessels, enlarged aorta and hepatic vein suggest a hemangioperithelioma.

REFERENCE

1. Brasch RC, Abols IB, Gooding CA, Filly RA Abdominal disease in children : a comparison of computed tomography and ultrasound. *AJR* 1980 Jan;134(1) : 153-8
2. Stevenson RJ. Abdominal masses. *Surg Clin North Am* 1985 Dec;65(6) : 1481-504
3. Kaude JV, Felman AH, Hawkins IF Jr. Ultrasonography in primary hepatic tumors in early childhood. *Pediatr Radiol* 1980; Feb 9(2) : 77-83
4. Holm HH, Gammelgaard J, Jensen F, Smith EH, Hillman BJ. Ultrasound in diagnosis of a palpable abdominal mass : a prospective study of 107 patients. *Gastrointest Radiol* 1982; 7(2) : 149-51
5. Madigan SM, Teele RL Ultrasonography of the liver and biliary tree in children. *Semin Ultrasound CT MR* 1984;5 : 68-84
6. Boechat MI, Kangar 100 H, Gilsanz V. Hepatic masses in children. *Semin Roentgenol* 1988 Jul; 23(3) : 185-93
7. Weinberg AG, Finegold MJ. Primary hepatic tumors of childhood. *Human Pathol* 1983; Jun 14(6) : 512-37
8. Holmin T, Kullendroff CM. Diagnostic aids for benign tumors of liver in childhood. *Acta Paediatr Scand* 1981; 70 : 755-57
9. Ehren H, Mahour GH, Isaacs H Jr. Benign liver tumors in infancy and childhood : report of 48 cases. *Am J Surg* 1983 Mar;145(3) : 325-9
10. Weinberg HG, Finegold MJ. Primary hepatic tumors in childhood. In : Boyd S, ed. *Pathology of Neoplasia in Children and Adolescents*. Philadelphia : W.B. Saunders, 1986. 333-72
11. Exekbt PR, Filler RM, Grossfield JL. Liver tumors in children in particular reference to hepatoblastoma and hepatocellular carcinoma : American Academy of Pediatrics Surgical Section Survey 1974. *J Pediatr Surg* 1975 Jun;10(3) : 329-37
12. Newlin N, Silver TM, Stuck KJ, Sandler MA. Ultrasonic features of pyogenic liver abscesses. *Radiology* 1981; Apr 139(1) : 155-9
13. Vajarapongse K, Wetchset-Nont D, Vajaragupta L; Buachum V, Lerdlum S. Ultrasonography of amoebic liver abscess. *Chula Med J* 1984 Sep; 28(9) : 973-83
14. Ralls RW, Meyers HI, Lapin SA, Rogers W, Boswell WD, Halls J. Grey-scale ultrasonography of hepatic amoebic abscess. *Radiology* 1979 Jul; 132(1) : 125-9
15. Kuligowska E, Connors SK, Shapiro JH. Liver abscesses sonography in diagnosis and treatment *AJR* 1982 Feb;138(2) : 253-57

16. Chusid MJ. Pyogenic hepatic abscess in infancy and childhood. *Pediatrics* 1978 Oct;62(4) : 554-9
17. Stanley P, Hall TR, Woolley MM, Diament MJ, Gil-sanz U, Miller JH. Mesenchymal hamartomas of the liver in childhood : sonographic and CT findings. *AJR* 1986 Nov;147(11) : 1035-9
18. Rosenbaum DM, Mindell HJ. Ultrasonographic findings in mesenchymal hamartoma of liver. *Radiology* 1981 Feb;138(2) : 425-7
19. Ros PR, Goodman ZD, Ishak RG, Dachman AH, Olmsted WW, Hartman DS. Mesenchymal hamartoma of liver : radiologic pathologic correlation. *Radiology* 1986 Mar;158(3) : 619-24
20. Smith WL, Ballantine TUN, Gonzalesz-Crussi F. Hepatic mesenchymal hamartoma causing heart failure in the neonate. *J Pediatr Surg* 1978 Apr; 13(2) : 183-5
21. Srouji MN, Chatten J, Schulman WM, Ziegler MM, Koop CE. Mesenchymal hamartoma of the liver in infants. *Cancer* 1978 Nov;42(5) : 2483-9
22. Stanley RD, Dehner LP, Hesker AE. Primary malignant mesenchymal tumors (mesenchymoma) of the liver in childhood : an anisographic-pathologic study of three cases. *Cancer* 1973 Oct; 32(4) : 973-84
23. Kraudel K, Williams CH. Ultrasound case report of hepatic teratoma in newborn. *J Clin Ultrasound* 1984 Feb;12(2) : 98-101
24. Cohen RC, Myers NA. Diagnosis and management of massive hepatic hemangiomas in childhood. *Pediatr Surg. Jan* 1986;21 : 6-9
25. Kaude JV, Felman AH, Hawkins IF Jr. Ultrasonography in primary hepatic tumors in early childhood. *Pediatr Radiol* 1980 Feb;9(2) : 77-83
26. Lahde IS, Pamilo M, Myllyla V, Leinonen A, Kairaluoma M. Ultrasound and computed tomography of small asymptomatic hemangioma of liver. *Acta Radiologica Diagn* 1982; 23 : 577-83
27. Abramson SJ, Lack EE, Teele RL. Benign vascular tumors of the liver in infants : sonographic appearance. *AJR* 1982 Apr;138(3) : 629-32
28. Stanley P, Gates GF, Eto RT, Miller SW. Hepatic cavernous hemangiomas and hemangioendotheliomas in infancy *AJR* 1977 Aug;129(2): 317-21
29. Slovis TL, Berdon WE, Haller JO, Casarella WJ, Baker DH. Hemangioma of the liver in infants : review of diagnosis, treatment, and course. *AJR* 1975 Apr 123(4) : 791-801
30. Dachman AH, Lichtenstein JE, Friedman AC, Hartman DS. infantile hemangioendothelioma of the liver : a radiologic-pathologic clinical correlation. *AJR* 1983 Jun;140(6) : 1091-6
31. Exelby PR, Filler RM, Grosfeld JL. Liver tumors in children in particular reference to hepatoblastoma and hepatocellular carcinoma : American Academy of Pediatrics Surgical Section Survey. 1974. *J Pediatr Surg* 1975 Jun;10(3) : 329-38
32. Amendola MA, Blane CE, Amendola BE, Glazer GM. CT findings in hepatoblastoma. *J Computer Assist Tomogr* 1984 Dec;8(6) : 1105-9
33. Miller JH, Gates GF, Stanley P. The radiological investigation of hepatic tumors in childhood. *Radiology* 1977 Aug;124(2) : 451-8
34. Dachman AH, Pakter RL, Ros PR, Fishman EK, Goodman ZD, Lichtenstein JE. Hepatoblastoma : radiologic pathologic correlation in 50 cases. *Radiology* 1987; 164(1) : 15-9
35. Miller JH. the ultrasonographic appearance of cystic hepatoblastoma. *Radiology* 1981 Jan;138(1) : 141-3
36. Farhi DC, Shikes RH, Murari PJ, Silverberg SG. Hepatocellular carcinoma in young people. *Cancer* 1983 Oct 15; 52(8) : 1516-25
37. Scheibel W, Gosink BB, Leopold GR. Grey scale echographic patterns of hepatic metastatic disease. *AJR* 1977 Dec;129(6) : 983-7
38. Bonsvaros A, Kinks DR. Imaging of neuroblastoma : an overview. *Pediatr Radiol* 1986 ; 16 : 89-106