

Value of Diagnostic Laparoscopy

Kobchitt Limpaphayom*

Wirach Wisawasukmongchol* Dumrong Rienprayoon*

Limpaphayom K, Wisawasukmongchol W, Rienprayoon D. Value of Diagnostic Laparoscopy. Chula Med J 1989 Jan; 33(1): 17-24

Laparoscopy was used as an ancillary method for diagnosis of intraabdominal pathology in 1518 cases at Chulalongkorn Hospital during January 1, 1983 to March 31, 1987 which accounted for 45.88% of all laparoscopy done here. Diagnostic laparoscopy was done if other clinical and laboratory parameters were inconclusive or not conclusive.

Infertility, endometriosis and pelvic inflammatory disease were the leading indications (980 cases) accounting for 64.55%. Preoperative evaluation for reversal sterilization were the next common indication (208), 13.70%. Under some conditions diagnostic laparoscopy eliminated the need for laparotomy. No special equipment is required for this procedure, which saves time, unnecessary payment, and gives benefit to certain group of patients.

Reprint request : Limpaphayom K, Department of Obstetrics and Gynecology, Faculty of Medicine, Chulalongkorn University, Bangkok 10500, Thailand.

Received for publication. March 1, 1988.

กอบจิตต์ ติมปพยอม, วิรัช วิศวกรรมงคล, คำรง เจริญประยูร. คุณค่าของการตรวจวินิจฉัยด้วยลาพารอสโคป. จุฬาลงกรณ์เวชสาร 2532 มกราคม; 33(1): 17-24

การใช้เครื่องมือลาพารอสโคปเพื่อการวินิจฉัยพยาธิสภาพในอุ้งเชิงกรานระหว่างวันที่ 1 มกราคม 2526 ถึง 31 มีนาคม 2530 มีทั้งหมด 1518 ราย คิดเป็นร้อยละ 45.88 ของการใช้เครื่องมือลาพารอสโคปทั้งหมดของช่วงระยะเวลาเดียวกับการวินิจฉัยด้วยการใช้เครื่องมือนี้ ทำเมื่อแพทย์มีความสงสัยในอาการทางคลินิกของผู้ป่วยและหรือ การตรวจทางห้องทดลองที่ยังไม่แน่นอน

ภาวะหรือกลุ่มอาการที่นำมาทำเพื่อการวินิจฉัยได้แก่ การเป็นหมัน โรค Endometriosis การอักเสบในอุ้งเชิงกรานคิดเป็นร้อยละ 64.55 (950 ราย) การตรวจประเมินหลอดมดลูกก่อนการแก้หมัน ร้อยละ 13.70 (208 ราย) การใช้เครื่องมือลาพารอสโคปเพื่อการวินิจฉัยนี้ สามารถลดการผ่าตัดเปิดช่องท้องได้ ร้อยละ 46.9 เครื่องมือที่ใช้เป็นเครื่องมือที่มีอยู่แล้ว ประหยัดเวลาค่าใช้จ่าย และสามารถช่วยลดระยะเวลาที่คนไข้ต้องอยู่เพื่อรับการรักษาในโรงพยาบาลได้

In Gynecology, a diagnosis made directly by actually seeing the lesion should be more accurate than one made indirectly with the use of blind procedure. The laparoscopic diagnosis can be such a direct method. The main indications for diagnostic laparoscopy are infertility, endocrine disorders, suspected tubal pregnancy, pelvic inflammatory processes, preoperative evaluations for reversal of sterilization, intraabdominal foreign bodies and primary amenorrhea.^(1,2,3) Diagnostic laparoscopy are widely used in women of reproductive age (15-45) but more commonly between the age of 26-35 years.⁽¹⁾ This procedure has been used to diagnose unknown problems, to follow the course of known disease, and to help make clinical judgement for major operation.^(4,5)

At Chulalongkorn Hospital, operative laparoscopic procedures are mainly utilized for female sterilization. There is an increasing list of operative procedures performed by experienced laparoscopist such as lysis of adhesion, cauterization of endometriotic spots, puncture of small ovarian cyst and oocyte aspiration for in vitro fertilization; these indications are increasing in the past year.

The purpose of this report is to present our experience in utilizing and establishing diagnosis with laparoscopy in various gynecologic disorders.

Materials and Methods

The 1518 patients in this series had diagnostic laparoscopy performed by the authors, other staff

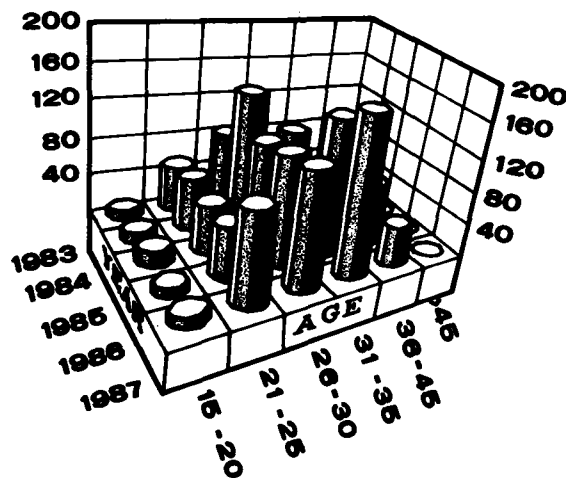
members and senior residents in family planning unit of the Department of Obstetrics and Gynecology, Chulalongkorn Hospital during January 1, 1983 to March 31, 1987. During this same period, a total of 3308 cases of both diagnostic and operative laparoscopies were performed. The percentage of diagnostic laparoscopy accounted for 45.88% of all cases.

The patients' ages varied from 15 to 50 years with the majority (64.2%) between 26-35 years (Table 1). The popularity of utilizing laparoscopy for diagnosis was increasing from 1983-1987.

A previous abdominal operation was not an absolute contra indication for laparoscopic examination. The authors utilized open laparoscopic technic in cases which had previous intraabdominal operation or suspected severe post operative adhesion to avoid trauma while entering peritoneal cavity for pneumoperitoneum or trocar insertion.^(6,7,8) There were 38 cases of open laparoscopy which accounted for 2.55% of all diagnostic cases.

All laparoscopies were performed under neuroleptanalgesia using pethidine 75 mg and diazepam 10 mg intravenously with local anesthesia. A single puncture technic was employed except for oocytes retrieval when a 2 hole technic was employed. In a case requiring chromopertubation, 1:1 diluted indigocarmine was instilled via modified Rubin's canula inserted into the cervix during diagnostic procedures.

Table 1 Age Distribution



Chulalongkorn Hospital

Results

A summary of indications is presented in table 2. The leading clinical indications are infertility endometriosis and pelvic inflammatory disease, accounting for 64.55%.

Of 345 cases with clinical diagnosis of endometriosis using the classification of disease according to the American Fertility Society, 97.4% are confirmed and only 2.6% are normal. (Table 3)

Table 2. Indications for Diagnostic laparoscopy.

Case	%	
Infertility	444	29.24
Clinical Endometriosis	345	22.72
Pelvic Inflammatory disease	191	12.58
Preoperative evaluation for reversal of sterilization	208	13.70
Suspected Ectopic Pregnancy	113	7.44
Chronic Pelvic Pain	59	3.88
Suspected Pelvic Mass	50	3.29
Primary Amenorrhea	33	2.17
Ovum Retrieval	54	3.55
Removal of intrauterine device perforation	11	0.72
Relaparoscope for post tubal reanastomosis	7	0.46
Relaposcope after medical treatment of endometriosis GIFT	1	0.06
Suspected H. Mole Perforation	1	0.06
	1	0.06
1518	100%	

Table 3. Laparoscopic Diagnosis of Pelvic Endometriosis.

Normal Pelvic Organ	10	
Mild Endometriosis	182	
with Endometriosis, at uterosacral ligament or ovary		128
with fimbrial adhesion		54
Moderate endometriosis	137	
with bilateral tubal patency		85
with unilateral tubal patency		30
with endometrioma		12
with peritubal adhesion		10
Severe endometriosis	60	
with bilateral tubal obstruction		27
with Cul de sac obliterate and severe pelvic abhesion		9
with endometriotic cyst > 4 cm		24

* Total number of 389 cases is not equal to indicated cases because the diagnosis was made from other indications.

One hundred and thirteen cases were suspected of tubal pregnancy; 53.07% or half of the cases were confirmed and, 46.9% spared from major operation. (Table 4)

Table 4. Laparoscopic diagnosis in patients with suspected ectopic pregnancy.

	Case	%
Laparoscopic diagnosis	113	
Ectopic Pregnancy		
Unruptured	44	38.93
Tubal abortion	14	12.38
Ruptured	2	1.76
Normal Pelvic organ	26	23.00
Intrauterine pregnancy	3	2.65
Incomplete Abortion	4	3.53
Functional Ovarian Cyst	20	17.69

Preoperative tubal evaluation in all patients seeking reversal of sterilization, is shown in Table 5.

Table 5. Preoperative evaluation of Tubal reanastomosis.

Tubes were cut at :

Isthmic-isthmic portion
Isthmic-Ampullary
Ampullary-Ampullary
Fimbriectomy
Post electrocavagulation
Too short tubes

Case	%
40	19.23
25	12.01
22	10.57
38	18.26
27	12.98
56	26.92
208	100%

Out of all diagnostic cases for various indications, 216 cases or 14.22% were found laparoscopically normal. (Table 6)

There were diagnostic procedures for females aged 20 or below and 35 or above with indications and findings summarized in Table (7,8,9,10). The youngest age was 15 and the oldest 50.

Table 6. Normal Pelvic organ from laparoscopic diagnosis.

	Total	Cases of Normal
Suspected infertility	444	76
Suspected endometriosis	345	10
Suspected chronic pelvic inflammatory disease	191	37
Suspected ectopic pregnancy	113	26
Chronic pelvic pain	59	39
Suspected pelvic mass	50	28
		(14.22%)

Table 7. Indications and finding for age 20 or less (52 cases).

Clinical Indication Diagnosis	Normal finding	Mild endometriosis	Acute PID	unruptured Tubal Pregnancy	Small Functional cyst	Incomplete Mullerian Agenesis
Endometriosis	3	2	-	-	-	-
Chronic Pelvic Pain	8	1*	4	-	3	-
Suspected Ectopic Pregnancy	8	-	6	7	-	-
Primary Amenorrhea	-	-	-	-	-	10

N.B.* Youngest age 15 had chronic pelvic pain and found endometriosis at both ovaries and uterosacral ligaments.

Table 8. Indications and finding in age over 35.

	Total	Normal finding	Pathological finding
Infertility	138	17	121
Endometriosis	72	-	72
	210	17	193
	100%	8.09%	

Table 9. Pathological finding for infertility age over 35.

Mild chronic PID	7
Myoma uterine with bilateral tubal patency	25
Multiple myoma uterine with tubal blockage	19
Chronic PID with pelvic adhesion	50
Post operative adhesion	8
Ovarian cyst	2

Table 10. Endometriosis in age over 35

Mild endometriosis	20
Moderate endometriosis	15
Severe endometriosis	37

There were 33 cases of primary amenorrhea in the age group 15-30 years. (Table 11)

Table 11. Primary amenorrhea (age 15-30).

Mullerian agenesis	11
Incomplete mullerian agenesis	17
Uterine agenesis	1
Hypoplasia of uterus	1
Double uterus	2
Double cervix	1
Acquired absence of uterus	1

Lost IUDs were located and retrieved in 11 patients. All were wearing Lippe's loop size D, except one using Multiload. (Table 12)

Table 12. Removal of foreign bodies.

	Cases	Type of IUD
1983	4	All Lippe's Loop
1984	3	2 Lippe's Loop 1 Multiload
1985	1*	Lippe's Loop
1986	3	All Lippe's Loop

*W.B. This is the oldest age in this series, 50 years of who had 20 years of IUD insertion.

Discussion

Diagnostic laparoscopy gives a panoramic inspection of the pelvis, and has achieved wide spread use as a valuable diagnostic aid in gynecology. In this report, the prime problems leading to laparoscopic investigation are infertility. They included primary, secondary infertility, clinically suspected endometriosis and chronic pelvic inflammatory diseases accounting for 64.54% of 1518 patients (Table 2). This is equal to the series reported during 1970-1980.^(9,10)

As shown in Table 3, of 345 cases of clinically suspected cases of endometriosis, 97.4% were confirmed and only 2.6% had normal pelvic organ. Also we found more incidence of this disease than we suspected, 389 instead of 345 cases which was due to the critically examination of the pelvic cavity for other conditions, to more knowledge of pelvic anatomy and prior experience with direct visualization of pelvic endometriosis.

Laparoscopy is believed to be the most definitive diagnostic procedure available in cases of suspected ectopic pregnancy where no serum radioimmunoassay pregnancy is available. In this series we found 53.07% of unruptured ectopic pregnancy, tubal abortion and early ruptured cases which through this diagnostic procedure

we can avert the danger of intraperitoneal hemorrhage and permit more conservative surgery. Also 46.9% of suspected ectopic pregnancies after diagnostic laparoscopy were found to have normal pelvic organs which were saved from unnecessary exploratory laparotomy.

Preoperative evaluation for reversal of sterilization utilizing diagnostic laparoscopy provided an objective and accurate assessment of the status of tubes to be reanastomosed.^(3,12) In Table 5, although 41.81% of cases were eligible for tubal reanastomosis, some husbands, about 1/3, have problems when their semen were analysed.⁽⁸⁾ So only one third of all cases requesting reversal were able to have reanastomosis. The value of this procedure is in giving the gynecologic microsurgeon a chance to eliminate unsuitable cases for reversal of sterilization and thus a better success rate for pregnancy outcome.

There were 14.22% of normal pelvic organ from 1518 patients after diagnostic laparoscopy. This will avoid hospitalization cost, unnecessary operation, give higher benefit to patients and again spare unnecessary operation. (Table 6)

Diagnostic laparoscopy is also useful in and gives benefit to patients below 20 and over 35 in whom it will save time and offer cost benefit for them. In table 7, out of a total of 52 women age 20 or less having diagnostic laparoscopy, 36.53% had normal pelvic finding and 44.28% (mild endometriosis, acute PID and unruptured ectopic pregnancy) needed further treatment either medical or surgical to restore their reproductive ability. Also in this series we found the youngest age for clinically suspected endometriosis. (15 yrs)

Women age over 35 were believed to have

decreased reproductive ability. In this series, causes of infertility for this age group were categorized (Table 8-9-10). The authors suggested no further investigation in 91.9% of these cases, because fertility results will not have been cost-effective after further investigation and treatment.

Today, gynecologists can quickly resolve the variation of Mullerian development by laparoscopy.⁽¹³⁾ Those patients are spared undue cost of investigation. Table 11 shows 34 cases of different types of primary amenorrhea which were diagnosed at between 15-30 years of age, 10 cases having been diagnosed before the age of 20. (Table 7)

Lost IUDs were located and retrieved in 11 patients (Table 12). This is the well established method.^(2,14,15,16) This technic may also be used for the removal of lost intraabdominal drain. The oldest patient in this series was a 50 year old. Woman with 20 yrs of lippe's IUD insertion, the perforation having occurred at posterior uterine wall on the right side.

Conclusion

As laparoscopy becomes established as a routine aid in differential gynecologic diagnosis and therapy, we gynecologists become more familiar with some disease and its course. Many diagnosis could not be made easily and positively by the conventional procedures. This procedure offer reduction in costs and give more benefit to our patients.

Acknowledgements

The authors wish to thank Mrs. Vorarad Silpacharn for her typing this mamuscript.

References

1. American College of Obstetricians and Gynecologists. *Precis. II : An update in Obstetric and gynecology.* Chicago: Am Col Obstet Gynecol, 1981.
2. Brooks PG. The use of laparoscopy. In : Phillips JM, Downey CA, eds. *Endoscopy in Gynecology.* American Association of Gynecologic Laparoscopist. St. Louis Christian Board of Publication, 1978, 2-5
3. Limpaphayom. Tubotubal anastomosis for revesal of female sterilization in Thailand, *J. Reprod Med* 1986 Jul; 31(7) : 601-604
4. Duignan NM, Jordan JA, Coughlau BM : Logan-Edward R. One thousand cousecutive cases of diangostic laparoscopy. *J Obstet Gynecol Br Commonw* 1972 Nov; 79(11) : 1016-1024
5. Fear RE. Laparoscopy, a valuable aid in gynecologic diagnosis, *Obstet Gynecol* 1968 Mar: 31(3) : 297-309
6. Penfield AJ. Open Laparoscopy. In: Phillips JM, Downey CA, eds. *Endoscopy in Gynecology.* American Association of Gynecologic Laparoscopist. St. Louis Christian Board of Publication, 1978. 58
7. Hasson HM. Open laparoscopy : a report of 150 cases. *J Reprod Med* 1974 Jan; 12(6) : 234-236
8. Limpaphayom K, et al. A Comparative Study Open and Closed Laparoscopy for Female Sterilization. Presented at 3rd Research Fertility Investigator Meeting. Pattaya, Thailand Sep 29-30, 1984

9. Peterson EP, Behrmaan SJ. Laparoscopy of the infertile patient. *Obstet Gynecol* 1970 Sep; 36(3) : 363-367
10. Templeton AA, Kerr MG. An Assessment of laparoscopy as the primary investigation in the subfertile female. *Br J Obstet Gynecol* 1977 Oct; 84(10) : 760-762
11. American Fertility Society. The classification of Endometriosis. *Fertil Steril* 1979 Dec; 32(6) : 633
12. Jones HW Jr., Rock JA, eds. *Reparative and Constructive Surgery of the Female Genital Tract*. Baltimore : Williams & Wilkins, 1983.
13. Motashaw NR, Dastur A, Vaidya RM, Aloorkar M. Laparoscopy for resolving mullerian abnormality. *J Reprod Med* 1978 Jul; 21(1) : 20-23
14. Ben-Baruch G, Meuczer J, Frenkel Y, : Laparoscopy in the management of uterine perforation. *J Reprod Med* 1982 Feb; 27 (2) : 73-75
15. Levinson CJ, Hulka JF, Richardsdson DC. Laparoscopy. In: Schaefer G, Graber EA, eds. *Complications in Obstetric and Gynecologic Surgery*. Hagerstow: Harpes & Row, 1981. 281-298
16. Siegler AM. Removal of ectopic intrauterine contraceptive devices aided by Laparoscopy. *Am J Obstet Gynecol* 1973 Jan 15; 115 (2) : 8-160