

## Cytomegalovirus gastrointestinal disease in patients with AIDS: A case series

Akarin Hiransuthikul\*

Narin Hiransuthikul\*

**Hiransuthikul A, Hiransuthikul N. Cytomegalovirus gastrointestinal disease in patients with AIDS: A case series. Chula Med J 2016 Mar – Apr;60(2): 155 - 65**

*Cytomegalovirus (CMV) is an important opportunistic infection in patients with acquired immunodeficiency syndrome (AIDS), usually in those with low CD4 cell counts. CMV colitis is the most common CMV end-organ diseases after CMV retinitis, though cytomegalovirus the gastrointestinal disease (CMV-GID) can occur at any region of gastrointestinal tract. Its clinical manifestations depend on the region of gastrointestinal tract involved. However, due to indistinguishable clinical features from other diseases, further investigations, preferably endoscopy and histopathological testing, are necessary for diagnosis. Prompt diagnosis and treatment are vital to decrease mortality and reduce morbidity in an otherwise fatal disease. Our case series consist of 3 cases, each with different clinical spectra. All but one patient were antiretroviral (ARV)-naïve. Ganciclovir was administered to all patients, with clinical improvement.*

**Keywords:** *Acquired immunodeficiency syndrome (AIDS), colitis, cytomegalovirus (CMV), human immunodeficiency virus (HIV), enteritis, esophagitis.*

Reprint request: Hiransuthikul A. Department of Preventive and Social Medicine, Faculty of Medicine, Chulalongkorn University, Bangkok 10330, Thailand.

Received for publication. July 15, 2015.

อัครินทร์ หิรัญสุทธิกุล, นรินทร์ หิรัญสุทธิกุล. การติดเชื้อ Cytomegalovirus ในระบบทางเดินอาหารในผู้ป่วยโรคเอดส์: รายงานผู้ป่วย. จุฬาลงกรณ์เวชสาร 2559 มี.ค. - เม.ย.; 60(2): 155 - 65

Cytomegalovirus (CMV) เป็นสาเหตุของโรคติดเชื้อแทรกซ้อนที่สำคัญในผู้ป่วย *acquired immunodeficiency syndrome (AIDS)* โดยมักจะเกิดในผู้ป่วยที่มีระดับ CD4 ต่ำ การติดเชื้อ CMV ที่ลำไส้ใหญ่พบได้บ่อยมากที่สุดรองจากการติดเชื้อ CMV ที่จอตา อย่างไรก็ตามการติดเชื้อ CMV ในระบบทางเดินอาหารสามารถเกิดได้ที่ตำแหน่งอื่นเช่นเดียวกัน โดยอาการและอาการแสดงขึ้นอยู่กับตำแหน่งของระบบทางเดินอาหารเหล่านั้น อย่างไรก็ตามก็ดูอาการและอาการแสดงของการติดเชื้อ CMV ในระบบทางเดินอาหารมักจะไม่สามารถแยกจากสาเหตุจากโรคอื่น ๆ ได้ จึงมีความจำเป็นที่ผู้ป่วยจะต้องได้รับการตรวจเพิ่มเติมทางห้องปฏิบัติการ ไม่ว่าจะเป็นการส่องกล้องตรวจทางเดินอาหาร (*endoscopy*) หรือการส่งตรวจชิ้นเนื้อเพิ่มเติม (*histopathology*) การติดเชื้อ CMV สามารถทำให้เกิดอันตรายถึงชีวิตได้ ดังนั้นการวินิจฉัยโรคและการรักษาที่ไม่ล่าช้าจะสามารถลดอันตรายที่อาจเกิดจากโรคนี้ได้ ในรายงานผู้ป่วยฉบับนี้ ผู้เขียนได้นำเสนอผู้ป่วยที่มีลักษณะอาการและอาการแสดงที่แตกต่างกัน รวม 3 ราย มีผู้ป่วย 2 รายที่ยังไม่เคยได้รับยาต้านรีโทรไวรัส ผู้ป่วยทั้ง 3 รายมีอาการดีขึ้นหลังได้รับการรักษาด้วยยา *ganciclovir*

**คำสำคัญ :** *Acquired immunodeficiency syndrome (AIDS), colitis, cytomegalovirus (CMV), human immunodeficiency virus (HIV), enteritis, esophagitis.*

Cytomegalovirus (CMV) infection is common worldwide, with a prevalence of 50 - 80%.<sup>(1)</sup> CMV is a double-stranded DNA virus in the herpesviridae family. Infected individuals usually remain asymptomatic unless T-lymphocyte-mediated immunity is compromised such as in patients with acquired immunodeficiency syndrome (AIDS).<sup>(2-4)</sup> In patients with AIDS, CMV infection usually occurs in those with CD4 cell counts below 50 cells/ $\mu$ L. Diverse end-organ diseases ranging from retinitis, gastrointestinal diseases, pneumonia, to encephalitis have been reported.

CMV is a well-established cause of gastrointestinal diseases in patients with advanced human immunodeficiency virus (HIV) diseases.<sup>(5)</sup> CMV-gastrointestinal disease (CMV-GID) can occur in any region along the gastrointestinal tract; the colon is the most common region involved. CMV colitis is the second most common CMV end-organ disease in HIV-infected patients, behind only CMV retinitis.<sup>(6)</sup> We, hereby, report a case series of CMV-GID in patients with AIDS and present a brief literature review.

### Case Reports

**Case 1.** A 37-year-old female with underlying HIV infection for 5 years and history of pulmonary tuberculosis presented with 2 weeks of intermittent epigastric pain radiated to back, anorexia, and weight loss. Her concurrent medication included tenofovir (TDF), emtricitabine (FTC), efavirenz (EFV), and cotrimoxazole. The patient had poor adherence to her medication. On examination, there were multiple cervical lymphadenopathies and mild tender in the epigastrium. Her CD4 cell counts were 10 (7%) cells/ $\mu$ L and HIV RNA levels of 50,798 copies/mL. Esophagogastroduodenoscopy (EGD) revealed

esophageal ulcer with necrosis. The biopsy showed esophageal ulcer with scattered spindle cells showing both intranuclear and intracytoplasmic eosinophilic inclusions.

Intravenous ganciclovir was administered for 4 weeks. The patient's symptoms resolved after three weeks. The same antiretroviral therapy (ART) was continued throughout the admission with perfect adherence.

**Case 2.** A 39-year-old man was admitted to a private hospital because of persistent diarrhea for 20 - day duration. The patient had been well until 1 month before this admission, when dry cough and dyspnea developed. The diagnosis was *Pneumocystis jiroveci* pneumonia (PCP) with HIV infection (CD4 cell counts was 64 (6%) cells/ $\mu$ L). A course of oral cotrimoxazole, prednisolone, and fluconazole were prescribed. After 10 days of treatment, dry cough and dyspnea subsided; however, he developed pruritic maculopapular rashes and watery occasional-bloody diarrhea 2-3 times per day. Cotrimoxazole was switched to clindamycin and primaquine in suspicion of drug allergy. The patient came to the appointment 10 days later with decreased rashes, but persistent diarrhea; furthermore, fever and mild abdominal pain at periumbilical area occurred. Antibiotic-associated diarrhea (AAD) was suspected; thus clindamycin and primaquine were stopped, and ciprofloxacin with metronidazole were prescribed. On the day of this admission, the patient returned to the outpatient clinic because of persistent symptoms. In addition, he reported worse fever with fatigue, decreased appetite, and weight loss of 4 kg during the preceding month. He had no other comorbidities and received no other medication.

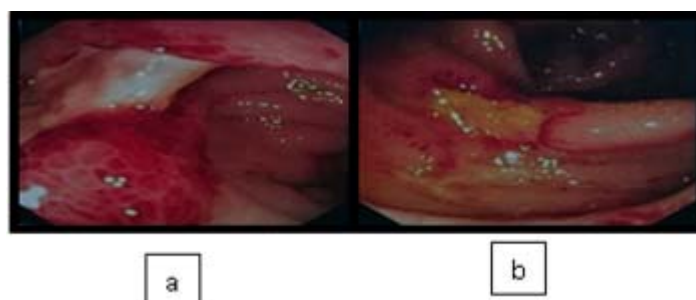
Physical examination was remarkable for ill-appearance and a temperature of 38°C. Minimal oral hairy leukoplakia was also found. Laboratory values included normocytic anemia (hemoglobin concentration of 7.3 g/dl), and white blood cell count of 4,230 /mm<sup>3</sup> with neutrophil predominated of 78%. Stool studies (including *C.difficile* toxin) were negative. Colonoscopy showed a large ulcer at the ileocecal valve and cecum, with multiple clean based ulcers and mucosal erythema throughout the colon (Rt. side >Lt. side) (Figure 1). The biopsy showed intranuclear inclusion-like materials. Blood for CMV viral load was positive (CMV viral load 10,800 copies/mL, log 4.03).

All the antibiotics were stopped, and the patient was given intravenous ganciclovir for 2 weeks. Within 1 week, the patient became afebrile and no diarrhea was further reported. After completion of 2-week course of ganciclovir, highly active antiretroviral therapy (HAART) was initiated using a standard regimen of TDF, FTC, and EFV.

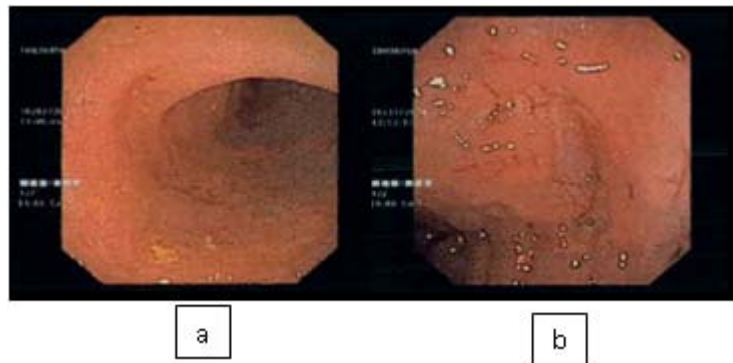**Case 3.** A 31-year-old female with no known underlying disease presented with persistent mucous diarrhea for 2 months. Stool frequency was more than 10 episodes per day, small in volume, and accompanied by tenesmus. Afterwards, she also developed fever, weight loss and progressive odynophagia and dysphagia. She had a history of unprotected sex with multiple partners.

Her examination was remarkable for multiple cervical lymphadenopathies, oral thrush, hepatomegaly, and pruritic papular eruption at both legs. Laboratory values included normocytic anemia (hemoglobin concentration of 10.2 g/dl), white blood cell count of 9,180 /mm<sup>3</sup> with no shift to the left, and normal liver function test. Stool studies were positive for WBC 5-10 cells/hpf. Her HIV serology turned out to be positive, with CD4 cell counts and HIV RNA levels of 163 (9%) cells/ $\mu$ L and 3 $\times$ 10<sup>6</sup> copies/mL, respectively. EGD concluded a diagnosis of esophageal candidiasis. Colonoscopy revealed inflamed colonic mucosa (Lt.side>Rt.side) with multiple scattered shallow clean ulcers from rectum to transverse colon and in terminal ileum (Figure 2). Biopsy tissues from both colon and terminal ileum showed atypical cells, suggesting CMV infection. Immunohistochemical (IHC) staining for CMV were positive from both specimens. Blood for CMV viral load was 16,389 copies/mL, log 4.21.

Intravenous ganciclovir 5mg/kg/12hr was administered for 3 weeks and later decreased to 5mg/kg/day until completion of 6 - week course due to suspicion of ganciclovir-induced transaminitis during admission. Hence, HAART was not initiated until the 5<sup>th</sup> week of admission after transaminitis subsided.



**Figure 1.** Colonoscopy showed a large ulcer at ileocecal valve and cecum, with multiple clean based ulcers and mucosal erythema throughout the colon (a) ileocecal valve (b) ascending colon.



**Figure 2.** Colonoscopy showed inflamed colonic mucosa with multiple scattered shallow clean ulcers from rectum to transverse colon and in terminal ileum (a) terminal ileum (b) descending colon.

### Discussion

Cytomegalovirus (CMV) is a double-stranded DNA virus in the herpesviridae family, usually acquired during childhood. Once infected, the virus usually remains dormant. CMV can infect both immunocompetent and immunocompromised individuals. Because CMV reactivation only develops when T-lymphocyte-mediated immunity is compromised, most immunocompetent individuals have mild to no symptoms at all. In contrast, CMV reactivation can develop in immunocompromised individuals and can cause multiple localized end-organ disease such as retinitis, gastrointestinal diseases, pneumonitis, and neurological diseases. Risk factors for end-organ disease in HIV-infected patients include those with low CD4 T-lymphocyte cell counts (<50 cells/ $\mu$ L), previous opportunistic infections (OIs), a high level of CMV viremia, and high plasma HIV RNA levels (>100,000 copies/mL).<sup>(7)</sup>

Gastrointestinal tract is the second most common clinical CMV end-organ disease in HIV-infected patients (5 - 10%), behind only retinitis.<sup>(6)</sup> The most common region of gastrointestinal tract involvement is colon.<sup>(8)</sup> The reason for such finding is still unclear. In our series, colonic involvement

occurred in 2 cases. CMV infection is a serious complication in HIV-infected patients, especially in the era before the advent of highly active antiretroviral therapy (HAART). A study in the pre-HAART era reported median survival of CMV colitis in HIV-infected patients were 4 months.<sup>(9)</sup> Since the advent of HAART, the incidence of CMV end-organ disease including CMV colitis has declined rapidly.<sup>(10, 11)</sup>

Patients with CMV-GID can present with various clinical manifestations depending on the region of gastrointestinal tract involved. Multiple clinical spectrums of CMV-GID in patients with AIDS have been reported (Table 1). Clinical features are usually difficult to be distinguished from other diseases; thus, further investigations are necessary to conclude the diagnosis. Esophagitis in patients with AIDS is most commonly due to either *Candida albicans* or herpes simplex virus, but in some cases for instance, CMV may also be the cause.<sup>(12)</sup> Coinfection of both CMV and candida esophagitis has also been reported, most of which had no gross CMV esophagitis. Laine *et al.* reported that less than a quarter of patients with candida esophagitis had concomitant CMV esophagitis and only 5% that

**Table 1.** Clinical spectrum of cytomegalovirus gastrointestinal disease (CMV-GID) in patients with acquired immunodeficiency syndrome (AIDS).

---

**Luminal tract disease**

Esophagitis

Gastritis<sup>(31)</sup>, Gastric perforation<sup>(31)</sup>

Enteritis, Pseudo tumor<sup>(32)</sup>

Colitis, Colonic perforation<sup>(33)</sup>

Enteric fistula

Enterocolic<sup>(17)</sup>

Enterocutaneous<sup>(18)</sup>

**Solid organ disease**

Hepatitis<sup>(34)</sup>

Cholangitis<sup>(35, 36)</sup>

Cholecystitis<sup>(37)</sup>

Pancreatitis<sup>(19)</sup>

Appendicitis<sup>(6, 20)</sup>

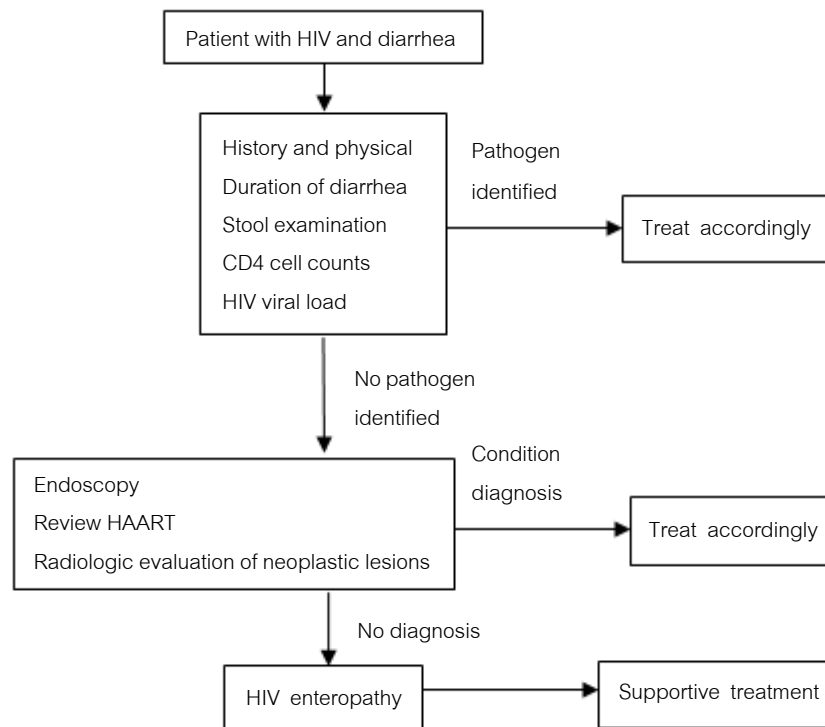
---

CMV was of clinical importance.<sup>(13)</sup> Even though in Case 3, the patient did not have histopathological test to rule out CMV esophagitis, the treatment for CMV esophagitis would have already be given because of concomitant CMV enteritis and colitis. Case 2 represented a great example of difficulties in distinguishing CMV colitis from other causes; in this case, antibiotic-associated diarrhea (AAD). Diarrhea occurred after taking antibiotic, especially clindamycin, might raise concerns for AAD; clindamycin is one of the most common cause for AAD. Cytotoxin assay, though it is considered the “gold standard” for AAD diagnosis, it is not commonly used because it requires tissue-cultured cells and 24 - 72 hours to incubate. The appropriate next step for the patient with suspected of AAD is to use enzyme-linked immunosorbent assay (ELISA) for *C.difficile*

toxin A and B, which is easier to do and provide prompt result. Due to lower sensitivity and specificity, 3 stool samples should be used. If the test is positive, no further investigation is need and the treatment can be started by discontinue antibiotics given for other purposes and initiate metronidazole and/or vancomycin. It is noted that in moderate to severe cases, the treatment can be started prior to the test results. If the result is negative, endoscopy should be performed as the next step.<sup>(14, 15)</sup> For HIV-infected patients with diarrhea, as seen in Case 2 and 3, stools examination and, occasionally, endoscopy are needed to aid the diagnosis (Figure 3).

Enteric fistula has been documented as a rare presentation of CMV-GID.<sup>(17, 18)</sup> Extraluminal diseases have also been reported-hepatitis, cholangitis, cholecystitis, pancreatitis, and appendicitis – on rare occasions. Pancreatitis has also been reported especially in the pre-HAART era; the incidence had declined since then. Osiro *et al.* reported approximately 30 cases of CMV pancreatitis in AIDS patients from 1980 to 2012.<sup>(19)</sup> Both cases of CMV appendicitis were also reported in the pre-HAART era.<sup>(20, 21)</sup>

The usual endoscopic finding is mucosal ulceration; however, several findings ranging from microerosion to pseudotumor have been reported.<sup>(7, 22)</sup> For CMV colitis, the findings are often undistinguished to ulcerative colitis and Crohn's disease.<sup>(5)</sup> Nonetheless, the absence of colonic ulceration on endoscopy should raise concern that other causes other than CMV may underlie the colonic disease.<sup>(9)</sup> Because clinical features and endoscopic findings typically lack specificity, histologic of biopsy tissue is ultimately necessary for diagnosis of CMV-



**Figure 3.** Basic approach to diarrhea in human immunodeficiency virus-infected patients. Specific examples of stool assay may be performed in addition to microscopic examination. Upper endoscopy and colonoscopy should be strongly considered for patients with CD4 cell counts <100 cells/ $\mu$ L. Abbreviations: HAART, highly active antiretroviral therapy; HIV, human immunodeficiency virus. Modified from MacArthur RD, et al. Clin Infect Dis 2012;55(6):860 - 7<sup>(16)</sup>

GID. Histologically, CMV infection can be identified by the infected cells consisting of characteristic intranuclear and intracytoplasmic 'owl's eye' inclusions using hematoxylin and eosin (H&E) staining; however, the current "gold standard" for CMV detection in tissue section is by using CMV-specific immunohistochemical (IHC) staining.<sup>(23, 24)</sup> The interpretation of polymerase chain reaction (PCR) from biopsy tissues for CMV detection is still inconclusive. In studies by Ljungman *et al*, CMV PCR of the tissue specimens alone is not recommended because of its low positive predictive value due to the high sensitivity of PCR, which can detect latent CMV infection.<sup>(22, 25)</sup> However, a study by Mills *et al*, suggested that CMV PCR on biopsy tissues complements with IHC has

the potentiality to identify additional patients who may benefit from anti-CMV therapy.<sup>(24)</sup>

CMV viremia detection has been proposed as another method to aid the diagnosis of CMV-GID. CMV viremia usually presents in individuals with CMV end-organ disease, and can be detected by PCR, antigen assays, or culture. However, false positive may occur in HIV-infected patients with low CD4 cell counts.<sup>(26, 27)</sup> Furthermore, negative results cannot be used to rule out CMV end-organ disease.<sup>(28)</sup> Thus, because of their poor predictive value, blood tests to detect CMV viremia are not recommended for diagnosis of CMV end-organ disease in HIV-infected patients.<sup>(7)</sup>

In HIV-infected patients, the best measure in preventing CMV infection is by using HAART to maintain the CD4 count > 100 cells/ $\mu$ L. Some studies have focused on using oral ganciclovir or oral valganciclovir for primary prophylaxis, the results proved little success.<sup>(29,30)</sup> Other preventive measures are to provide patient's education that CMV is shed in semen, cervical secretions, and saliva and to also emphasize that latex condoms must always be used during sexual intercourse.<sup>(7)</sup>

Ganciclovir, valganciclovir, and foscarnet are the medication currently used for treatment, though some variations are presented from different guidelines (Table 2). Ganciclovir and valganciclovir

are guanosine derivatives. Both have comparable effectiveness and side effects. More importantly, both require intracellular conversion using the viral phosphotransferase encoded by CMV UL97 gene, the gene contributes to drug resistance; thus, both drugs have similar genetic barrier for developing drug resistance. In contrast to ganciclovir and valganciclovir, foscarnet does not require phosphorylation to be active. Thus, foscarnet can be used effectively in patients who develop resistance to ganciclovir or valganciclovir. However, because of its considerable amount of toxicities and complicated drug administration, it is not commonly used. Treatment for CMV-GID in patients with AIDS is

**Table 2.** Treatment of CMV esophagitis/colitis from selected guidelines.

Year	CDC/NIH/HIVMA/IDSA <sup>(7)</sup>	EACS <sup>(38)</sup>	TAS <sup>(39)</sup>
	2015	2015	2014
Primary treatment	Ganciclovir 5 mg/kg IV q12h; may switch to valganciclovir 900 mg PO q12h once the patient can tolerate oral therapy	Ganciclovir 5 mg/kg IV q12h or Foscarnet 90 mg/kg IV q12h	Ganciclovir 5 mg/kg IV q12h or Valganciclovir 900 mg PO q12h
Alternative treatment	Foscarnet 90 mg/kg IV q12h or Foscarnet 60 mg/kg IV q8h or Valganciclovir 900 mg PO q12h	or Valganciclovir 900 mg PO q12h	Not available
Duration	21-42 days or until symptoms resolved	3-6 weeks, respectively until symptoms resolved	3-6 weeks or until symptoms resolved
Timing for ART initiation	Within 2 weeks	Not available	As soon as possible

Abbreviations: ART, antiretroviral therapy; CDC, Centers for Disease Control and Prevention; EACS, European AIDS Clinical Society; HIVMA/IDSA, HIV Medicine Association of the Infectious Disease Society of America; NIH, National Institutes of Health; TAS: Thai AIDS Society.



recommended for 3 - 6 weeks or until symptoms have resolved. For treatment-naïve patients, ART should be initiated as soon as possible or within 2 weeks provided that the patients have no CMV retinitis or CMV-related neurological disorder; otherwise ART initiation should be delayed for at least 2 weeks to prevent immune reconstitution inflammatory syndrome (IRIS). Secondary prophylaxis is not recommended unless there is concurrent CMV retinitis.

### Conclusion

Cytomegalovirus gastrointestinal disease in patients with AIDS can occur at any site of the gastrointestinal tract. Because of its indistinguishable clinical manifestations, high suspicion from health care provider is required for further investigation to conclude the diagnosis. In preventing CMV infection, emphasis to the patients should always be made on keeping CD4 level of more than 100 cells/ $\mu$ L by having good adherence to ARV. Prompt diagnosis and treatment can decrease mortality and reduce morbidity in an otherwise, a fatal disease.

### References

1. de la Hoz RE, Stephens G, Sherlock C. Diagnosis and treatment approaches of CMV infections in adult patients. *J Clin Virol* 2002 Aug;25 Suppl 2:S1-12
2. Feasey NA, Healey P, Gordon MA. Review article: the aetiology, investigation and management of diarrhoea in the HIV-positive patient. *Aliment Pharmacol Ther* 2011 Sep;34(6): 587-603
3. Monkemuller KE, Wilcox CM. Diagnosis and treatment of colonic disease in AIDS. *Gastrointest Endosc Clin N Am* 1998 Oct; 8(4):889-911
4. DeRodriguez CV, Fuhrer J, Lake-Bakaar G. Cytomegalovirus colitis in patients with acquired immunodeficiency syndrome. *J R Soc Med* 1994 Apr;87(4):203-5
5. Paparone PP, Paparone PA. Cytomegalovirus colitis in a human immunodeficiency virus-positive patient with a normal CD4 count. *Am J Med Sci* 2012 Dec;344(6):508-10
6. Dieterich DT, Rahmin M. Cytomegalovirus colitis in AIDS: presentation in 44 patients and a review of the literature. *J Acquir Immune Defic Syndr* 1991;4 Suppl 1:S29-35
7. Panel on Opportunistic Infections in HIV-Infected Adults and Adolescents. Guidelines for the prevention and treatment of opportunistic infections in HIV-infected adults and adolescents: recommendations from the Centers for Disease Control and Prevention, the National Institutes of Health, and the HIV Medicine Association of the Infectious Diseases Society of America. 2016 [cited 2016 Feb 19] Available from: [http://aidsinfo.nih.gov/contentfiles/lvguidelines/adult\\_oi.pdf](http://aidsinfo.nih.gov/contentfiles/lvguidelines/adult_oi.pdf).
8. Shepp DH, Moses JE, Kaplan MH. Seroepidemiology of cytomegalovirus in patients with advanced HIV disease: influence on disease expression and survival. *J Acquir Immune Defic Syndr Hum Retrovirol* 1996 Apr 15;11(5):460-8
9. Mentec H, Leport C, Leport J, Marche C, Harzic M, Vilde JL. Cytomegalovirus colitis in HIV-1-infected patients: a prospective research in

- 55 patients. *AIDS* 1994 Apr;8(4):461-7
10. Salzberger B, Hartmann P, Hanses F, Uyanik B, Cornely OA, Wohrmann A, Fatkenheuer G. Incidence and prognosis of CMV disease in HIV-infected patients before and after introduction of combination antiretroviral therapy. *Infection* 2005 Oct;33(5-6):345-9
  11. Bini EJ, Gorelick SM, Weinshel EH. Outcome of AIDS-associated cytomegalovirus colitis in the era of potent antiretroviral therapy. *J Clin Gastroenterol* 2000 Jun;30(4):414-9
  12. Wilcox CM, Straub RF, Schwartz DA. Cytomegalovirus esophagitis in AIDS: a prospective evaluation of clinical response to ganciclovir therapy, relapse rate, and long-term outcome. *Am J Med* 1995 Feb; 98(2):169-76
  13. Laine L, Bonacini M, Sattler F, Young T, Sherrod A. Cytomegalovirus and *Candida* esophagitis in patients with AIDS. *J Acquir Immune Defic Syndr* 1992;5(6):605-9
  14. Hookman P, Barkin JS. *Clostridium difficile* associated infection, diarrhea and colitis. *World J Gastroenterol* 2009 Apr 7;15(13): 1554-80
  19. Osiro S, Muhammad R, Ruiz J, Sladen A, Mathenge N, Tiwari KJ. Acute necrotizing pancreatitis in the setting of CMV viremia and AIDS: a case report and review of literature from 1980 to 2012. *JOP* 2012 Nov;13(6): 705-11
  20. Tarng YW, Shih DF, Liu SI, Wang BW, Mok KT. Cytomegalovirus appendicitis in a patient with acquired immunodeficiency syndrome: a case report. *Zhonghua Yi Xue Za Zhi* (Taipei) 1997 Jul;60(1):48-51
  21. Dieterich DT, Kim MH, McMeeding A, Rotterdam H. Cytomegalovirus appendicitis in a patient with acquired immune deficiency syndrome. *Am J Gastroenterol* 1991 Jul;86(7):904-6
  22. Ljungman P, Griffiths P, Paya C. Definitions of cytomegalovirus infection and disease in transplant recipients. *Clin Infect Dis* 2002 Apr 15;34(8):1094-7
  23. Hirsch MS. Cytomegalovirus and Human Herpesvirus Types 6, 7, and 8. In: Longo DL, FA, Kasper DL, Hauser SL, Jameson JL, Loscalzo J, editor. *Harrison's Principles of Internal Medicine*. 18 ed. New York, NY: McGraw-Hill; 2012. p. 1471-5
  24. Mills AM, Guo FP, Copland AP, Pai RK, Pinsky BA. A comparison of CMV detection in gastrointestinal mucosal biopsies using immunohistochemistry and PCR performed on formalin-fixed, paraffin-embedded tissue. *Am J Surg Pathol* 2013 Jul;37(7):995-1000
  25. Ljungman P, de la Camara R, Cordonnier C, Einsele H, Engelhard D, Reusser P, Styczynski J, Ward K. Management of CMV, HHV-6, HHV-7 and Kaposi-sarcoma herpesvirus (HHV-8) infections in patients with hematological malignancies and after SCT. *Bone Marrow Transplant* 2008 Aug; 42(4):227-40
  26. Zurlo JJ, O'Neill D, Polis MA, Manischewitz J, Yarchoan R, Baseler M, Lane HC, Masur H. Lack of clinical utility of cytomegalovirus blood and urine cultures in patients with HIV infection. *Ann Intern Med* 1993 Jan;118(1): 12-7

27. Deayton JR, Prof Sabin CA, Johnson MA, Emery VC, Wilson P, Griffiths PD. Importance of cytomegalovirus viraemia in risk of disease progression and death in HIV-infected patients receiving highly active antiretroviral therapy. *Lancet* 2004 Jun 26;363(9427): 2116-21
28. Ganzenmueller T, Henke-Gendo C, Schlue J, Wedemeyer J, Huebner S, Heim A. Quantification of cytomegalovirus DNA levels in intestinal biopsies as a diagnostic tool for CMV intestinal disease. *J Clin Virol* 2009 Nov; 46(3):254-8
29. Spector SA, McKinley GF, Lalezari JP, Samo T, Andruczk R, Follansbee S, Sparti PD, Havlir DV, Simpson G, Buhles W, et al. Oral ganciclovir for the prevention of cytomegalovirus disease in persons with AIDS. Roche Cooperative Oral Ganciclovir Study Group. *N Engl J Med* 1996 Jun;334(23):1491-7
30. Wohl DA, Kendall MA, Andersen J, Crumpacker C, Spector SA, Feinberg J, Alston-Smith B, Owens S, Chafey S, Marco M, et al. Low rate of CMV end-organ disease in HIV-infected patients despite low CD4+ cell counts and CMV viremia: results of ACTG protocol A5030. *HIV Clin Trials* 2009 May-Jun;10(3):143-52
31. Megarbane B, Resiere D, Ferrand J, Raskine L, Vahedi K, Baud FJ. Difficulties in assessing cytomegalovirus-associated gastric perforation in an HIV-infected patient. *BMC Infect Dis* 2005 Apr 13;5:28
34. Astagneau P, Michon C, Marche C, Simonpoli AM, Girard PM, Kernbaum S, Coulaud JP, Saimot AG. Hepatic involvement in AIDS. A retrospective clinical study in 71 patients. *Ann Med Interne (Paris)* 1990;141(5):459-63
35. Hidalgo-Tenorio C, Blasco-Morente G. Sclerosing cholangitis by cytomegalovirus in highly active antiretroviral therapy era. *Rev Esp Enferm Dig* 2013 Oct;105(9):557-60
36. Bouche H, Housset C, Dumont JL, Carnot F, Menu Y, Aveline B, Belghiti J, Boboc B, Erlinger S, Berthelot P, et al. AIDS-related cholangitis: diagnostic features and course in 15 patients. *J Hepatol* 1993 Jan;17(1):34-9
37. Schneiderman DJ. Hepatobiliary abnormalities of AIDS. *Gastroenterol Clin North Am* 1988 Sep;17(3):615-30
38. Ryom L, Boesecke C, Gisler V, Manzardo C, Rockstroh JK, Puoti M, Furrer H, Miro JM, Gatell JM, Pozniak A, et al. Essentials from the 2015 European AIDS Clinical Society (EACS) guidelines for the treatment of adult HIV-positive persons. *HIV Med* 2016 Feb; 17(2):83-8
39. Manosuthi W, Ongwandee S, Bhakeecheep S, Leechawengwongs M, Ruxrungtham K, Phanuphak P, Hiransuthikul N, Ratanasuwan W, Chetchotisakd P, Tantisiriwat W, et al. Guidelines for antiretroviral therapy in HIV-1 infected adults and adolescents 2014, Thailand. *AIDS Res Ther* 2015 Apr 24;12:12